



# Protocol for the Examination of Biopsy Specimens From Patients With Invasive Carcinoma of the Breast

Version: BreastInvasiveBiopsy 1.0.0.0

Protocol Posting Date: February 2019

## Accreditation Requirements

The use of this protocol is recommended for clinical care purposes but is not required for accreditation purposes.

## This protocol may be used for the following procedures AND tumor types:

Procedure	Description
Biopsy	Includes specimens designated needle biopsy, fine needle aspiration and others (for excisional biopsy, see below)
Tumor Type	Description
Invasive breast carcinoma of any type, with or without ductal carcinoma in situ (DCIS)	Includes microinvasive carcinoma and carcinoma with neuroendocrine features

## The following should NOT be reported using this protocol:

Procedure
Resection (consider Breast Invasive Carcinoma Resection protocol)
Excisional biopsy (consider Breast Invasive Carcinoma Resection protocol)
Tumor Type
Ductal carcinoma in situ (DCIS) without invasive carcinoma (consider the DCIS Biopsy protocol)
Phyllodes tumor
Lymphoma (consider the Hodgkin or non-Hodgkin Lymphoma protocols)
Sarcoma (consider the Soft Tissue protocol)

## Authors

Patrick L. Fitzgibbons, MD\*; James L. Connolly\*, MD

With guidance from the CAP Cancer and CAP Pathology Electronic Reporting Committees.

\* Denotes primary author. All other contributing authors are listed alphabetically.

## Accreditation Requirements

The use of this biopsy case summary is recommended for clinical care purposes, but is not required for accreditation purposes. The core and conditional data elements are routinely reported for biopsy specimens. Non-core data elements are included to allow for reporting information that may be of clinical value.

## Summary of Changes

1.0.0.0 – New Breast Invasive Carcinoma Biopsy protocol

**Surgical Pathology Cancer Case Summary**

---

Protocol posting date: February 2019

**INVASIVE CARCINOMA OF THE BREAST: Biopsy****Notes:****This case summary is recommended for reporting biopsy specimens but is NOT REQUIRED for accreditation purposes. Core data elements are bolded to help identify routinely reported elements.****Select a single response unless otherwise indicated.****Procedure**

- Needle biopsy  
 Fine needle aspiration  
 Other (specify): \_\_\_\_\_  
 Not specified

**Specimen Laterality**

- Right  
 Left  
 Not specified

Tumor Site (select all that apply)

- Upper outer quadrant  
 Lower outer quadrant  
 Upper inner quadrant  
 Lower inner quadrant  
 Central  
 Nipple  
 Clock position (specify): \_\_\_\_\_ o'clock  
 Distance from nipple (centimeters): \_\_\_\_\_ cm  
 Other (specify): \_\_\_\_\_  
 Not specified

**Histologic Type (Note A)**

- Invasive carcinoma of no special type (ductal, not otherwise specified)  
 Micro-invasive carcinoma  
 Invasive lobular carcinoma  
 Invasive carcinoma with lobular features  
 Invasive carcinoma with ductal and lobular features (“mixed type carcinoma”)  
 Mucinous carcinoma  
 Tubular carcinoma  
 Invasive carcinoma, tubulo-lobular variant  
 Invasive cribriform carcinoma  
 Invasive micropapillary carcinoma  
 Invasive papillary carcinoma  
 Medullary carcinoma  
 Invasive carcinoma with medullary features  
 Metaplastic carcinoma  
 Low-grade adenosquamous carcinoma  
 Fibromatosis-like metaplastic carcinoma  
 Metaplastic carcinoma, spindle cell type  
 Metaplastic carcinoma, mixed epithelial and mesenchymal type

- Invasive carcinoma with metaplastic features
- Squamous cell carcinoma
- Adenoid cystic carcinoma
- Invasive carcinoma with apocrine features
- Invasive carcinoma with clear cell (glycogen rich) features
- Invasive carcinoma with neuroendocrine features
- Invasive carcinoma, with signet-ring cell features
- Secretory carcinoma
- Invasive carcinoma, type cannot be determined
- Other histologic type not listed (specify): \_\_\_\_\_

**Histologic Grade (Nottingham Histologic Score) (Note B)**

- Not applicable (microinvasion only)

**Glandular (Acinar)/Tubular Differentiation**

- Score 1 (>75% of tumor area forming glandular/tubular structures)
- Score 2 (10% to 75% of tumor area forming glandular/tubular structures)
- Score 3 (<10% of tumor area forming glandular/tubular structures)
- Score cannot be determined

**Nuclear Pleomorphism**

- Score 1 (nuclei small with little increase in size in comparison with normal breast epithelial cells, regular outlines, uniform nuclear chromatin, little variation in size)
- Score 2 (cells larger than normal with open vesicular nuclei, visible nucleoli, and moderate variability in both size and shape)
- Score 3 (vesicular nuclei, often with prominent nucleoli, exhibiting marked variation in size and shape, occasionally with very large and bizarre forms)
- Score cannot be determined

**Mitotic Rate**

- Score 1 ( $\leq 3$  mitoses per  $\text{mm}^2$ ) (see Table 1)
  - Score 2 (4-7 mitoses per  $\text{mm}^2$ ) (see Table 1)
  - Score 3 ( $\geq 8$  mitoses per  $\text{mm}^2$ ) (see Table 1)
  - Score cannot be determined
- Number of mitoses per 10 high-power fields: \_\_\_\_

**Overall Grade**

- Grade 1 (scores of 3, 4, or 5)
- Grade 2 (scores of 6 or 7)
- Grade 3 (scores of 8 or 9)
- Score cannot be determined (explain: \_\_\_\_\_)

**Ductal Carcinoma In Situ (DCIS) (Note C)**

- Not identified
- Present

**Architectural Patterns (if DCIS is present select all that apply)**

- Comedo
- Paget disease (DCIS involving nipple skin)
- Cribriform
- Micropapillary
- Papillary
- Solid
- Other (specify): \_\_\_\_\_

**Nuclear Grade (if DCIS is present)**

- Grade I (low)
- Grade II (intermediate)
- Grade III (high)

**Necrosis (if DCIS is present)**

- Not identified
- Present, focal (small foci or single cell necrosis)
- Present, central (expansive “comedo” necrosis)

**Lymphovascular Invasion**

- Not identified
- Present
- Cannot be determined

**Additional Pathologic Findings (Note D)**

Specify: \_\_\_\_\_

**Microcalcifications (select all that apply) (Note E)**

- Not identified
- Present in DCIS
- Present in invasive carcinoma
- Present in non-neoplastic tissue
- Other (specify): \_\_\_\_\_

**Ancillary Studies**

*Note: For hormone receptor and HER2 reporting, the CAP Breast Biomarker Template should be used.*  
[www.cap.org/cancerprotocols](http://www.cap.org/cancerprotocols). Pending biomarker studies should be listed in the Comments section of this report.

Comment(s)

**A. Histologic Type**

This protocol applies to all invasive carcinomas of the breast. The World Health Organization (WHO) classification of breast carcinoma is presented below, although the protocol does not preclude the use of other classifications or histologic types. Carcinomas may be classified based on the H&E appearance without the use of immunohistochemical studies.

A modified list is presented in the protocol, based on the most frequent types of invasive carcinomas and terminology that is in widespread usage. The modified list is intended to capture the majority of tumors and reduce the classification of tumors being reported as “other.” The WHO classification is presented for completeness.

**WHO Classification of Invasive Carcinoma of the Breast<sup>1</sup>**

Microinvasive carcinoma

Invasive carcinoma of no special type (NST)

Pleomorphic carcinoma

Carcinoma with osteoclast-like stromal giant cells

Carcinoma with choriocarcinomatous features

Carcinoma with melanotic features

Invasive lobular carcinoma

Classic lobular carcinoma

Solid lobular carcinoma

Alveolar lobular carcinoma

Pleomorphic lobular carcinoma

Tubulolobular carcinoma

Mixed lobular carcinoma

Tubular carcinoma

Cribriform carcinoma

Mucinous carcinoma

Carcinoma with medullary features

Medullary carcinoma

Atypical medullary carcinoma

Invasive carcinoma NST with medullary features

Carcinoma with apocrine differentiation

Carcinoma with signet-ring-cell differentiation

Invasive micropapillary carcinoma

Metaplastic carcinoma of no special type

Low-grade adenosquamous carcinoma

Fibromatosis-like metaplastic carcinoma

Squamous cell carcinoma

Spindle cell carcinoma

Metaplastic carcinoma with mesenchymal differentiation

Chondroid differentiation

Osseous differentiation

Other types of mesenchymal differentiation

Mixed metaplastic carcinoma

Myoepithelial carcinoma

Papillary carcinoma

Encapsulated papillary carcinoma with invasion

Solid papillary carcinoma, invasive

Epithelial-myoepithelial tumors

Adenomyoepithelioma with carcinoma

Adenoid cystic carcinoma

Rare types

Carcinoma with neuroendocrine features

Neuroendocrine tumor, well-differentiated  
 Neuroendocrine carcinoma poorly differentiated (small cell carcinoma)  
 Carcinoma with neuroendocrine differentiation

Secretory carcinoma  
 Invasive papillary carcinoma  
 Acinic cell carcinoma  
 Mucoepidermoid carcinoma  
 Polymorphous carcinoma  
 Oncocytic carcinoma  
 Lipid-rich carcinoma  
 Glycogen-rich clear cell carcinoma  
 Sebaceous carcinoma

#### References

1. Lakhani SR, Ellis IO, Schnitt SJ, Tan PH, van de Vijver MJ. *WHO Classification of Tumours of the Breast, fourth ed.* Geneva, Switzerland: WHO Press; 2012.

#### B. Histologic Grade

All invasive breast carcinomas should be graded.<sup>1</sup> The Nottingham combined histologic grade (Elston-Ellis modification of Scarff-Bloom-Richardson grading system) should be used for reporting. Within each stage grouping there is a relation between histologic grade and outcome.

The Nottingham combined histologic grade evaluates the amount of tubule formation, the extent of nuclear pleomorphism, and the mitotic count (or mitotic rate). Each variable is given a score of 1, 2, or 3, and the scores are added to produce a grade. The mitotic score is determined by the number of mitotic figures found in 10 consecutive high-power fields (HPF) in the most mitotically active part of the tumor. Only clearly identifiable mitotic figures should be counted; hyperchromatic, karyorrhectic, or apoptotic nuclei are excluded. Because of variations in field size, the HPF size must be determined for each microscope and the appropriate point score determined accordingly. It is recommended that the size be measured by using a micrometer. However, the diameter of an HPF can also be calculated by using the method below.

#### Measuring the Size of a High-Power Field (HPF) With a Ruler

Use a clear ruler to measure the diameter of a low-power field. This number can be used to calculate a constant based on the following formula:

Eyepiece Magnification x Objective Magnification x Microscopic Field Diameter = A Constant

When the value of the constant is known, the diameter of an HPF can be calculated for other objectives by using the following formula:

Unknown Field Diameter = Constant/(Eyepiece Magnification x Objective Magnification)

Half of the field diameter is the radius of the field ( $r$ ), which can then be used to calculate the area of the HPF:  
 $3.1415 \times r^2 = \text{Area of Microscopic Field}$

If the microscopic field diameter or the area of the field is known, Table 1 can be used to determine the number of mitoses corresponding to different scores.

Table 1. Score Categories According to Field Diameter and Mitotic Count

Scoring Categories of Mitotic Counts				
Field diameter (mm)	Area (mm <sup>2</sup> )	Number of mitoses per 10 fields corresponding to:		
		Score 1	Score 2	Score 3
0.40	0.125	≤4	5 to 9	≥10
0.41	0.132	≤4	5 to 9	≥10
0.42	0.139	≤5	6 to 10	≥11
0.43	0.145	≤5	6 to 10	≥11
0.44	0.152	≤5	6 to 11	≥12
0.45	0.159	≤5	6 to 11	≥12
0.46	0.166	≤6	7 to 12	≥13
0.47	0.173	≤6	7 to 12	≥13
0.48	0.181	≤6	7 to 13	≥14
0.49	0.189	≤6	7 to 13	≥14
0.50	0.196	≤7	8 to 14	≥15
0.51	0.204	≤7	8 to 14	≥15
0.52	0.212	≤7	8 to 15	≥16
0.53	0.221	≤8	9 to 16	≥17
0.54	0.229	≤8	9 to 16	≥17
0.55	0.238	≤8	9 to 17	≥18
0.56	0.246	≤8	9 to 17	≥18
0.57	0.255	≤9	10 to 18	≥19
0.58	0.264	≤9	10 to 19	≥20
0.59	0.273	≤9	10 to 19	≥20
0.60	0.283	≤10	11 to 20	≥21
0.61	0.292	≤10	11 to 21	≥22
0.62	0.302	≤11	12 to 22	≥23
0.63	0.312	≤11	12 to 22	≥23
0.64	0.322	≤11	12 to 23	≥24
0.65	0.332	≤12	13 to 24	≥25
0.66	0.342	≤12	13 to 24	≥25
0.67	0.353	≤12	13 to 25	≥26
0.68	0.363	≤13	14 to 26	≥27
0.69	0.374	≤13	14 to 27	≥28

From Pathology Reporting of Breast Disease.<sup>2</sup> Copyright 2005 National Health Service Cancer Screening Programme and The Royal College of Pathologists. Adapted with permission.

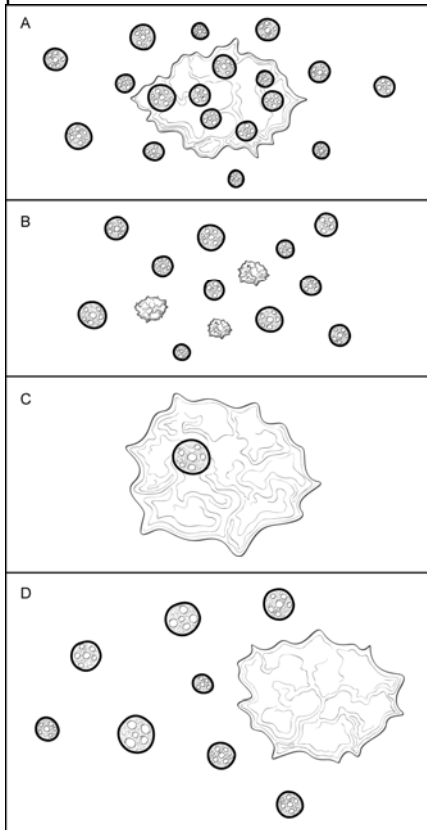
## References

1. Ellis IO, Elston CW. Histologic grade. In: O'Malley FP, Pinder SE, eds. *Breast Pathology*. Philadelphia, PA: Elsevier; 2006:225-233.
2. *Pathology Reporting of Breast Disease*. A Joint Document Incorporating the Third Edition of the NHS Breast Screening Programme's *Guidelines for Pathology Reporting in Breast Cancer Screening* and the Second Edition of The Royal College of Pathologists' *Minimum Dataset for Breast Cancer Histopathology* Published by the NHS Cancer Screening Programmes jointly with The Royal College of Pathologists. NHSBSP Publication No 58. January 2005. <http://www.cancerscreening.nhs.uk/breastscreen/publications/nhsbsp58.html>. Accessed April 8, 2009.

**C. Ductal Carcinoma In Situ**

Ductal carcinoma in situ associated with invasive carcinoma increases the risk of local recurrence for women undergoing breast-conserving surgery. It is more important to report the features of DCIS when in situ disease is predominant (eg, cases of DCIS with microinvasion or extensive DCIS associated with T1a carcinoma). If DCIS is a minimal component of the invasive carcinoma, the features of the DCIS have less clinical relevance. Therefore, most of the reporting elements for DCIS are optional and should be used at the discretion of the pathologist.

The pathology report should specify whether extensive DCIS is present. Extensive intraductal component (EIC)-positive carcinomas are defined in 2 ways (Figure 4, A through D)<sup>1</sup>:



**Figure 4. Extensive Intraductal Component (EIC).** A. Extensive intraductal component (EIC)-positive carcinomas are defined by the following criteria: (1)  $\geq 25\%$  of the area within the invasive carcinoma is ductal carcinoma in situ (DCIS) and (2) DCIS is also present outside the area of invasive carcinoma. B. EIC-positive carcinomas also include carcinomas in which DCIS is associated with a “small” (approximately 10 mm or less) invasive carcinoma or carcinomas. C. EIC-negative carcinomas do not fulfill the criteria for being positive for EIC. D. Some carcinomas do not strictly fulfill the criteria for EIC but are associated with extensive DCIS in the surrounding tissue. In such cases it is helpful to provide some measure of the extent of DCIS in the specimen.



1. Ductal carcinoma in situ is a major component within the area of invasive carcinoma (approximately 25%) and DCIS is also present in the surrounding breast parenchyma.
2. There is extensive DCIS associated with a small (~10 mm or less) invasive carcinoma (ie, the invasive carcinoma is too small for DCIS to comprise 25% of the area).

Extensive intraductal component-positive carcinomas are associated with an increased risk of local recurrence when the surgical margins are not evaluated or focally involved. The finding of EIC positivity has less significance when DCIS does not extend close to margins.

In some cases, extensive DCIS can be present outside the area of invasive carcinoma although the carcinoma does not technically fulfill the criteria for EIC positivity. In such cases, quantification of the amount of DCIS present is helpful for planning radiation therapy.

The extent of DCIS will be most relevant for cases of extensive DCIS with microinvasion and least relevant for large EIC-negative invasive carcinomas. Methods for estimating the extent of DCIS include directly measuring the lesion when confined to a single histologic slide, determining size by submitting the entire specimen in sequence and in sections of uniform thickness, or counting the number of blocks with DCIS. The College of American Pathologists (CAP) DCIS protocol<sup>2</sup> provides additional information on determining the extent of DCIS.

### Architectural Pattern of DCIS

The architectural pattern has traditionally been reported for DCIS. However, nuclear grade and the presence of necrosis are more predictive of clinical outcome.

### Nuclear Grade of DCIS

The nuclear grade of DCIS is determined using 6 morphologic features (Table 1).<sup>3</sup>

**Table 2. Nuclear Grade of Ductal Carcinoma in Situ**

Feature	Grade I (Low)	Grade II (Intermediate)	Grade III (High)
<b>Pleomorphism</b>	Monotonous (monomorphic)	Intermediate	Markedly pleomorphic
<b>Size</b>	1.5 to 2 x the size of a normal red blood cell or a normal duct epithelial cell nucleus	Intermediate	>2.5 x the size of a normal red blood cell or a normal duct epithelial cell nucleus
<b>Chromatin</b>	Usually diffuse, finely dispersed chromatin	Intermediate	Usually vesicular with irregular chromatin distribution
<b>Nucleoli</b>	Only occasional	Intermediate	Prominent, often multiple
<b>Mitoses</b>	Only occasional	Intermediate	May be frequent
<b>Orientation</b>	Polarized toward luminal spaces	Intermediate	Usually not polarized toward the luminal space

### Necrosis

The presence of necrosis is correlated with the finding of mammographic calcifications (ie, most areas of necrosis will calcify). Ductal carcinoma in situ that presents as mammographic calcifications often recurs as calcifications. Necrosis can be classified as follows:

- **Central (“comedo”)**: The central portion of an involved ductal space is replaced by an area of expansive necrosis that is easily detected at low magnification. Ghost cells and karyorrhectic debris are generally present. Although central necrosis is generally associated with high-grade nuclei (ie, comedo DCIS), it can also occur with DCIS of low or intermediate nuclear grade.
- **Focal**: Small foci, indistinct at low magnification, or single cell necrosis.

Necrosis should be distinguished from secretory material, which can also be associated with calcifications, but does not include nuclear debris.

#### References

1. Morrow M, Harris JR. Local management of invasive breast cancer (chapter 33). In: Harris JR, Lippman ME, Morrow M, Osborne KE, eds. *Diseases of the Breast*. 2<sup>nd</sup> ed. Philadelphia, PA: Lippincott Williams & Wilkins; 2000:522-523.
2. Fitzgibbons PL, Bose S, Chen Y, et al. Protocol for the Examination of Specimens From Patients with Ductal Carcinoma In Situ (DCIS) of the Breast. 2019; [www.cap.org/cancerprotocols](http://www.cap.org/cancerprotocols).
3. Schwartz GF, Lagios MD, Carter D, et al. Consensus conference on the classification of ductal carcinoma in situ. *Cancer*. 1997;80:1798-1802.

#### D. Additional Pathologic Findings

In some cases, additional pathologic findings are important for the clinical management of patients. If multiple invasive carcinomas are present and differ in histologic type, grade, or the expression of ER, PgR, or HER2, this information should be included as text in this section.

#### E. Microcalcifications

Cancer found in biopsies performed for microcalcifications will almost always be at the site of the calcifications or in close proximity. The presence of the targeted calcifications in the specimen should be confirmed by specimen radiography. The pathologist must be satisfied that the specimen has been sampled in such a way that the lesion responsible for the calcifications has been examined microscopically. The relationship of the radiologic calcifications to the invasive carcinoma and the DCIS should be indicated.

If calcifications can be seen in the specimen radiograph but not in the initial histologic sections, deeper levels should be examined. If needed, radiographs of the paraffin block(s) may be obtained to detect calcifications remaining in the block(s). If microcalcifications cannot be confirmed by routine microscopic evaluation, polarized light may be helpful, since calcium oxalate crystals are refractile and polarizable but usually clear or tinged yellow in H&E sections. On rare occasions, calcifications do not survive tissue processing or prolonged fixation in formalin. Foreign material can sometimes simulate calcifications (eg, metallic fragments after surgery or trauma).