

Protocol for the Examination of Specimens From Patients With Uveal Melanoma

Protocol applies to malignant melanoma of the uvea.

Based on AJCC/UICC TNM, 7th edition
Protocol web posting date: October 2013

Procedures

- Resection (Local Resection, Enucleation, Limited or Complete Exenteration)

Authors

Hans E. Grossniklaus MD, MBA, FCAP*

Departments of Ophthalmology and Pathology, Emory University School of Medicine, Atlanta, Georgia

Tero Kivëla MD

Departments of Ophthalmology and Pathology, University of Helsinki, Finland

J. William Harbour MD

Department of Ophthalmology, Washington University School of Medicine, St. Louis, Missouri

Paul Finger MD

Department of Ophthalmology, New York Eye and Ear Hospital, New York, New York

For the Members of the Cancer Committee, College of American Pathologists

* Denotes primary author. All other contributing authors are listed alphabetically.

Previous lead contributors: David L. Page, Harry H. Brown, MD

© 2013 College of American Pathologists (CAP). All rights reserved.

The College does not permit reproduction of any substantial portion of these protocols without its written authorization. The College hereby authorizes use of these protocols by physicians and other health care providers in reporting on surgical specimens, in teaching, and in carrying out medical research for nonprofit purposes. This authorization does not extend to reproduction or other use of any substantial portion of these protocols for commercial purposes without the written consent of the College.

The CAP also authorizes physicians and other health care practitioners to make modified versions of the Protocols solely for their individual use in reporting on surgical specimens for individual patients, teaching, and carrying out medical research for non-profit purposes.

The CAP further authorizes the following uses by physicians and other health care practitioners, in reporting on surgical specimens for individual patients, in teaching, and in carrying out medical research for non-profit purposes: (1) **Dictation** from the original or modified protocols for the purposes of creating a text-based patient record on paper, or in a word processing document; (2) **Copying** from the original or modified protocols into a text-based patient record on paper, or in a word processing document; (3) The use of a **computerized system** for items (1) and (2), provided that the protocol data is stored intact as a single text-based document, and is not stored as multiple discrete data fields.

Other than uses (1), (2), and (3) above, the CAP does not authorize any use of the Protocols in electronic medical records systems, pathology informatics systems, cancer registry computer systems, computerized databases, mappings between coding works, or any computerized system without a written license from the CAP.

Any public dissemination of the original or modified protocols is prohibited without a written license from the CAP.

The College of American Pathologists offers these protocols to assist pathologists in providing clinically useful and relevant information when reporting results of surgical specimen examinations of surgical specimens. The College regards the reporting elements in the "Surgical Pathology Cancer Case Summary" portion of the protocols as essential elements of the pathology report. However, the manner in which these elements are reported is at the discretion of each specific pathologist, taking into account clinician preferences, institutional policies, and individual practice.

The College developed these protocols as an educational tool to assist pathologists in the useful reporting of relevant information. It did not issue the protocols for use in litigation, reimbursement, or other contexts. Nevertheless, the College recognizes that the protocols might be used by hospitals, attorneys, payers, and others. Indeed, effective January 1, 2004, the Commission on Cancer of the American College of Surgeons mandated the use of the required data elements of the protocols as part of its Cancer Program Standards for Approved Cancer Programs. Therefore, it becomes even more important for pathologists to familiarize themselves with these documents. At the same time, the College cautions that use of the protocols other than for their intended educational purpose may involve additional considerations that are beyond the scope of this document.

The inclusion of a product name or service in a CAP publication should not be construed as an endorsement of such product or service, nor is failure to include the name of a product or service to be construed as disapproval.

CAP Uveal Melanoma Protocol Revision History

Version Code

The definition of the version code can be found at www.cap.org/cancerprotocols.

Version: UvealMelanoma 3.2.0.0

Summary of Changes

The following changes have been made since the November 2011 release.

Resection

+ Additional Pathologic Findings

"Microvascular patterns" was changed to "Extravascular matrix pattern."

Surgical Pathology Cancer Case Summary

Protocol web posting date: October 2013

UVEAL MELANOMA: Resection (Local Resection, Enucleation, Limited or Complete Exenteration) (Note A)

Select a single response unless otherwise indicated.

Procedure

- Local resection
 Enucleation
 Limited exenteration
 Complete exenteration
 Other (specify): _____
 Not specified

Specimen Size

For Enucleation

- Anteroposterior diameter: ___ mm
 Horizontal diameter: ___ mm
 Vertical diameter: ___ mm
 Length of optic nerve: ___ mm
 Diameter of optic nerve: ___ mm
 Cannot be determined (see Comment)

For Exenteration

- Greatest dimension: ___ mm
 + Additional dimensions: ___ x ___ mm
 Cannot be determined (see Comment)

Specimen Laterality

- Right
 Left
 Unspecified

Tumor Site (macroscopic examination/transillumination) (select all that apply) (Note B)

- Cannot be determined
 Superotemporal quadrant of globe
 Superonasal quadrant of globe
 Inferotemporal quadrant of globe
 Inferonasal quadrant of globe
 Other (specify): _____

+ Tumor Basal Size on Transillumination

- Cannot be determined
 Specify: ___ x ___ mm

Tumor Size After Sectioning (Note C) Cannot be determined

Base at cut edge: ___ mm

+ Height at cut edge: ___ mm

Greatest height: ___ mm

+ Tumor Location After Sectioning (Note D)+ Cannot be determined+ Distance from anterior edge of tumor to limbus at cut edge: ___ mm+ Distance of posterior margin of tumor base from edge of optic disc: ___ mm**Tumor Involvement of Other Ocular Structures (select all that apply)** Cannot be determined Sclera Vortex vein(s) Optic disc Vitreous Choroid Ciliary body Iris Lens Anterior chamber Extrascleral extension (anterior) Extrascleral extension (posterior) Angle/Schlemm's canal Optic nerve Retina+ Cornea**Growth Pattern** Cannot be determined Solid mass Diffuse (ciliary body ring) Diffuse (flat)**Histologic Type (Note E)** Cannot be determined Spindle cell type+ Spindle cell type, spindle A+ Spindle cell type, spindle B Epithelioid cell type Mixed cell type Necrotic**Histopathologic Type (Note E)** Spindle cell melanoma (greater than 90% spindle cells) Mixed cell melanoma (>10% epithelioid cells and <90% spindle cells) Epithelioid cell melanoma (greater than 90% epithelioid cells)

Histologic Grade (pG)#

___pGX: Grade cannot be assessed

___pG1: Spindle cell melanoma

___pG2: Mixed cell melanoma

___pG3: Epithelioid cell melanoma

Because of general lack of agreement regarding which proportion of epithelioid cells classifies a tumor as mixed and epithelioid in type, some ophthalmic pathologists currently combine grades 2 and 3 (nonspindle, epithelioid cells detected) and contrast them with grade 1 (spindle, no epithelioid cells detected).

Microscopic Tumor Extension

+ Tumor Location

- + ___ Anterior margin between equator and iris
- + ___ Anterior margin between disc and equator
- + ___ Posterior margin between equator and iris
- + ___ Posterior margin between disc and equator
- + ___ Cannot be determined
- + ___ None of above

Scleral Involvement

- ___ Cannot be determined
- ___ None
- ___ Extrascleral
- ___ Intrasccleral

Margins

- ___ Cannot be assessed
- ___ No melanoma at margins
- ___ Extrascleral extension (for enucleation specimens)
- ___ Other margin(s) involved (specify): _____

Pathologic Staging (pTNM) (Note F)

TNM Descriptors (required only if applicable) (select all that apply)

- ___ m (multiple primary tumors)
- ___ r (recurrent)
- ___ y (post-treatment)

+ Data elements preceded by this symbol are not required. However, these elements may be clinically important but are not yet validated or regularly used in patient management.

Primary Tumor (pT)*Iris*

- pTX: Primary tumor cannot be assessed
- pT0: No evidence of primary tumor
- pT1: Tumor limited to the iris
 - pT1a: Tumor limited to the iris not more than 3 clock hours in size
 - pT1b: Tumor limited to the iris more than 3 clock hours in size
 - pT1c: Tumor limited to the iris with secondary glaucoma
- pT2: Tumor confluent with or extending into the ciliary body, choroid, or both
 - pT2a: Tumor confluent with or extending into the ciliary body, choroid, or both, with secondary glaucoma
 - pT3: Tumor confluent with or extending into the ciliary body, choroid, or both, with scleral extension
 - pT3a: Tumor confluent with or extending into the ciliary body, choroid, or both, with scleral extension and secondary glaucoma
- pT4: Tumor with extrascleral extension
 - pT4a: Tumor with extrascleral extension less than or equal to 5 mm in diameter
 - pT4b: Tumor with extrascleral extension more than 5 mm in diameter

Ciliary Body and Choroid

- pTX: Primary tumor cannot be assessed
- pT0: No evidence of primary tumor
- pT1: Tumor size category 1
 - pT1a: Tumor size category 1 without ciliary body involvement and extraocular extension
 - pT1b: Tumor size category 1 with ciliary body involvement
 - pT1c: Tumor size category 1 without ciliary body involvement but with extraocular extension less than or equal to 5 mm in diameter
 - pT1d: Tumor size category 1 with ciliary body involvement and extraocular extension less than or equal to 5 mm in diameter
- pT2: Tumor size category 2
 - pT2a: Tumor size category 2 without ciliary body involvement and extraocular extension
 - pT2b: Tumor size category 2 with ciliary body involvement
 - pT2c: Tumor size category 2 without ciliary body involvement but with extraocular extension less than or equal to 5 mm in diameter
 - pT2d: Tumor size category 2 with ciliary body involvement and extraocular extension less than or equal to 5 mm in diameter
- pT3: Tumor size category 3
 - pT3a: Tumor size category 3 without ciliary body involvement and extraocular extension
 - pT3b: Tumor size category 3 with ciliary body involvement
 - pT3c: Tumor size category 3 without ciliary body involvement but with extraocular extension less than or equal to 5 mm in diameter
 - pT3d: Tumor size category 3 with ciliary body involvement and extraocular extension less than or equal to 5 mm in diameter
- pT4: Tumor size category 4
 - pT4a: Tumor size category 4 without ciliary body involvement and extraocular extension
 - pT4b: Tumor size category 4 with ciliary body involvement
 - pT4c: Tumor size category 4 without ciliary body involvement but with extraocular extension less than or equal to 5 mm in diameter
 - pT4d: Tumor size category 4 with ciliary body involvement and extraocular extension less than or equal to 5 mm in diameter
 - pT4e: Any tumor size category with extraocular extension more than 5 mm in diameter

+ Data elements preceded by this symbol are not required. However, these elements may be clinically important but are not yet validated or regularly used in patient management.

Regional Lymph Nodes (pN)

- pNX: Regional lymph nodes cannot be assessed
- pN0: No regional lymph node metastasis
- pN1: Regional lymph node metastasis

Distant Metastasis (pM)

- Not applicable
- pM1: Distant metastasis
- pM1a: Largest diameter of the largest metastasis 3 cm or less
- pM1b: Largest diameter of the largest metastasis 3.1-8.0 cm
- pM1c: Largest diameter of the largest metastasis 8.1 cm or more

+ Additional Pathologic Findings (select all that apply) (Note G)

- + None identified
- + Mitotic rate (number of mitoses per 40X objective with a field area of 0.152 mm²)
(specify): _____
- + Extravascular matrix pattern
- + Vascular invasion (tumor vessels or other vessels)
- + Degree of pigmentation
- + Inflammatory cells/tumor infiltrating lymphocytes
- + Drusen
- + Retinal detachment
- + Invasion of Bruch's membrane
- + Nevus
- + Hemorrhage
- + Neovascularization
- + Other (specify): _____

+ Comment(s)

Explanatory Notes

A. Fixative

The minimum recommended fixation time for whole globes with intraocular tumors is 48 hours. The globe should be fixed in an adequate volume of fixative with a 10:1 ratio of fixative volume to specimen volume recommended. Incisions or windows in the globe are not necessary for adequate penetration of fixative and are not recommended. Injection of fixative into the globe is also not recommended.

B. Orientation

The orientation of a globe may be determined by identification of extraocular muscle insertions, the optic nerve, and other landmarks, as illustrated in Figure 1. The terms *temporal* and *nasal* are generally used in place of *lateral* and *medial* with reference to ocular anatomy.

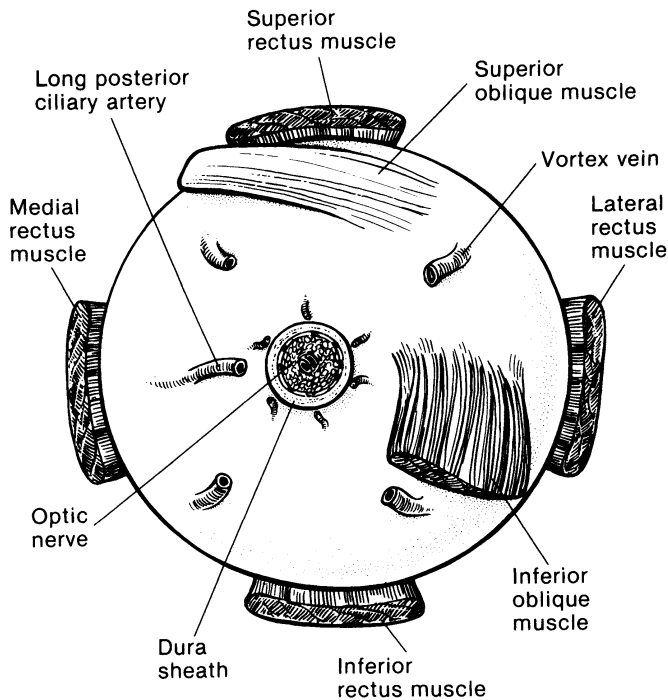


Figure 1. Anatomic landmarks of the posterior aspect of the globe (right eye). The position of the inferior oblique muscle relative to the optic nerve is most helpful in orienting the globe. The inferior oblique muscle insertion is located temporal (lateral) to the optic nerve on the sclera, and its fibers travel inferonasally from its insertion. The long posterior ciliary artery is often seen as a blue-gray line in the sclera on either side of the optic nerve and marks the horizontal meridian of the globe. Reprinted with permission from WB Saunders Company.

C. Tumor Size

Tumor size has prognostic significance. Many studies of choroidal and ciliary body melanoma have defined small tumors as being less than 10 mm in greatest diameter.¹ More recently, an ongoing study started in 1986, the Collaborative Ocular Melanoma Study^{2,3} defined the following size classification based on clinical measurements.

Small tumors#:	Smaller than medium or large tumors defined below
Medium tumors:	Greater than or equal to 2.5 mm, less than or equal to 10 mm in height, and less than or equal to 16 mm in basal diameter

Large tumors: Greater than 10 mm in height *or*
 Greater than 2 mm in height and greater than 16 mm in basal diameter *or*
 Greater than 8 mm in height with optic nerve involvement

Small tumors have a more favorable prognosis.^{4,5}

D. Sectioning the Globe

The globe is generally sectioned in the horizontal or vertical plane, with care to include the pupil and optic nerve in the section to be submitted for microscopic examination. If the mass cannot be included with horizontal or vertical sectioning, the globe is sectioned obliquely to include the tumor, pupil, and optic nerve, as illustrated in Figure 2. Alternative methods of sectioning have been described.⁶

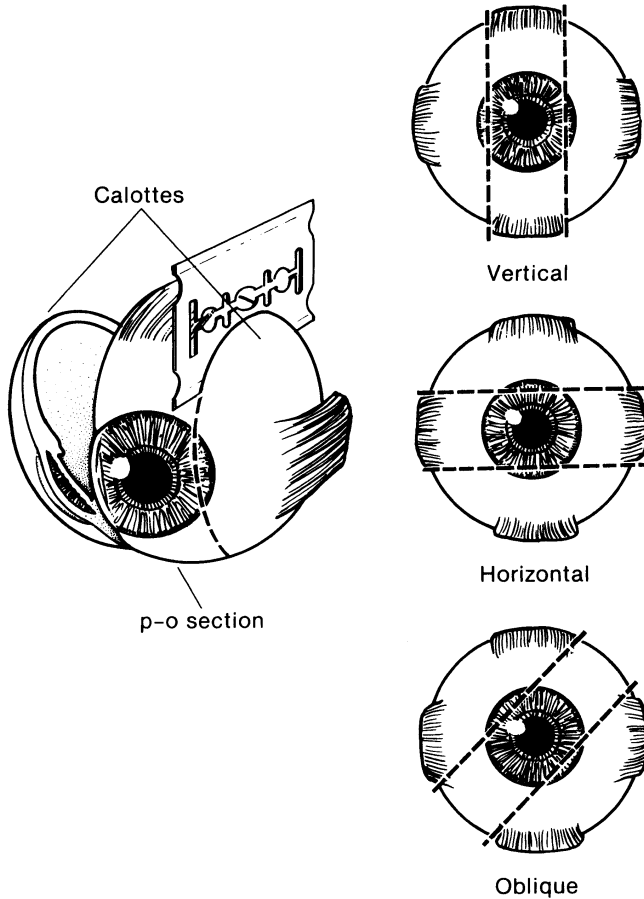


Figure 2. The most common methods of sectioning a globe. After transillumination, the tumor base is marked, if possible, and included in the pupil-optic (p-o) nerve section and submitted for processing. If tumor is found in either of the calottes, these may also be submitted for sectioning. The meridian in which the globe was sectioned should be included in the gross description of the pathology report. It is not uncommon to induce an artifactual retinal detachment while sectioning the globe. This can be minimized by gentle handling and by avoiding a sawing motion with the blade. Reprinted with permission from WB Saunders Company.

E. Histologic Type

The modified Callender classification shown below is used for determining cell type, but has prognostic significance only for tumors of the choroid and ciliary body, not those of the iris, which generally have a benign course.^{1,7-9} The American Joint Committee on Cancer (AJCC) defined the histopathologic types as follows¹⁰:#

Spindle cell melanoma (greater than 90% spindle cells)

Mixed cell melanoma (>10% epithelioid cells and <90% spindle cells)

Epithelioid cell melanoma (greater than 90% epithelioid cells)

Spindle cell melanomas have the most favorable prognosis, and epithelioid cell melanomas the least favorable in terms of survival.

F. TNM Stage Groupings

The American Joint Committee on Cancer (AJCC) and the International Union Against Cancer (UICC) TNM staging systems for uveal melanoma of the iris, ciliary body, and choroid are shown below.¹⁰

By AJCC/UICC convention, the designation "T" refers to a primary tumor that has not been previously treated. The symbol "p" refers to the pathologic classification of the TNM, as opposed to the clinical classification, and is based on gross and microscopic examination. pT entails a resection of the primary tumor or biopsy adequate to evaluate the highest pT category, pN entails removal of nodes adequate to validate lymph node metastasis, and pM implies microscopic examination of distant lesions. Clinical classification (cTNM) is usually carried out by the referring physician before treatment during initial evaluation of the patient or when pathologic classification is not possible.

Pathologic staging is usually performed after surgical resection of the primary tumor. Pathologic staging depends on pathologic documentation of the anatomic extent of disease, whether or not the primary tumor has been completely removed. If a biopsied tumor is not resected for any reason (eg, when technically unfeasible) and if the highest T and N categories or the M1 category of the tumor can be confirmed microscopically, the criteria for pathologic classification and staging have been satisfied without total removal of the primary cancer.

Primary Tumor

All Uveal Melanomas

TX Primary tumor cannot be assessed
T0 No evidence of primary tumor

Iris#

T1 Tumor limited to the iris
T1a Tumor limited to the iris not more than 3 clock hours in size
T1b Tumor limited to the iris more than 3 clock hours in size
T1c Tumor limited to the iris with secondary glaucoma
T2 Tumor confluent with or extending into the ciliary body, choroid, or both
T2a Tumor confluent with or extending into the ciliary body, choroid, or both, with secondary glaucoma
T3 Tumor confluent with or extending into the ciliary body, choroid or both, with scleral extension
T3a Tumor confluent with or extending into the ciliary body, choroid or both, with scleral extension and secondary glaucoma
T4 Tumor with extrascleral extension
T4a Tumor with extrascleral extension less than or equal to 5 mm in diameter
T4b Tumor with extrascleral extension more than 5 mm in diameter

Iris melanomas originate from, and are predominantly located in, this region of the uvea. If less than half of the tumor volume is located within the iris, the tumor may have originated in the ciliary body, and consideration should be given to classifying it accordingly.

Ciliary Body and Choroid

Primary ciliary body and choroidal melanomas are classified according to the 4 tumor size categories below¹⁰:

Thickness (mm)		Largest basal diameter (mm)						
		≤ 3.0	3.1-6.0	6.1-9.0	9.1-12.0	12.1-15.0	15.1-18.0	>18
>15						4	4	4
12.1-15.0					3	3	4	4
9.1-12.0			3	3	3	3	3	4
6.1-9.0		2	2	2	2	3	3	4
3.1-6.0		1	1	1	2	2	3	4
≤ 3.0		1	1	1	1	2	2	4

- T1 Tumor size category 1
 - T1a Tumor size category 1 without ciliary body involvement and extraocular extension
 - T1b Tumor size category 1 with ciliary body involvement
 - T1c Tumor size category 1 without ciliary body involvement but with extraocular extension less than or equal to 5 mm in diameter
 - T1d Tumor size category 1 with ciliary body involvement and extraocular extension less than or equal to 5 mm in diameter

- T2 Tumor size category 2
 - T2a Tumor size category 2 without ciliary body involvement and extraocular extension
 - T2b Tumor size category 2 with ciliary body involvement
 - T2c Tumor size category 2 without ciliary body involvement but with extraocular extension less than or equal to 5 mm in diameter
 - T2d Tumor size category 2 with ciliary body involvement and extraocular extension less than or equal to 5 mm in diameter

- T3 Tumor size category 3
 - T3a Tumor size category 3 without ciliary body involvement and extraocular extension
 - T3b Tumor size category 3 with ciliary body involvement
 - T3c Tumor size category 3 without ciliary body involvement but with extraocular extension less than or equal to 5 mm in diameter
 - T3d Tumor size category 3 with ciliary body involvement and extraocular extension less than or equal to 5 mm in diameter

- T4 Tumor size category 4
 - T4a Tumor size category 4 without ciliary body involvement and extraocular extension
 - T4b Tumor size category 4 with ciliary body involvement
 - T4c Tumor size category 4 without ciliary body involvement but with extraocular extension less than or equal to 5 mm in diameter
 - T4d Tumor size category 4 with ciliary body involvement and extraocular extension less than or equal to 5 mm in diameter
 - T4e Any tumor size category with extraocular extension more than 5 mm in diameter

Note: In clinical practice, the largest tumor basal diameter may be estimated in optic disc diameters (dd, average: 1 dd = 1.5 mm). Tumor thickness may be estimated in diopters (average: 2.5 diopters = 1 mm). However, techniques such as ultrasonography and fundus photography are used to provide more accurate measurements. Ciliary body involvement can be evaluated by the slit-lamp, ophthalmoscopy, gonioscopy, and transillumination. However, high-frequency ultrasonography

(ultrasound biomicroscopy) is used for more accurate assessment. Extension through the sclera is evaluated visually before and during surgery, and with ultrasonography, computed tomography, or magnetic resonance imaging.

When histopathologic measurements are recorded after fixation, tumor diameter and thickness may be underestimated because of tissue shrinkage.

Regional Lymph Nodes (N)

NX Regional lymph nodes cannot be assessed
 N0 No regional lymph node metastasis
 N1 Regional lymph node metastasis

Distant Metastasis (M)

M0 No distant metastasis
 M1 Distant metastasis
 M1a Largest diameter of the largest metastasis 3 cm or less
 M1b Largest diameter of the largest metastasis 3.1-8.0 cm
 M1c Largest diameter of the largest metastasis 8.1 cm or more

Stage Grouping

Stage I	T1a	N0	M0
Stage IIA	T1b-d	N0	M0
	T2a	N0	M0
Stage IIB	T2b	N0	M0
	T3a	N0	M0
Stage IIIA	T2c-d	N0	M0
	T3b-c	N0	M0
	T4a	N0	M0
Stage IIIB	T3d	N0	M0
	T4b-c	N0	M0
Stage IIIC	T4d-e	N0	M0
Stage IV	Any T	N1	M0
	Any T	Any N	M1a-c

It should be noted that regional lymph node involvement is rare in uveal melanoma, but metastasis to the liver and direct extension into the orbit are more common.¹⁰

TNM Descriptors

For identification of special cases of TNM or pTNM classifications, the “m” suffix and “y,” “r,” and “a” prefixes are used. Although they do not affect the stage grouping, they indicate cases needing separate analysis.

The “m” suffix indicates the presence of multiple primary tumors in a single site and is recorded in parentheses: pT(m)NM.

The “y” prefix indicates those cases in which classification is performed during or following initial multimodality therapy (ie, neoadjuvant chemotherapy, radiation therapy, or both chemotherapy and radiation therapy). The cTNM or pTNM category is identified by a “y” prefix. The ycTNM or ypTNM categorizes the extent of tumor actually present at the time of that examination. The “y” categorization is not an estimate of tumor prior to multimodality therapy (ie, before initiation of neoadjuvant therapy).

The “r” prefix indicates a recurrent tumor when staged after a documented disease-free interval, and is identified by the “r” prefix: rTNM.

The “a” prefix designates the stage determined at autopsy: aTNM.

Additional Descriptors

Residual Tumor (R)

Tumor remaining in a patient after therapy with curative intent (eg, surgical resection for cure) is categorized by a system known as R classification, shown below.

RX	Presence of residual tumor cannot be assessed
R0	No residual tumor
R1	Microscopic residual tumor
R2	Macroscopic residual tumor

For the surgeon, the R classification may be useful to indicate the known or assumed status of the completeness of a surgical excision. For the pathologist, the R classification is relevant to the status of the margins of a surgical resection specimen. That is, tumor involving the resection margin on pathologic examination may be assumed to correspond to residual tumor in the patient and may be classified as macroscopic or microscopic according to the findings at the specimen margin(s).

Lymph-Vascular Invasion (LVI)

LVI indicates whether microscopic lymph-vascular invasion is identified in the pathology report. LVI includes lymphatic invasion, vascular invasion, or lymph-vascular invasion. By AJCC/UICC convention, LVI does not affect the T category indicating local extent of tumor unless specifically included in the definition of a T category.

G. Other Pathologic Features of Prognostic Significance

Other histologic features with prognostic significance in choroidal and ciliary body melanoma include the number of mitoses in 40 high-powered fields, pigmentation, degree of inflammation, growth pattern (diffuse choroidal melanomas and ring melanomas of the ciliary body have a much less favorable prognosis), location of anterior margin of tumor, degree and patterns of vascularity, blood vessel invasion (both tumor vessels and normal vessels), tumor necrosis, extraocular extension, and optic nerve involvement.^{1,11-19}

References

1. Zimmerman LE. Malignant melanoma of the uveal tract. In: Spencer WH, ed. *Ophthalmic Pathology. An Atlas and Textbook*. 3rd ed. Philadelphia, Pa: WB Saunders Co; 1986:2072-2139.
2. The Collaborative Ocular Melanoma Study Group. Design and methods of a clinical trial for a rare condition: COMS report no. 3. The Collaborative Ocular Melanoma Study Group. *Control Clin Trials*. 1993;14:362-391.
3. Collaborative Ocular Melanoma Study Group. *COMS Manual of Procedures*. Springfield, Va: National Technical Information Service; 1989. NTIS Accession No. PB90-115536.
4. McLean IW, Foster WD, Zimmerman LE. Prognostic factors in small malignant melanomas of choroid and ciliary body. *Arch Ophthalmol*. 1977;95:48-58.
5. Affeldt JC, Minckler DS, Azen SP, Yeh L. Prognosis in uveal melanoma with extraocular extension. *Arch Ophthalmol*. 1980;98:1975-1979.
6. Folberg R, Verdick R, Weingeist TA, Montague PR. The gross examination of eyes removed for choroidal and ciliary body melanomas. *Ophthalmology*. 1986;93:1643-1647.
7. Callender GR. Malignant melanotic tumors of the eye: a study of histologic types in 111 cases. *Trans Am Acad Ophthalmol Otolaryngol*. 1931;36:131-142.

8. McLean IW, Zimmerman LE, Evans RM. Reappraisal of Callender's spindle A type of malignant melanoma of choroid and ciliary body. *Am J Ophthalmol.* 1978; 86:557-564.
9. McLean IW, Foster WD, Zimmerman LE. Modifications of Callender's classification of uveal melanoma at the Armed Forces Institute of Pathology. *Am J Ophthalmol.* 1983;96:502-509.
10. Chapter 43: Malignant melanoma of the uvea. In: Edge SD, Byrd DR, Carducci MA, Compton CC, eds. *AJCC Cancer Staging Manual.* 7th ed. New York, NY: Springer; 2009.
11. Font RL, Spaulding AG, Zimmerman LE. Diffuse malignant melanoma of the uveal tract: a clinicopathologic report of 54 cases. *Trans Am Acad Ophthalmol Otolaryngol.* 1968;72:877-894.
12. McLean IW, Foster WD, Zimmerman LE. Uveal melanoma: location, size, cell type, and enucleation as risk factors in metastasis. *Hum Pathol.* 1982;13:123-132.
13. Weinhaus RS, Seddon JM, Albert DM, Gragoudas ES, Robinson N. Prognostic factor study of survival after enucleation for juxtapapillary melanomas. *Arch Ophthalmol.* 1985;103:1673-1677.
14. Gamel JW, McCurdy JB, McLean IW. A comparison of prognostic covariates for uveal melanoma. *Invest Ophthalmol Vis Sci.* 1992;33:1919-1922.
15. Folberg R, Peier J, Gruman LM, et al. The morphologic characteristics of tumor blood vessels as a marker of tumor progression in primary human uveal melanoma: a matched case-control study. *Hum Pathol.* 1992;23:1298-1305.
16. Coleman K, Baak JP, Van Diest P, Mullaney J, Farrell M, Fenton M. Prognostic factors following enucleation of 111 uveal melanomas. *Br J Ophthalmol.* 1993;77:688-692.
17. Folberg R, Rummelt V, Parys-Van Ginderdeuren R, et al. The prognostic value of tumor blood vessel morphology in primary uveal melanoma. *Ophthalmology.* 1993;100:1389-1398.
18. Folberg R, Rummelt V, Gruman LM, et al. Microcirculation architecture of melanocytic nevi and malignant melanomas of the ciliary body and choroid: a comparative histopathologic and ultrastructural study. *Ophthalmology.* 1994;101:718-727.
19. Rummelt V, Folberg R, Woolson RF, Hwang T, Peier J. Relation between the microcirculation architecture and the aggressive behavior of ciliary body melanomas. *Ophthalmology.* 1995;102:844-851.