

Protocol for the Examination of Specimens From Patients With Uveal Melanoma

Version: UvealMelanoma 4.0.0.0

Protocol Posting Date: June 2017

Includes pTNM requirements from the 8th Edition, AJCC Staging Manual

For accreditation purposes, this protocol should be used for the following procedures AND tumor types:

Procedure	Description
Resection	Includes local resection, enucleation, and partial or complete exenteration
Tumor Type	Description
Uveal melanoma	

The following tumor types should NOT be reported using this protocol:

Tumor Type
Cutaneous melanoma (consider Skin Melanoma protocol)

Authors

Hans E. Grossniklaus, MD, MBA*; Paul T. Finger, MD; J. William Harbour, MD; Tero Kivëla, MD

With guidance from the CAP Cancer and CAP Pathology Electronic Reporting Committees.

** Denotes primary author. All other contributing authors are listed alphabetically.*

Accreditation Requirements

This protocol can be utilized for a variety of procedures and tumor types for clinical care purposes. For accreditation purposes, only the definitive primary cancer resection specimen is required to have the core and conditional data elements reported in a synoptic format.

- Core data elements are required in reports to adequately describe appropriate malignancies. For accreditation purposes, essential data elements must be reported in all instances, even if the response is “not applicable” or “cannot be determined.”
- Conditional data elements are only required to be reported if applicable as delineated in the protocol. For instance, the total number of lymph nodes examined must be reported, but only if nodes are present in the specimen.
- Optional data elements are identified with “+” and although not required for CAP accreditation purposes, may be considered for reporting as determined by local practice standards.

The use of this protocol is not required for recurrent tumors or for metastatic tumors that are resected at a different time than the primary tumor. Use of this protocol is also not required for pathology reviews performed at a second institution (ie, secondary consultation, second opinion, or review of outside case at second institution).

Synoptic Reporting

All core and conditionally required data elements outlined on the surgical case summary from this cancer protocol must be displayed in synoptic report format. Synoptic format is defined as:

- Data element: followed by its answer (response), outline format without the paired "Data element: Response" format is NOT considered synoptic.
- The data element must be represented in the report as it is listed in the case summary. The response for any data element may be modified from those listed in the case summary, including “Cannot be determined” if appropriate.
- Each diagnostic parameter pair (Data element: Response) is listed on a separate line or in a tabular format to achieve visual separation. The following exceptions are allowed to be listed on one line:
 - Anatomic site or specimen, laterality, and procedure
 - Pathologic Stage Classification (pTNM) elements
 - Negative margins, as long as all negative margins are specifically enumerated where applicable
- The synoptic portion of the report can appear in the diagnosis section of the pathology report, at the end of the report or in a separate section, but all Data element: Responses must be listed together in one location

Organizations and pathologists may choose to list the required elements in any order, use additional methods in order to enhance or achieve visual separation, or add optional items within the synoptic report. The report may have required elements in a summary format elsewhere in the report IN ADDITION TO but not as replacement for the synoptic report i.e. all required elements must be in the synoptic portion of the report in the format defined above.

CAP Laboratory Accreditation Program Protocol Required Use Date: March 2018*

* Beginning January 1, 2018, the 8th edition AJCC Staging Manual should be used for reporting pTNM.

CAP Uveal Melanoma Protocol Summary of Changes

The following data elements were modified:

Pathologic Stage Classification (pTNM, AJCC 8th Edition)

Tumor Site

Tumor Size

Tumor Involvement of Other Ocular Structures

Microscopic Tumor Extension

Additional Pathologic Findings

Surgical Pathology Cancer Case Summary

Protocol posting date: June 2017

UVEAL MELANOMA:**Select a single response unless otherwise indicated.****Procedure (Note A)**

- Local resection
 Enucleation
 Limited exenteration
 Complete exenteration
 Other (specify): _____
 Not specified

Specimen Laterality

- Right
 Left
 Not specified

Tumor Site (macroscopic examination/transillumination) (select all that apply) (Note B)

- Cannot be determined
 Superotemporal quadrant of globe
 Superonasal quadrant of globe
 Inferotemporal quadrant of globe
 Inferonasal quadrant of globe
 Anterior chamber
 Between ____ and ____ o'clock
 Other (specify): _____

Tumor Size After Sectioning (Note C)

- Cannot be determined
 Greatest basal diameter (millimeters): ____ mm
 + Base at cut edge (millimeters): ____ mm
 Greatest thickness (millimeters): ____ mm
 + Thickness at cut edge (millimeters): ____ mm

Tumor Site After Sectioning (Note D)

- Cannot be determined
 Superonasal
 Inferonasal
 Superotemporal
 Inferotemporal
 + Distance from anterior edge of tumor to limbus at cut edge (millimeters): ____ mm
 + Distance of posterior margin of tumor base from edge of optic disc (millimeters): ____ mm

Tumor Involvement of Other Ocular Structures (select all that apply)

- Sclera
 Vortex vein(s)
 Optic nerve head
 Vitreous
 Choroid
 Ciliary body
 Iris

+ Data elements preceded by this symbol are not required for accreditation purposes. These optional elements may be clinically important but are not yet validated or regularly used in patient management.

- Lens
- Anterior chamber
- Extrascleral extension (anterior)
- Extrascleral extension (posterior)
- Angle/Schlemm's canal
- Optic nerve
- Retina
- + Cornea
- Other (specify): _____
- Cannot be assessed

Growth Pattern

- Cannot be determined
- Solid mass
- Dome shape
- Mushroom shape
- Diffuse (ciliary body ring)
- Diffuse (flat)

Histologic Type (Note E)

- Spindle cell melanoma (>90% spindle cells)
- Mixed cell melanoma (>10% epithelioid cells and <90% spindle cells)
- Epithelioid cell melanoma (>90% epithelioid cells)

Tumor Extension

- + Tumor Location
- + Anterior margin between ciliary body and iris
- + Anterior margin between equator and ciliary body
- + Anterior margin between disc and equator
- + Posterior margin between ciliary body and iris
- + Posterior margin between equator and ciliary body
- + Posterior margin between disc and equator
- + Cannot be determined
- + Other (specify): _____

Scleral Involvement

- None
- Intrasceral
- Extrascleral (≤5 mm largest diameter)
- Extrascleral (>5 mm largest diameter)
- Cannot be determined

Margins

- Cannot be assessed
- No melanoma at margins
- Extrascleral extension (for enucleation specimens)
- Other margin(s) involved (specify): _____

Regional Lymph Nodes

- No lymph nodes submitted or found

Lymph Node Examination (required only if lymph nodes are present in the specimen)

Number of Lymph Nodes Involved: _____
 ___ Number cannot be determined (explain): _____

Number of Lymph Nodes Examined: _____
 ___ Number cannot be determined (explain): _____

Pathologic Stage Classification (pTNM, AJCC 8th Edition) (Note F)

Note: Reporting of pT, pN, and (when applicable) pM categories is based on information available to the pathologist at the time the report is issued. Only the applicable T, N, or M category is required for reporting; their definitions need not be included in the report. The categories (with modifiers when applicable) can be listed on 1 line or more than 1 line.

TNM Descriptors (required only if applicable) (select all that apply)

- ___ m (multiple primary tumors)
 ___ r (recurrent)
 ___ y (posttreatment)

Primary Tumor (pT)*Iris*

- ___ pTX: Primary tumor cannot be assessed
 ___ pT0: No evidence of primary tumor
 ___ pT1: Tumor limited to the iris
 ___ pT1a: Tumor limited to the iris not more than 3 clock hours in size
 ___ pT1b: Tumor limited to the iris more than 3 clock hours in size
 ___ pT1c: Tumor limited to the iris with secondary glaucoma
 ___ pT2: Tumor confluent with or extending into the ciliary body, choroid, or both
 ___ pT2a: Tumor confluent with or extending into the ciliary body, without secondary glaucoma
 ___ pT2b: Tumor confluent with or extending into the ciliary body and choroid, without secondary glaucoma
 ___ pT2c: Tumor confluent with or extending into the ciliary body, choroid, or both, with secondary glaucoma
 ___ pT3: Tumor confluent with or extending into the ciliary body, choroid, or both, with scleral extension
 ___ pT4: Tumor with extrascleral extension
 ___ pT4a: Tumor with extrascleral extension ≤5 mm in largest diameter
 ___ pT4b: Tumor with extrascleral extension >5 mm in largest diameter

Note: Iris melanomas originate from, and are predominantly located in, this region of the uvea. If less than half the tumor volume is located within the iris, the tumor may have originated in the ciliary body, and consideration should be given to classifying it accordingly.

Ciliary Body and Choroid

- ___ pTX: Primary tumor cannot be assessed
 ___ pT0: No evidence of primary tumor
 ___ pT1: Tumor size category 1
 ___ pT1a: Tumor size category 1 without ciliary body involvement and extraocular extension
 ___ pT1b: Tumor size category 1 with ciliary body involvement
 ___ pT1c: Tumor size category 1 without ciliary body involvement but with extraocular extension ≤5 mm in largest diameter
 ___ pT1d: Tumor size category 1 with ciliary body involvement and extraocular extension ≤5 mm in largest diameter
 ___ pT2: Tumor size category 2
 ___ pT2a: Tumor size category 2 without ciliary body involvement and extraocular extension
 ___ pT2b: Tumor size category 2 with ciliary body involvement
 ___ pT2c: Tumor size category 2 without ciliary body involvement but with extraocular extension ≤5 mm in largest diameter
 ___ pT2d: Tumor size category 2 with ciliary body involvement and extraocular extension ≤5 mm in largest diameter

+ Data elements preceded by this symbol are not required for accreditation purposes. These optional elements may be clinically important but are not yet validated or regularly used in patient management.

- pT3: Tumor size category 3
- pT3a: Tumor size category 3 without ciliary body involvement and extraocular extension
- pT3b: Tumor size category 3 with ciliary body involvement
- pT3c: Tumor size category 3 without ciliary body involvement but with extraocular extension ≤ 5 mm in largest diameter
- pT3d: Tumor size category 3 with ciliary body involvement and extraocular extension ≤ 5 mm in largest diameter
- pT4: Tumor size category 4
- pT4a: Tumor size category 4 without ciliary body involvement and extraocular extension
- pT4b: Tumor size category 4 with ciliary body involvement
- pT4c: Tumor size category 4 without ciliary body involvement but with extraocular extension ≤ 5 mm in largest diameter
- pT4d: Tumor size category 4 with ciliary body involvement and extraocular extension ≤ 5 mm in largest diameter
- pT4e: Any tumor size category with extraocular extension > 5 mm in largest diameter

Notes:

1. Primary ciliary body and choroidal melanomas are classified according to the four tumor size categories defined in Figure 3.
2. In clinical practice, the largest tumor basal diameter may be estimated in optic disc diameters (DD; average: 1 DD = 1.5 mm), and tumor thickness may be estimated in diopters (average: 2.5 diopters = 1 mm). Ultrasonography and fundus photography are used to provide more accurate measurements.
3. When histopathologic measurements are recorded after fixation, tumor diameter and thickness may be underestimated because of tissue shrinkage.

Regional Lymph Nodes (pN)

- pNX: Regional lymph nodes cannot be assessed
- pN0: No regional lymph node metastasis
- pN1: Regional lymph node metastasis or discrete tumor deposits in the orbit
- pN1a: Metastasis in one or more regional lymph node(s)
- pN1b: No regional lymph nodes are positive, but there are discrete tumor deposits in the orbit that are not contiguous to the eye. (choroidal and ciliary body)

Distant Metastasis (pM) (required only if confirmed pathologically in this case)

- pM1: Distant metastasis
- pM1a: Largest diameter of the largest metastasis ≤ 3 cm
- pM1b: Largest diameter of the largest metastasis 3.1-8.0 cm
- pM1c: Largest diameter of the largest metastasis ≥ 8.1 cm

Specify sites(s), if known: _____

+ Additional Pathologic Findings (select all that apply) (Note G)

- + None identified
- + Mitotic rate (number of mitoses per 40 fields determined by using a 40X objective with a field area of 0.152 mm^2) (specify): _____
- + Extravascular matrix pattern (extracellular closed loops and networks, the latter defined as at least 3 back-to-back closed loops, is associated with death from metastatic disease)
- + Vascular invasion (tumor vessels or other vessels)
- + Degree of pigmentation
- + Inflammatory cells/tumor infiltrating lymphocytes and macrophages
- + Drusen
- + Retinal detachment
- + Invasion of Bruch's membrane
- + Nevus
- + Hemorrhage (specify site): _____
- + Neovascularization
- + Other (specify): _____

+ Data elements preceded by this symbol are not required for accreditation purposes. These optional elements may be clinically important but are not yet validated or regularly used in patient management.

+ Comment(s)

Note: *Chromosome 3 and 8 loss or gain, immunohistochemical staining for presence or absence of BAP1 protein immunoreactivity, and/or gene expression profile may be included in the report.*

Explanatory Notes

A. Fixative

The minimum recommended fixation time for whole globes with intraocular tumors is 48 hours. The globe should be fixed in an adequate volume of fixative, with a 10:1 ratio of fixative volume to specimen volume recommended. Incisions or windows in the globe are not necessary for adequate penetration of fixative and are not recommended. Injection of fixative into the globe is also not recommended.

B. Orientation

The orientation of a globe may be determined by identification of extraocular muscle insertions, the optic nerve, and other landmarks, as illustrated in Figure 1. The terms *temporal* and *nasal* are generally used in place of *lateral* and *medial* with reference to ocular anatomy.

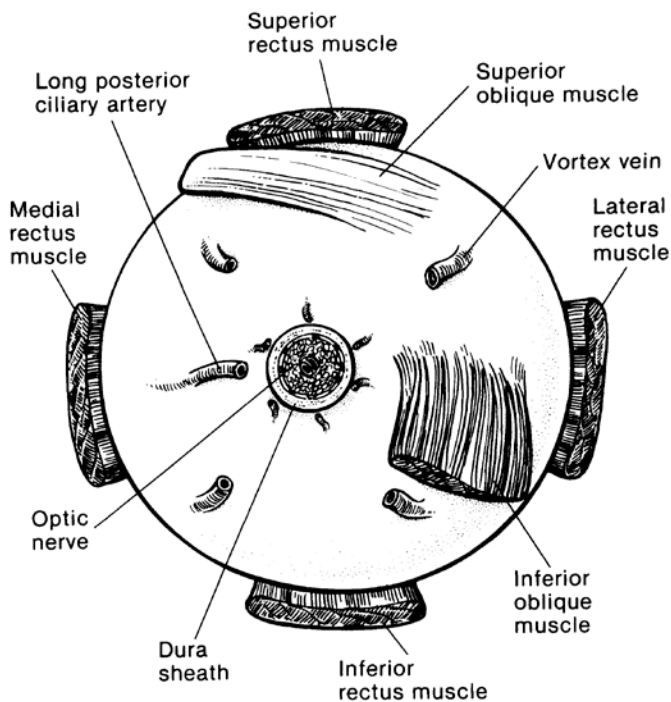


Figure 1. Anatomic landmarks of the posterior aspect of the globe (right eye). The position of the inferior oblique muscle relative to the optic nerve is most helpful in orienting the globe. The inferior oblique muscle insertion is located temporal (lateral) to the optic nerve on the sclera, and its fibers travel inferonasally from its insertion. The long posterior ciliary artery is often seen as a blue-gray line in the sclera on either side of the optic nerve and marks the horizontal meridian of the globe. Reprinted with permission from WB Saunders Company.

C. Tumor Size

Tumor size has prognostic significance. Many studies of choroidal and ciliary body melanoma have defined small tumors as being less than 10 mm in greatest diameter.¹ More recently, an ongoing study started in 1986, the Collaborative Ocular Melanoma Study,^{2,3} defined the following size classification based on clinical measurements.

Small tumors [#] :	Smaller than medium or large tumors defined below
Medium tumors:	Greater than or equal to 2.5 mm, less than or equal to 10 mm in height, and less than or equal to 16 mm in basal diameter
Large tumors:	Greater than 10 mm in height <i>or</i> Greater than 2 mm in height and greater than 16 mm in basal diameter <i>or</i> Greater than 8 mm in height with optic nerve involvement

[#] Small tumors have a more favorable prognosis.^{4,5}

Since then, the AJCC TNM system defined empirically 4 tumor sizes (Figure 3) – small (T1), medium (T2), large (T3), and very large (T4) – that differ significantly in survival prognosis.^{6,7} This size classification was externally validated and is now recommended.

D. Sectioning the Globe

The globe is generally sectioned in the horizontal or vertical plane, with care to include the pupil and optic nerve in the section to be submitted for microscopic examination. If the mass cannot be included with horizontal or vertical sectioning, the globe is sectioned obliquely to include the tumor, pupil, and optic nerve, as illustrated in Figure 2. Alternative methods of sectioning have been described.⁶

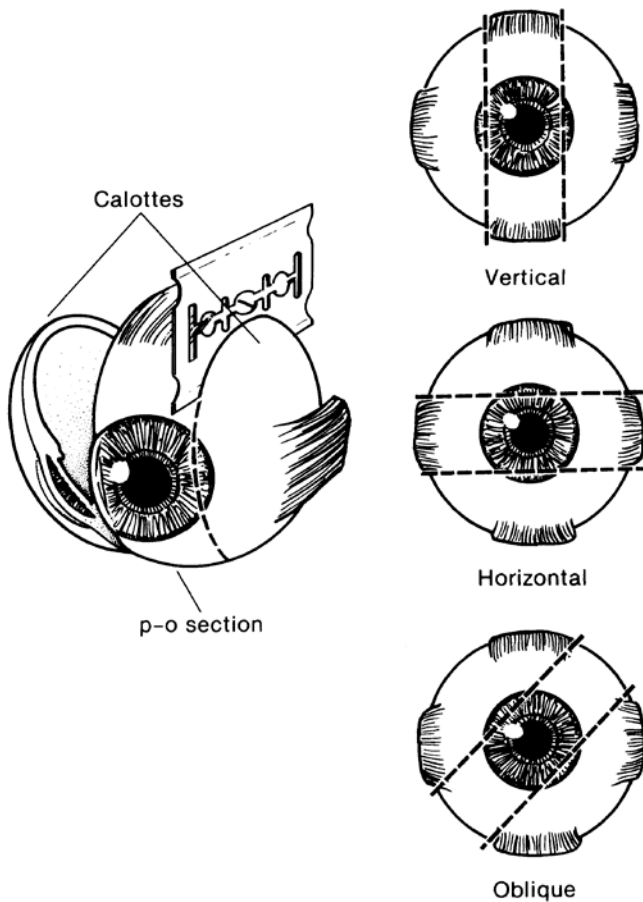


Figure 2. The most common methods of sectioning a globe. After transillumination, the tumor base is marked, if possible, and included in the pupil-optic (p-o) nerve section and submitted for processing. If tumor is found in either of the calottes, these may also be submitted for sectioning. The meridian in which the globe was sectioned should be included in the gross description of the pathology report. It is not uncommon to induce an artifactual retinal detachment while sectioning the globe. This can be minimized by gentle handling and by avoiding a sawing motion with the blade. Reprinted with permission from WB Saunders Company.

E. Histologic Type

The modified Callender classification shown below is used for determining cell type but has prognostic significance only for tumors of the choroid and ciliary body, not those of the iris, which generally have a benign course unless they invade the chamber angle.^{1,8-11} The American Joint Committee on Cancer (AJCC) defined the histopathologic types[#] as follows¹⁰:

Spindle cell melanoma (>90% spindle cells)

Mixed cell melanoma (>10% epithelioid cells and <90% spindle cells)

Epithelioid cell melanoma (>90% epithelioid cells)

Spindle cell melanomas have the most favorable prognosis, and epithelioid cell melanomas the least favorable in terms of survival.

Histologic Grade (G)

G	G Definition
GX	Grade cannot be assessed
G1	Spindle cell melanoma (>90% spindle cells)
G2	Mixed cell melanoma (>10% epithelioid cells and <90% spindle cells)
G3	Epithelioid cell melanoma (>90% epithelioid cells)

Note: Because of the lack of universal agreement regarding which proportion of epithelioid cells classifies a tumor as mixed or epithelioid, some ophthalmic pathologists currently combine grades 2 and 3 (nonspindle, ie, epithelioid cells detected) and contrast them with grade 1 (spindle, ie, no epithelioid cells detected) or even tumors that have no epithelioid cells with those that have any epithelioid cells.

F. Pathologic Stage Classification

The American Joint Committee on Cancer (AJCC) and the International Union Against Cancer (UICC) TNM staging systems for uveal melanoma of the iris, ciliary body, and choroid are shown below.¹²

By AJCC/UICC convention, the designation “T” refers to a primary tumor that has not been previously treated. The symbol “p” refers to the pathologic classification of the TNM, as opposed to the clinical classification, and is based on gross and microscopic examination. pT entails a resection of the primary tumor or biopsy adequate to evaluate the highest pT category, pN entails removal of nodes adequate to validate lymph node metastasis, and pM implies microscopic examination of distant lesions. Clinical classification (cTNM) is usually carried out by the referring physician before treatment during initial evaluation of the patient or when pathologic classification is not possible.

Pathologic staging is usually performed after surgical resection of the primary tumor. Pathologic staging depends on pathologic documentation of the anatomic extent of disease, whether or not the primary tumor has been completely removed. If a biopsied tumor is not resected for any reason (eg, when technically unfeasible) and if the highest T and N categories or the M1 category of the tumor can be confirmed microscopically, the criteria for pathologic classification and staging have been satisfied without total removal of the primary cancer.

TNM Descriptors

For identification of special cases of TNM or pTNM classifications, the “m” suffix and “y,” “r,” and “a” prefixes are used. Although they do not affect the stage grouping, they indicate cases needing separate analysis.

The “m” suffix indicates the presence of multiple primary tumors in a single site and is recorded in parentheses: pT(m)NM.

The “y” prefix indicates those cases in which classification is performed during or following initial multimodality therapy (ie, neoadjuvant chemotherapy, radiation therapy, or both chemotherapy and radiation therapy). The cTNM or pTNM category is identified by a “y” prefix. The ycTNM or ypTNM categorizes the extent of tumor actually present at the time of that examination. The “y” categorization is not an estimate of tumor prior to multimodality therapy (ie, before initiation of neoadjuvant therapy).

The “r” prefix indicates a recurrent tumor when staged after a documented disease-free interval, and is identified by the “r” prefix: rTNM.

The “a” prefix designates the stage determined at autopsy: aTNM.

Additional Descriptors

Residual Tumor (R)

Tumor remaining in a patient after therapy with curative intent (eg, surgical resection for cure) is categorized by a system known as R classification, shown below.

- RX Presence of residual tumor cannot be assessed
- R0 No residual tumor
- R1 Microscopic residual tumor
- R2 Macroscopic residual tumor

For the surgeon, the R classification may be useful to indicate the known or assumed status of the completeness of a surgical excision. For the pathologist, the R classification is relevant to the status of the margins of a surgical resection specimen. That is, tumor involving the resection margin on pathologic examination may be assumed to correspond to residual tumor in the patient and may be classified as macroscopic or microscopic according to the findings at the specimen margin(s).

T Category Considerations

Iris melanomas originate from, and are predominantly located in, this region of the uvea. If less than half of the tumor volume is located within the iris, the tumor may have originated in the ciliary body, and consideration should be given to classifying it accordingly.

Ciliary Body and Choroid

Primary ciliary body and choroidal melanomas are classified according to the 4 tumor size categories below¹²:

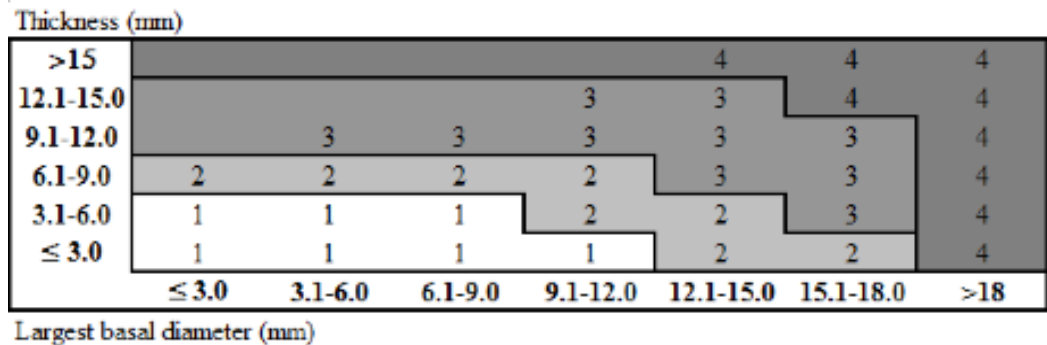


Figure 3.

In clinical practice, the largest tumor basal diameter may be estimated in optic disc diameters (dd, average: 1 dd = 1.5 mm). Tumor thickness may be estimated in diopters (average: 2.5 diopters = 1 mm). However, techniques such as ultrasonography and fundus photography are used to provide more accurate measurements. Ciliary body involvement can be evaluated by the slit-lamp, ophthalmoscopy, gonioscopy, and transillumination. However, high-frequency ultrasonography (ultrasound biomicroscopy) is used for more accurate assessment. Extension through the sclera is evaluated visually before and during surgery, and with ultrasonography, computed tomography, or magnetic resonance imaging.

When histopathologic measurements are recorded after fixation, tumor diameter and thickness may be underestimated because of tissue shrinkage.

Lymph-Vascular Invasion (LVI)

LVI indicates whether microscopic lymph-vascular invasion is identified in the pathology report. LVI includes lymphatic invasion, vascular invasion, or lymph-vascular invasion. By AJCC/UICC convention, LVI does not affect the T category indicating local extent of tumor unless specifically included in the definition of a T category. It should be noted that regional lymph node involvement is rare in uveal melanoma, but metastasis to the liver and direct extension into the orbit are more common.¹²

Stage Grouping

Stage I	T1a	N0	M0
Stage IIA	T1b-d	N0	M0
	T2a	N0	M0

Stage IIB	T2b	N0	M0
	T3a	N0	M0
Stage IIIA	T2c-d	N0	M0
	T3b-c	N0	M0
	T4a	N0	M0
Stage IIIB	T3d	N0	M0
	T4b-c	N0	M0
Stage IIIC	T4d-e	N0	M0
Stage IV	Any T	N1	M0
	Any T	Any N	M1a-c

G. Other Pathologic Features of Prognostic Significance

Other histologic features with prognostic significance in choroidal and ciliary body melanoma include the number of mitoses in 40 high-powered fields, pigmentation, degree of inflammation, number of tumor infiltrating macrophages, growth pattern (diffuse choroidal melanomas and ring melanomas of the ciliary body have a much less favorable prognosis), location of anterior margin of tumor, degree and patterns of vascularity, blood vessel invasion (both tumor vessels and normal vessels), tumor necrosis, extraocular extension, optic nerve involvement, and lack of nuclear BAP1 immunostaining.^{1,13-27}

References

- Zimmerman LE. Malignant melanoma of the uveal tract. In: Spencer WH, ed. *Ophthalmic Pathology: An Atlas and Textbook*. 3rd ed. Philadelphia, PA: WB Saunders Co; 1986:2072-2139.
- The Collaborative Ocular Melanoma Study Group. Design and methods of a clinical trial for a rare condition: COMS report no. 3. The Collaborative Ocular Melanoma Study Group. *Control Clin Trials*. 1993;14:362-391.
- Collaborative Ocular Melanoma Study Group. *COMS Manual of Procedures*. Springfield, VA: National Technical Information Service; 1989. NTIS Accession No. PB90-115536.
- McLean IW, Foster WD, Zimmerman LE. Prognostic factors in small malignant melanomas of choroid and ciliary body. *Arch Ophthalmol*. 1977;95:48-58.
- Affeldt JC, Minckler DS, Azen SP, Yeh L. Prognosis in uveal melanoma with extraocular extension. *Arch Ophthalmol*. 1980;98:1975-1979.
- Kujala E, Damato B, Coupland SE, et al. Staging of ciliary body and choroidal melanomas based on anatomic extent. *J Clin Oncol*. 2013;31:2825-2831.
- AJCC Ophthalmic Oncology Task Force. International validation of the American Joint Committee on Cancer's 7th edition classification of uveal melanoma. *JAMA Ophthalmol*. 2015;133:376-383.
- Folberg R, Verdick R, Weingeist TA, Montague PR. The gross examination of eyes removed for choroidal and ciliary body melanomas. *Ophthalmology*. 1986;93:1643-1647.
- Callender GR. Malignant melanotic tumors of the eye: a study of histologic types in 111 cases. *Trans Am Acad Ophthalmol Otolaryngol*. 1931;36:131-142.
- McLean IW, Zimmerman LE, Evans RM. Reappraisal of Callender's spindle A type of malignant melanoma of choroid and ciliary body. *Am J Ophthalmol*. 1978; 86:557-564.
- McLean IW, Foster WD, Zimmerman LE. Modifications of Callender's classification of uveal melanoma at the Armed Forces Institute of Pathology. *Am J Ophthalmol*. 1983;96:502-509.
- Amin MB, Edge SB, Greene FL, et al, eds. *AJCC Cancer Staging Manual*. 8th ed. New York, NY: Springer; 2017.
- Font RL, Spaulding AG, Zimmerman LE. Diffuse malignant melanoma of the uveal tract: a clinicopathologic report of 54 cases. *Trans Am Acad Ophthalmol Otolaryngol*. 1968;72:877-894.
- McLean IW, Foster WD, Zimmerman LE. Uveal melanoma: location, size, cell type, and enucleation as risk factors in metastasis. *Hum Pathol*. 1982;13:123-132.
- Weinhaus RS, Seddon JM, Albert DM, Gragoudas ES, Robinson N. Prognostic factor study of survival after enucleation for juxtapapillary melanomas. *Arch Ophthalmol*. 1985;103:1673-1677.
- Gamel JW, McCurdy JB, McLean IW. A comparison of prognostic covariates for uveal melanoma. *Invest Ophthalmol Vis Sci*. 1992;33:1919-1922.
- Folberg R, Peer J, Gruman LM, et al. The morphologic characteristics of tumor blood vessels as a marker of tumor progression in primary human uveal melanoma: a matched case-control study. *Hum Pathol*. 1992;23:1298-1305.

18. Coleman K, Baak JP, Van Diest P, Mullaney J, Farrell M, Fenton M. Prognostic factors following enucleation of 111 uveal melanomas. *Br J Ophthalmol*. 1993;77:688-692.
19. Folberg R, Rummelt V, Parys-Van Ginderdeuren R, et al. The prognostic value of tumor blood vessel morphology in primary uveal melanoma. *Ophthalmology*. 1993;100:1389-1398.
20. Folberg R, Rummelt V, Gruman LM, et al. Microcirculation architecture of melanocytic nevi and malignant melanomas of the ciliary body and choroid: a comparative histopathologic and ultrastructural study. *Ophthalmology*. 1994;101:718-727.
21. Rummelt V, Folberg R, Woolson RF, Hwang T, Peier J. Relation between the microcirculation architecture and the aggressive behavior of ciliary body melanomas. *Ophthalmology*. 1995;102:844-851.
22. Finger PT. Intraocular melanoma. In: DeVita Jr. VT, Lawrence TS, Rosenberg SA, eds. *DeVita, Hellman, and Rosenberg's Cancer: Principles & Practice of Oncology*. 10th ed. Riverwoods, IL: Wolters Kluwer Health; 2015.
23. Mäkitie T, Summanen P, Tarkkanen A, Kivelä T. Tumor-infiltrating macrophages (CD68(+) cells) and prognosis in malignant uveal melanoma. *Invest Ophthalmol Vis Sci*. 2001;42:1414-141.
24. Bronkhorst IH, Ly LV, Jordanova ES, Vrolijk J, Versluis M, Luyten GP, Jager MJ. Detection of M2-macrophages in uveal melanoma and relation with survival. *Invest Ophthalmol Vis Sci*. 2011;52:643-650.
25. Koopmans AE, Verdijk RM, Brouwer RW, et al. Clinical significance of immunohistochemistry for detection of BAP1 mutations in uveal melanoma. *Mod Pathol*. 2014;27:1321-1330.
26. Kalirai H, Dodson A, Faqir S, Damato BE, Coupland SE. Lack of BAP1 protein expression in uveal melanoma is associated with increased metastatic risk and has utility in routine prognostic testing. *Br J Cancer*. 2014;111:1373-1380.
27. van de Nes JA, Nelles J, Kreis S, et al. Comparing the prognostic value of *BAP1* mutation pattern, chromosome 3 status, and BAP1 immunohistochemistry in uveal melanoma. *Am J Surg Pathol*. 2016;40:796-805.