

# Protocol for the Examination of Specimens From Patients With Carcinoma of the Urinary Bladder

Protocol applies primarily to invasive carcinomas and/or associated  
epithelial lesions, including carcinoma in situ.

---

Based on AJCC/UICC TNM, 7<sup>th</sup> edition  
Protocol web posting date: October 2013

## Procedures

- Bladder Biopsy, Transurethral Resection of Bladder Tumor (TURBT) Specimen
- Cystectomy (Partial, Total)
  - Radical Cystoprostatectomy
  - Pelvic Exenteration

## Authors

Mahul B. Amin, MD, FCAP\*

Department of Pathology and Laboratory Medicine, Cedars-Sinai Medical Center, Los Angeles, California

Brett Delahunt, MD

Department of Pathology and Molecular Medicine, Wellington School of Medicine and Health Sciences,  
New Zealand

Bernard H. Bochner, MD

Department of Surgery, Urology Service, Memorial Sloan-Kettering Cancer Center, New York, New York

Jonathan I. Epstein, MD

The Johns Hopkins Hospital, Baltimore, Maryland

David J. Grignon, MD, FCAP

Department of Pathology, Indiana University School of Medicine, Indianapolis, Indiana

Peter A. Humphrey, MD, PhD, FCAP

Department of Pathology and Immunology, Washington University School of Medicine and Barnes-Jewish  
Hospital, St. Louis, Missouri

Rodolfo Montironi, MD

Institute of Pathological Anatomy and Histopathology, University of Ancona School of Medicine, Ancona,  
Italy

Gladell P. Paner, MD, FCAP

Department of Pathology and Laboratory Medicine, Loyola University Medical Center, Maywood, Illinois

Andrew A. Renshaw, MD, FCAP

Department of Pathology, Baptist Hospital of Miami, Miami, Florida

Victor E. Reuter, MD, FCAP

Department of Pathology, Memorial Sloan-Kettering Cancer Center, New York, New York

John R. Srigley, MD, FCAP

Department of Laboratory Medicine, Credit Valley Hospital, Mississauga, Ontario, Canada

Ming Zhou, MD, PhD, FCAP†

Department of Pathology, New York University Langone Medical Center, New York, New York

For the Members of the Cancer Committee, College of American Pathologists

\* Denotes primary author. † Denotes senior author. All other contributing authors are listed alphabetically.

**Previous lead contributor:** Donald Earl Henson, MD

© 2013 College of American Pathologists (CAP). All rights reserved.

The College does not permit reproduction of any substantial portion of these protocols without its written authorization. The College hereby authorizes use of these protocols by physicians and other health care providers in reporting on surgical specimens, in teaching, and in carrying out medical research for nonprofit purposes. This authorization does not extend to reproduction or other use of any substantial portion of these protocols for commercial purposes without the written consent of the College.

The CAP also authorizes physicians and other health care practitioners to make modified versions of the Protocols solely for their individual use in reporting on surgical specimens for individual patients, teaching, and carrying out medical research for non-profit purposes.

The CAP further authorizes the following uses by physicians and other health care practitioners, in reporting on surgical specimens for individual patients, in teaching, and in carrying out medical research for non-profit purposes: (1) **Dictation** from the original or modified protocols for the purposes of creating a text-based patient record on paper, or in a word processing document; (2) **Copying** from the original or modified protocols into a text-based patient record on paper, or in a word processing document; (3) The use of a **computerized system** for items (1) and (2), provided that the protocol data is stored intact as a single text-based document, and is not stored as multiple discrete data fields.

Other than uses (1), (2), and (3) above, the CAP does not authorize any use of the Protocols in electronic medical records systems, pathology informatics systems, cancer registry computer systems, computerized databases, mappings between coding works, or any computerized system without a written license from the CAP.

Any public dissemination of the original or modified protocols is prohibited without a written license from the CAP.

The College of American Pathologists offers these protocols to assist pathologists in providing clinically useful and relevant information when reporting results of surgical specimen examinations of surgical specimens. The College regards the reporting elements in the "Surgical Pathology Cancer Case Summary" portion of the protocols as essential elements of the pathology report. However, the manner in which these elements are reported is at the discretion of each specific pathologist, taking into account clinician preferences, institutional policies, and individual practice.

The College developed these protocols as an educational tool to assist pathologists in the useful reporting of relevant information. It did not issue the protocols for use in litigation, reimbursement, or other contexts. Nevertheless, the College recognizes that the protocols might be used by hospitals, attorneys, payers, and others. Indeed, effective January 1, 2004, the Commission on Cancer of the American College of Surgeons mandated the use of the required data elements of the protocols as part of its Cancer Program Standards for Approved Cancer Programs. Therefore, it becomes even more important for pathologists to familiarize themselves with these documents. At the same time, the College cautions that use of the protocols other than for their intended educational purpose may involve additional considerations that are beyond the scope of this document.

The inclusion of a product name or service in a CAP publication should not be construed as an endorsement of such product or service, nor is failure to include the name of a product or service to be construed as disapproval.

## CAP Urinary Bladder Protocol Revision History

---

### **Version Code**

The definition of the version code can be found at [www.cap.org/cancerprotocols](http://www.cap.org/cancerprotocols).

**Version:** UrinaryBladder 3.2.1.0

### **Summary of Changes**

The following changes have been made since the June 2012 release.

### **Biopsy and TURBT; Cystectomy, Partial, Total, or Radical; Anterior Exenteration**

### **Tumor Type**

A reporting element for tumor type was added, as follows:

### **Tumor Type**

- Invasive carcinoma
- Noninvasive carcinoma
- Carcinoma in situ

## Surgical Pathology Cancer Case Summary

---

Protocol web posting date: October 2013

### URINARY BLADDER: Biopsy and Transurethral Resection of Bladder Tumor (TURBT)

Note: Use of case summary for biopsy specimens is optional

Select a single response unless otherwise indicated.

#### Procedure (required only for TURBT) (Note A)

- Biopsy
- TURBT
- Other (specify): \_\_\_\_\_
- Not specified

#### Tumor Type

- Invasive carcinoma
- Noninvasive carcinoma
- Carcinoma in situ

#### Histologic Type (Note B)

- Urothelial (transitional cell) carcinoma
- Urothelial (transitional cell) carcinoma with squamous differentiation
- Urothelial (transitional cell) carcinoma with glandular differentiation
- Urothelial (transitional cell) carcinoma with variant histology (specify): \_\_\_\_\_
- Squamous cell carcinoma, typical
- Squamous cell carcinoma, variant histology (specify): \_\_\_\_\_
- Adenocarcinoma, typical
- Adenocarcinoma, variant histology (specify): \_\_\_\_\_
- Small cell carcinoma
- Undifferentiated carcinoma (specify): \_\_\_\_\_
- Mixed cell type (specify): \_\_\_\_\_
- Other (specify): \_\_\_\_\_
- Carcinoma, type cannot be determined

#### Associated Epithelial Lesions (select all that apply) (Note C)

- None identified
- Urothelial (transitional cell) papilloma (World Health Organization [WHO] 2004/ International Society of Urologic Pathology [ISUP])
- Urothelial (transitional cell) papilloma, inverted type
- Papillary urothelial (transitional cell) neoplasm, low malignant potential (WHO 2004/ISUP)
- Cannot be determined

#### Histologic Grade (select all that apply) (Note C)

- Not applicable
- Cannot be determined
- Urothelial carcinoma
  - Low-grade
  - High-grade
  - Other (specify): \_\_\_\_\_

+ Data elements preceded by this symbol are not required. However, these elements may be clinically important but are not yet validated or regularly used in patient management.

- Squamous cell carcinoma or adenocarcinoma
- GX: Cannot be assessed
  - G1: Well differentiated
  - G2: Moderately differentiated
  - G3: Poorly differentiated
  - Other (specify): \_\_\_\_\_
- Other carcinoma
- Low-grade
  - High-grade
  - Other (specify): \_\_\_\_\_

**+ Tumor Configuration (select all that apply)**

- +  Papillary
- +  Solid/nodule
- +  Flat
- +  Ulcerated
- +  Indeterminate
- +  Other (specify): \_\_\_\_\_

**Adequacy of Material for Determining Muscularis Propria Invasion (Note D)**

- Muscularis propria (detrusor muscle) not identified
- Muscularis propria (detrusor muscle) present
- Presence of muscularis propria indeterminate

**Lymph-Vascular Invasion (Note E)**

- Not identified
- Present
- Indeterminate

**Microscopic Tumor Extension (select all that apply) (Note F)**

- Cannot be assessed
- Noninvasive papillary carcinoma
- Flat carcinoma in situ
- Tumor invades subepithelial connective tissue (lamina propria)
- Tumor invades muscularis propria (detrusor muscle)
- Urothelial carcinoma involving prostatic urethra in prostatic chips sampled by TURBT
- Urothelial carcinoma involving prostatic ducts and acini in prostatic chips sampled by TURBT
- Urothelial carcinoma invasive into prostatic stroma in prostatic chips sampled by TURBT

**+ Additional Pathologic Findings (select all that apply)**

- +  Urothelial dysplasia (low-grade intraurothelial neoplasia)
- +  Inflammation/regenerative changes
- +  Therapy-related changes
- +  Cautery artifact
- +  Cystitis cystica et glandularis
- +  Keratinizing squamous metaplasia
- +  Intestinal metaplasia
- +  Other (specify): \_\_\_\_\_

**+ Comment(s)**

## Surgical Pathology Cancer Case Summary

---

Protocol web posting date: October 2013

### URINARY BLADDER: Cystectomy, Partial, Total, or Radical; Anterior Exenteration

Select a single response unless otherwise indicated.

#### Specimen

- Bladder
- Other (specify): \_\_\_\_\_
- Not specified

#### Procedure (Note G)

- Partial cystectomy
- Total cystectomy
- Radical cystectomy
- Radical cystoprostatectomy
- Anterior exenteration
- Other (specify): \_\_\_\_\_
- Not specified

#### + Tumor Site (select all that apply)

- +  Trigone
- +  Right lateral wall
- +  Left lateral wall
- +  Anterior wall
- +  Posterior wall
- +  Dome
- +  Other (specify): \_\_\_\_\_
- +  Not specified

#### Tumor Size

- Greatest dimension: \_\_\_ cm
- + Additional dimensions: \_\_x\_\_ cm
- Cannot be determined (see Comment)

#### Tumor Type

- Invasive carcinoma
- Noninvasive carcinoma
- Carcinoma in situ

**Histologic Type (Note B)**

- Urothelial (transitional cell) carcinoma
- Urothelial (transitional cell) carcinoma with squamous differentiation
- Urothelial (transitional cell) carcinoma with glandular differentiation
- Urothelial (transitional cell) carcinoma with variant histology (specify): \_\_\_\_\_
- Squamous cell carcinoma, typical
- Squamous cell carcinoma, variant histology (specify): \_\_\_\_\_
- Adenocarcinoma, typical
- Adenocarcinoma, variant histology (specify): \_\_\_\_\_
- Small cell carcinoma
- Undifferentiated carcinoma (specify): \_\_\_\_\_
- Mixed cell type (specify): \_\_\_\_\_
- Other (specify): \_\_\_\_\_
- Carcinoma, type cannot be determined

**Associated Epithelial Lesions (select all that apply) (Note C)**

- None identified
- Urothelial (transitional cell) papilloma (World Health Organization [WHO] 2004/ International Society of Urologic Pathology [ISUP])
- Urothelial (transitional cell) papilloma, inverted type
- Papillary urothelial (transitional cell) neoplasm, low malignant potential (WHO 2004/ISUP)
- Cannot be determined

**Histologic Grade (select all that apply) (Note C)**

- Not applicable
- Cannot be determined
- Urothelial carcinoma
  - Low-grade
  - High-grade
  - Other (specify): \_\_\_\_\_
- Squamous cell carcinoma or adenocarcinoma
  - GX: Cannot be assessed
  - G1: Well differentiated
  - G2: Moderately differentiated
  - G3: Poorly differentiated
  - Other (specify): \_\_\_\_\_
- Other carcinoma
  - Low-grade
  - High-grade
  - Other (specify): \_\_\_\_\_

**+ Tumor Configuration (select all that apply)**

- +  Papillary
- +  Solid/nodule
- +  Flat
- +  Ulcerated
- +  Indeterminate
- +  Other (specify): \_\_\_\_\_

**Microscopic Tumor Extension (select all that apply) (Note D)**

- Cannot be assessed
- No evidence of primary tumor
- Noninvasive papillary carcinoma
- Carcinoma in situ: "flat tumor"
- Tumor invades lamina propria
- Tumor invades muscularis propria
  - Tumor invades superficial muscularis propria (inner half)
  - Tumor invades deep muscularis propria (outer half)
- Tumor invades perivesical tissue
  - Microscopically
  - Macroscopically (extravesical mass)
- Tumor invades adjacent structures
  - Prostatic stroma
  - Seminal vesicles
  - Uterus
  - Vagina
  - Adnexae
  - Pelvis wall
  - Abdominal wall
  - Rectum
  - Other (specify): \_\_\_\_\_

**Margins (select all that apply) (Note G)**

- Cannot be assessed
- Margin(s) involved by invasive carcinoma
  - Ureteral margin
  - Distal urethral margin
  - Deep soft tissue margin
  - Other margin(s) (specify)#: \_\_\_\_\_
- Margins(s) involved by carcinoma in situ/noninvasive high-grade urothelial carcinoma
  - Ureteral margin
  - Distal urethral margin
  - Other margin(s) (specify)#: \_\_\_\_\_
- Margins uninvolved by invasive carcinoma/carcinoma in situ/noninvasive high-grade urothelial carcinoma
  - + Distance of carcinoma from closest margin: \_\_\_ mm
  - + Specify margin#: \_\_\_\_\_
  - + Other significant changes at margin (specify margin)#: \_\_\_\_\_
    - +  Low-grade dysplasia
    - +  Non-invasive low-grade urothelial carcinoma

# For partial cystectomies, if the specimen is received unoriented precluding identification of specific margins, it should be denoted here.

**Lymph-Vascular Invasion (Note E)**

- Not identified
- Present
- Indeterminate

+ Data elements preceded by this symbol are not required. However, these elements may be clinically important but are not yet validated or regularly used in patient management.



**Pathologic Staging (pTNM) (Note F)**TNM Descriptors (required only if applicable) (select all that apply)

- m (multiple primary tumors)  
 r (recurrent)  
 y (posttreatment)

Primary Tumor (pT)

- pTX: Primary tumor cannot be assessed  
 pT0: No evidence of primary tumor  
 pTa: Noninvasive papillary carcinoma  
 pTis: Carcinoma in situ: "flat tumor"  
 pT1: Tumor invades subepithelial connective tissue (lamina propria)  
 pT2: Tumor invades muscularis propria (detrusor muscle)  
 pT2a: Tumor invades superficial muscularis propria (inner half)  
 pT2b: Tumor invades deep muscularis propria (outer half)  
 pT3: Tumor invades perivesical tissue  
 pT3a: Microscopically  
 pT3b: Macroscopically (extravesicular mass)  
 pT4: Tumor invades any of the following: prostatic stroma, seminal vesicles, uterus, vagina, pelvic wall, abdominal wall  
 pT4a: Tumor invades prostatic stroma or uterus or vagina  
 pT4b: Tumor invades pelvic wall or abdominal wall

Regional Lymph Nodes (pN)

- pNX: Lymph nodes cannot be assessed  
 pN0: No lymph node metastasis  
 pN1: Single regional lymph node metastasis in the true pelvis (hypogastric, obturator, external iliac or presacral lymph node)  
 pN2: Multiple regional lymph node metastasis in the true pelvis (hypogastric, obturator, external iliac or presacral lymph node metastasis)  
 pN3: Lymph node metastasis to the common iliac lymph nodes  
  
 No nodes submitted or found

*Number of Lymph Nodes Examined*

- Specify: \_\_\_\_\_  
 Number cannot be determined (explain): \_\_\_\_\_

*Number of Lymph Nodes Involved (any size)*

- Specify: \_\_\_\_\_  
 Number cannot be determined (explain): \_\_\_\_\_

Distant Metastasis (pM)

- Not applicable  
 pM1: Distant metastasis  
     + Specify site(s), if known: \_\_\_\_\_

**+ Additional Pathologic Findings (select all that apply)**

- +  Adenocarcinoma of prostate (use protocol for carcinoma of prostate)
- +  Urothelial (transitional cell) carcinoma involving urethra, prostatic ducts and acini with or without stromal invasion (use protocol for carcinoma of urethra)
- +  Urothelial dysplasia (low-grade intraurothelial neoplasia)
- +  Inflammation/regenerative changes
- +  Therapy-related changes
- +  Cystitis cystica et glandularis
- +  Keratinizing squamous metaplasia
- +  Intestinal metaplasia
- +  Other (specify): \_\_\_\_\_

**+ Comment(s)**

## Explanatory Notes

---

### A. History

A relevant history is important for interpretation of all bladder specimens.<sup>1-4</sup> Cystoscopic visualization findings hold useful information on the nature and extent of bladder lesions in biopsy and TURBT specimens. A history of renal stones, recent urinary tract procedures, infections, or obstruction may influence the interpretation of random biopsies obtained on patients with hematuria. Any neoplasms previously diagnosed should be specified, including the histologic type, primary site, and histologic grade. If prior therapy has been given, it should be described (systemic or intravesical chemotherapy, immunotherapy, radiation, etc). The method of collection and date also should be specified in urine cytology specimens.

### B. Histologic Type

The vast majority (more than 95%) of carcinomas of the urinary bladder, renal pelvis, and ureter are urothelial or transitional cell in origin. A working histologic classification encompassing the wide histologic diversity and histologic range within the different types of carcinomas of the urothelial tract is tabulated in this note. Benign tumors are included in this classification because, within the same patient, a spectrum of differentiation from benign to malignant tumors may be seen in the bladder, either at the same time or over the clinical course of the disease. Also, clinicians stage most tumors irrespective of histologic grade.<sup>5-12</sup> The distinction between a urothelial carcinoma with aberrant squamous or glandular differentiation and a primary squamous cell carcinoma or adenocarcinoma is rather arbitrary. Most authorities require a pure histology of squamous cell carcinoma or adenocarcinoma to designate a tumor as such, all others with recognizable papillary, invasive, or flat carcinoma in situ (CIS) urothelial component being considered as urothelial carcinoma with aberrant differentiation.

### Classification of Neoplasms of the Urinary Bladder, Including Urothelial (Transitional Cell) Carcinoma and Its Variants#

#### Urothelial (Transitional Cell) Neoplasia

##### Benign

Urothelial papilloma (World Health Organization [WHO] 2004/ International Society of Urologic Pathology [ISUP]), WHO, 1973, grade 0)

##### Inverted papilloma

Papillary urothelial neoplasm of low malignant potential (WHO 2004/ISUP); WHO, 1973, grade I)

##### Malignant

##### Papillary##

Typical, noninvasive

Typical, with invasion

##### Variant

With squamous or glandular differentiation

##### Micropapillary

##### Nonpapillary

Carcinoma in situ

Invasive carcinoma

Variants containing or exhibiting

Deceptively benign features

Nested pattern (resembling von Brunn's nests)

Small tubular pattern

Microcystic pattern

Inverted pattern

Squamous differentiation

Glandular differentiation

- Micropapillary histology
- Sarcomatoid foci ("sarcomatoid carcinoma")
- Urothelial carcinoma with unusual cytoplasmic features
  - Clear cell (glycogen rich)
  - Plasmacytoid
  - Rhabdoid
  - Lipoid rich
- Urothelial carcinoma with syncytiotrophoblasts
- Unusual stromal reactions
  - Pseudosarcomatous stroma
  - Stromal osseous or cartilaginous metaplasia
  - Osteoclast-type giant cells
  - With prominent lymphoid infiltrate

## Squamous Cell Carcinoma

- Typical
- Variant
  - Verrucous carcinoma
  - Basaloid squamous cell carcinoma
  - Sarcomatoid carcinoma

## Adenocarcinoma

- Anatomic variants
  - Bladder mucosa
  - Urachal
  - With exstrophy
  - From endometriosis
- Histologic variants
  - Typical intestinal type
  - Mucinous (including colloid)
  - Signet-ring cell
  - Clear cell
  - Hepatoid
  - Mixture of above patterns – adenocarcinoma not otherwise specified (NOS)

## Tumors of Mixed Cell Types

## Undifferentiated Carcinoma###

- Small cell carcinoma
- Large cell neuroendocrine carcinoma
- Lymphoepithelioma-like carcinoma
- Osteoclast-rich carcinoma
- Giant cell carcinoma
- Not otherwise specified

## Metastatic Carcinoma

# Modified from Amin et al.<sup>5</sup>

## Papillary tumors may be invasive or noninvasive, and when invasive may be microinvasive (invasive to a depth of 2 mm or less) or frankly invasive (like nonpapillary tumors).

### Refers to tumors that are undifferentiated by light microscopy.

**C. Histologic Grade**

Flat intraepithelial lesions and papillary and invasive lesions are graded separately.<sup>10-16</sup> There has been significant controversy in the classification of these lesions. Flat lesions were graded as mild, moderate,

and severe dysplasia and carcinoma in situ; or atypical hyperplasia and carcinoma in situ; or dysplasia and carcinoma in situ.<sup>5,7</sup> Papillary lesions were classified as papillomas (grade 0) and transitional cell carcinomas, grades I, II and III; or as papillomas, low-grade and high-grade transitional cell carcinomas.<sup>12-14</sup> Due to variable classification systems and the need for a universally acceptable system, the World Health Organization/International Society of Urological Pathology (WHO/ISUP) consensus classification was proposed.<sup>12</sup> This system is adopted in the WHO 2004 "blue book"<sup>10</sup> and 2004 AFIP fascicle.<sup>11</sup> Other systems (that were being used previously) may still be used according to institutional preference. Until the WHO/ISUP system is clinically and prognostically validated, tumor grade according to both the WHO/ISUP (1998)<sup>12</sup> / WHO (2004)<sup>10</sup> system and the older WHO (1973)<sup>14</sup> system, eg, papillary urothelial neoplasm of low malignant potential (WHO/ISUP, 1998)/transitional cell carcinoma, grade I (WHO, 1973), may be concurrently used.

The WHO (1999) classification of bladder tumors<sup>9</sup> differs only slightly from the WHO/ISUP (1998)<sup>12</sup> and WHO (2004)<sup>10</sup> system<sup>12</sup> in that carcinomas are graded on a I to III scale in the former and low-grade and high-grade in the latter. Most cases designated as grade II and III by the WHO (1999) system correspond to high-grade carcinomas in the WHO/ISUP (1998) and WHO (2004) Consensus Classification.

### World Health Organization (WHO) 2004/ International Society of Urologic Pathology (ISUP) Consensus Classification for Urothelial (Transitional Cell) Lesions

Normal

Normal#

Hyperplasia

Flat hyperplasia

Papillary hyperplasia

Flat Lesions with Atypia

Reactive (inflammatory) atypia

Atypia of unknown significance

Dysplasia (low-grade intraurothelial neoplasia)#

Carcinoma in situ (high-grade intraurothelial neoplasia)##

Papillary Neoplasms

Papilloma

Inverted papilloma

Papillary neoplasm of low malignant potential

Papillary carcinoma, low-grade

Papillary carcinoma, high-grade###

Invasive Neoplasms

Lamina propria invasion

Muscularis propria (detrusor muscle) invasion

# May include cases formerly diagnosed as "mild dysplasia."

## Includes cases with "severe dysplasia."

### Option exists to add comment as to the presence of marked anaplasia.

Squamous carcinomas and adenocarcinomas may be graded as well differentiated, moderately differentiated, and poorly differentiated.

#### D. Extent of Invasion

A critical role of the surgical pathologist is to diagnose the depth and extent of invasion into the subepithelial connective tissue/lamina propria/submucosa (pT1), muscularis propria (pT2), or beyond (pT3 or pT4).<sup>17-19</sup> In papillary tumors, invasion occurs most often at the base of the tumor and very

infrequently in the stalk. In the urinary bladder, a tumor infiltrating the lamina propria (pT1) is sometimes overdiagnosed as vascular invasion; hence, caution should be exercised when diagnosing this feature, which in some cases may be supported by performing immunohistochemical studies for endothelial markers.<sup>20</sup> Although attempts at substaging bladder pT1 tumors have been made, the WHO/ISUP committee recommended that it is currently not necessary for the practice to be universally adopted.<sup>10,12</sup> Pathologists are, however, encouraged to provide some assessment as to the extent of lamina propria invasion (ie, focal versus extensive, or depth in millimeters, or by level – above, at, or below muscularis mucosae). Designation of a tumor as merely muscle invasive is inappropriate, but the type of muscle invasion, ie, muscularis mucosae (pT1 tumors) versus muscularis propria (pT2 tumors) invasion, needs to be clearly stated.<sup>21,22</sup> Descriptive terminology, such as “urothelial carcinoma with muscle invasion, indeterminate for type of muscle invasion,” may be used when it is not possible to be certain whether the type of muscle invaded by the tumor is hypertrophic muscularis mucosae or muscularis propria. A comment on thermocoagulation effect may be made, especially if its presence impedes diagnostic evaluation.<sup>23</sup> In TURBT specimens invasive into muscularis propria, no attempt should be made to substage the depth of muscularis propria invasion. Since fat may be present in the lamina propria and muscularis propria, the presence of tumor in adipose tissue is not necessarily diagnostic of extravesical spread; this determination is reserved for cystectomy specimens.<sup>22,24</sup>

Involvement of the prostate gland may occur in several different patterns. The prostatic urethra may be involved (flat carcinoma in situ, papillary or invasive carcinoma), or the prostate gland may be involved. Involvement of the prostate gland may be evident as involvement of prostatic ducts and acini without stromal invasion (carcinoma in situ involving prostate glands) or as urothelial carcinoma involving prostatic stroma (either from prostatic urethral carcinoma, carcinoma extending directly through the bladder wall, or carcinoma involving prostatic ducts and acini additionally with stromal invasion).<sup>25</sup>

### E. Lymph-Vascular Invasion

Urothelial carcinoma may invade blood vessels or lymphatic channels. Lymphovascular invasion has been shown to be an independent predictor of recurrence and decreased overall survival.<sup>26</sup> Presence of lymph-vascular invasion in TURBT specimens is associated with higher nodal metastasis.<sup>27</sup> In suspicious cases, blood vessels can be highlighted by immunohistochemical staining for factor VIII-related antigen, CD31 or CD34. Staining will not resolve the problem of differentiating lymphatic versus artifactual space entrapment by tumor cells, and as mentioned, this is frequently seen in urothelial tumors invading the lamina propria. Retraction artifact is also prominent in the “micropapillary variant” of urothelial carcinoma.<sup>7</sup>

### F. TNM and Stage Groupings

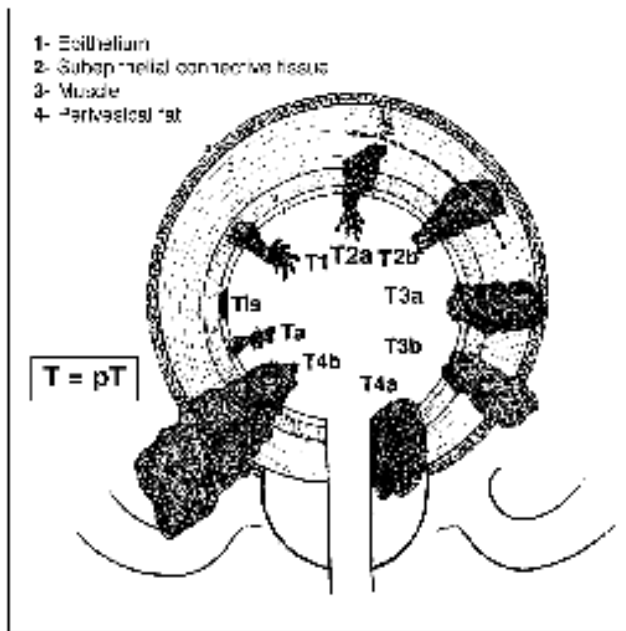
The TNM Staging System for carcinomas of the urinary bladder of the American Joint Committee on Cancer (AJCC) and the International Union Against Cancer (UICC) is recommended.<sup>17,18</sup> A cystoprostatectomy specimen may contain 3 separate primaries: carcinoma of the urinary bladder, carcinoma of the prostate and carcinoma of the urethra. Depending on the pathology in a given case, the number of protocols to be used in a cystoprostatectomy specimen will vary.

By AJCC/UICC convention, the designation “T” refers to a primary tumor that has not been previously treated. The symbol “p” refers to the pathologic classification of the TNM, as opposed to the clinical classification, and is based on gross and microscopic examination. pT entails a resection of the primary tumor or biopsy adequate to evaluate the highest pT category, pN entails removal of nodes adequate to validate lymph node metastasis, and pM implies microscopic examination of distant lesions. Clinical classification (cTNM) is usually carried out by the referring physician before treatment during initial evaluation of the patient or when pathologic classification is not possible.

Pathologic staging is usually performed after surgical resection of the primary tumor. Pathologic staging depends on pathologic documentation of the anatomic extent of disease, whether or not the primary tumor has been completely removed. If a biopsied tumor is not resected for any reason (eg, when technically unfeasible) and if the highest T and N categories or the M1 category of the tumor can be confirmed microscopically, the criteria for pathologic classification and staging have been satisfied without total removal of the primary cancer.

**Primary Tumor (T)** (Figure 1)

The suffix “m” should be added to the appropriate T category to indicate multiple tumors. The suffix “is” may be added to any T to indicate the presence of associated carcinoma in situ.



**Figure 1.** Schematic depiction of pathologic stage (TNM, 1997; TNM, 2002; and TNM, 2009) for carcinomas of the urinary bladder. From: Hermanek P, Hutter RVP, Sobin LH, Wagner G, Wittekind C, eds. *UICC TNM Atlas: Illustrated Guide to the TNM/pTNM Classification of Malignant Tumors*. 4<sup>th</sup> ed. Berlin-Heidelberg, Germany: Springer-Verlag; 1997. Reproduced with permission.

**TNM Stage Groupings**

Stage 0a	Ta	N0	M0 <sup>#</sup>
Stage 0is	Tis	N0	M0
Stage I	T1	N0	M0
Stage II	T2a	N0	M0
	T2b	N0	M0
Stage III	T3a	N0	M0
	T3b	N0	M0
	T4a	N0	M0
Stage IV	T4b	N0	M0
	Any T	N1,2,3	M0
	Any T	Any N	M1

<sup>#</sup> M0 is defined as no distant metastasis.

### TNM Descriptors

For identification of special cases of TNM or pTNM classifications, the “m” suffix and “y” and “r” prefixes are used. Although they do not affect the stage grouping, they indicate cases needing separate analysis.

The “m” suffix indicates the presence of multiple primary tumors in a single site and is recorded in parentheses: pT(m)NM.

The “y” prefix indicates those cases in which classification is performed during or following initial multimodality therapy (ie, neoadjuvant chemotherapy, radiation therapy, or both chemotherapy and radiation therapy). The cTNM or pTNM category is identified by a “y” prefix. The ycTNM or ypTNM categorizes the extent of tumor actually present at the time of that examination. The “y” categorization is not an estimate of tumor prior to multimodality therapy (ie, before initiation of neoadjuvant therapy).

The “r” prefix indicates a recurrent tumor when staged after a documented disease-free interval, and is identified by the “r” prefix: rTNM.

### Additional Descriptors

#### Residual Tumor (R)

Tumor remaining in a patient after therapy with curative intent (eg, surgical resection for cure) is categorized by a system known as R classification, shown below.

RX	Presence of residual tumor cannot be assessed
R0	No residual tumor
R1	Microscopic residual tumor
R2	Macroscopic residual tumor

For the surgeon, the R classification may be useful to indicate the known or assumed status of the completeness of a surgical excision. For the pathologist, the R classification is relevant to the status of the margins of a surgical resection specimen. That is, tumor involving the resection margin on pathologic examination may be assumed to correspond to residual tumor in the patient and may be classified as macroscopic or microscopic according to the findings at the specimen margin(s).

## G. Sections for Microscopic Evaluation

### Bladder

Sections of bladder for microscopic evaluation are as follows. In TURBT specimens, submit 1 section per centimeter of tumor diameter (up to 10 cassettes). If the tumor is noninvasive by the initial sampling, additional submission of tissue (including possibly submitting all tissue) is necessary to diagnose or rule out the presence of invasion. If tumor is invasive into lamina propria in the initial sampling, additional sections (including possibly submitting the entire specimen) may be necessary to diagnose or rule out the possibility of muscularis propria invasion. In cystectomy specimens, several representative sections of the tumor, including the macroscopically deepest penetration, should be sampled. Submit several sections of the mucosa remote from the carcinoma, especially if abnormal, including the lateral wall(s), dome, and trigone. Submit 1 section of ureteral margin, unless submitted separately as frozen section specimens, and 1 section of urethral margin. If a long segment of the ureter(s) is present, then additional sections from the mid-portion may be necessary, as urothelial cancer often is multifocal.



### Prostate and Prostatic Urethra

Prostatic urethral involvement should be carefully investigated in cystectomy specimens. Sections should include the prostatic urethra, including at the margin and with the surrounding prostatic parenchyma. Representative sections of the peripheral zone, central zone, and seminal vesicles should be included. Close gross examination may help target sampling of selective abnormal-appearing areas.

### Lymph Nodes

Submit 1 section from each grossly positive lymph node. All other lymph nodes should be entirely submitted, as presence of nodal disease may be used as an indication for adjuvant therapy. Lymph nodes may be grossly or microscopically detected in the perivesical fat.

### Other Tissues

Submit 1 or more sections of uterus (as indicated) and 1 or more sections of vagina, seminal vesicles, and other organs (as indicated). If the tumor grossly appears to invade the prostate, uterus, or vagina, sections should be targeted, such that the relationship of the infiltrating tumor in the bladder wall and the adjacent viscus is clearly demonstrable.

### H. Margins

Resection margins, including those mentioned in Note G, should be carefully specified. Statements about deep soft tissue margins should specify whether peritoneal surfaces are involved by tumor. In cases of urachal adenocarcinoma in which partial cystectomy with excision of the urachal tract and umbilicus is performed, the margins of the urachal tract, ie, the soft tissue surrounding the urachus and the skin around the umbilical margin, should be specified. In renal pelvis, ureter, and nephroureterectomy specimens, the margins may include radial hilar soft tissue margin; bladder cuff; and ureteral, renal parenchymal, and Gerota's fascia margins, depending on the type of surgical specimen.

### References

1. Murphy WM. Diseases of the urinary bladder, urethra, ureters and renal pelvis. In: Murphy WM, ed. *Urological Pathology*. 2<sup>nd</sup> ed. Philadelphia, PA: WB Saunders Co; 1997.
2. Ro JY, Staerckel GA, Ayala AG. Cytologic and histologic features of superficial bladder cancer. *Urol Clin North Am*. 1992;19:435-453.
3. Grignon DJ. Neoplasms of the urinary bladder. In: Bostwick DG, Eble JN, eds. *Urologic Surgical Pathology*. St. Louis, MO: Mosby Year Book, Inc; 1997.
4. Hughes JH, Raab SS, Cohen MB. The cytologic diagnosis of low-grade transitional cell carcinoma. *Am J Clin Pathol*. 2000;114(suppl1):559-567.
5. Amin MB, Murphy WM, Reuter VE, et al. Controversies in the pathology of transitional cell carcinoma of the urinary bladder. Part I, Chapter 1. In: Rosen PP, Fechner RE, eds. *Reviews of Pathology*. Vol. 1. Chicago, IL: ASCP Press; 1996.
6. Reuter VE. The urothelial tract: renal pelvis, ureter, urinary bladder, and urethra. In: Mills Se, Carter D, Greenson JK, Oberman HA, Reuter V, Stoler MH, eds. *Sternberg's Diagnostic Surgical Pathology*. 4<sup>th</sup> ed. Philadelphia, PA: Lippincott Williams and Wilkins; 2004.
7. Amin MB, Young RH. Intraepithelial lesions of the urinary bladder with a discussion of the histogenesis of urothelial neoplasia. *Semin Diagn Pathol*. 1997;14(2):84-97.
8. Eble JN, Young RH. Carcinoma of the urinary bladder: a review of its diverse morphology. *Semin Diagn Pathol*. 1997;14(2):98-108.
9. Mostofi FK, Davis CJ, Sesterhenn IA. Histologic typing of urinary bladder tumors. In: *World Health Organization International Histologic Classification of Tumours*. 2<sup>nd</sup> ed. Heidelberg, Germany: Springer-Verlag, Berlin; 1999.

10. Eble JN, Sauter G, Epstein JI, Sesterhenn IA. Tumors of the urinary system. In: *World Health Organization Classification of Tumours: Pathology and Genetics of Tumours of the Urinary System and Male Genital Organs*. Lyon, France: IARC Press; 2004.
11. Murphy WM, Grignon DJ, Perlman EJ. Tumors of the urinary bladder. In: *Tumors of the Kidney, Bladder, and Related Urinary Structures. AFIP Atlas of Tumor Pathology Series 4*. Washington, DC: American Registry of Pathology; 2004.
12. Epstein JI, Amin MB, Reuter VR, Mostofi FK, the Bladder Consensus Conference Committee. The World Health Organization/ International Society of Urological Pathology Consensus classification of urothelial (transitional cell) neoplasms of the urinary bladder. *Am J Surg Pathol*. 1998;22:1435-1448.
13. Murphy WM, Beckwith JB, Farrow GM. Tumors of the kidney, bladder, and related urinary structures. In: *Atlas of Tumor Pathology*. 3<sup>rd</sup> series. Fascicle 11. Washington, DC: Armed Forces Institute of Pathology; 1994.
14. Mostofi FK. Histological typing of urinary bladder tumours. In: *WHO Histological Classification of Tumours. No. 10*. Geneva, Switzerland: World Health Organization; 1973.
15. Bergkvist A, Ljungqvist A, Moberger G. Classification of bladder tumors based on the cellular pattern. *Acta Chir Scand*. 1965;130:371-378.
16. Friedell GH, Bell JR, Burney SW, Soto EA, Tiltman AJ. Histopathology and classification of urinary bladder carcinoma. *Urol Clin North Am*. 1976;3:265-227.
17. Edge SB, Byrd DR, Carducci MA, Compton CC, eds. *AJCC Cancer Staging Manual*. 7th ed. New York, NY: Springer; 2009.
18. Sobin LH, Gospodarowicz M, Wittekind Ch, eds. *UICC TNM Classification of Malignant Tumours*. 7th ed. New York, NY: Wiley-Liss; in press.
19. Jimenez RE, Keane TE, Hardy HT, Amin MB. pT1 urothelial carcinoma of the bladder: criteria for diagnosis, pitfalls, and clinical implications. *Adv Anat Pathol*. 2000;7(1):13-25.
20. Amin MB, Murphy WM, Reuter VE, et al. Controversies in the pathology of transitional cell carcinoma of the urinary bladder. Part II, Chapter 5. In: Rosen PP, Fechner RE, eds. *Reviews of Pathology*. Vol. 2. Chicago, IL: ASCP Press; 1997: 71-110.
21. Ro JY, Ayala AG, El-Naggar A. Muscularis mucosa of urinary bladder: importance for staging and treatment. *Am J Surg Pathol*. 1983;136:265-271.
22. Paner GP, Ro JY, Wojcik EM, Venkataraman G, Data MW, Amin MB. Further characterization of the muscle layers and lamina propria of the urinary bladder by systematic histologic mapping: implications for pathologic staging of invasive urothelial carcinoma. *Am J Surg Pathol*. 2007;31:1420-1429.
23. Murphy WM. ASCP survey on pathology examination of the urinary bladder. *Am J Clin Pathol*. 1994;102:715-723.
24. Philip AT, Amin MB, Tamboli P, Lee TJ, Hill CE, Ro JY. Intravesical adipose tissue: a quantitative study of its presence and location with implications for therapy and prognosis. *Am J Surg Pathol*. 2000;24:1286-1290.
25. Mahadevia PS, Koss LG, Tar IJ. Prostatic involvement in bladder cancer. *Cancer*. 1986;58:2096-2102.
26. Lotan Y, Gupta A, Shariat SF, et al. Lymphovascular invasion is independently associated with overall survival, cause-specific survival, and local and distant recurrence in patients with negative lymph nodes at radical cystectomy. *J Clin Oncol*. 2005;23:6533-6539.
27. Kunju LP, You L, Zhang Y, Daignault S, Montie JE, Lee CT. Lymphovascular invasion of urothelial cancer in matched transurethral bladder tumor resection and radical cystectomy specimens. *J Urol*. 2008;18:1928-1932.