



Protocol for the Examination of Specimens From Patients With Retinoblastoma

Protocol applies to retinoblastoma only.

Based on AJCC/UICC TNM, 7th edition

Protocol web posting date: January 2016

Procedure

- Enucleation, Partial or Complete Exenteration

Authors

Hans E. Grossniklaus MD, MBA*

Departments of Ophthalmology and Pathology, Emory University School of Medicine, Atlanta, Georgia

Paul T. Finger, MD

Department of Ophthalmology, The New York Eye Cancer Center, New York, New York

J. William Harbour, MD

Department of Ophthalmology, Washington University School of Medicine, St. Louis, Missouri

Tero Kivëla, MD

Departments of Ophthalmology and Pathology, University of Helsinki, Finland

For the Members of the Cancer Committee, College of American Pathologists

* Denotes primary author. All other contributing authors are listed alphabetically.

Previous lead contributors: David L. Page, MD; Harry H. Brown, MD.

© 2016 College of American Pathologists (CAP). All rights reserved.

The College does not permit reproduction of any substantial portion of these protocols without its written authorization. The College hereby authorizes use of these protocols by physicians and other health care providers in reporting on surgical specimens, in teaching, and in carrying out medical research for nonprofit purposes. This authorization does not extend to reproduction or other use of any substantial portion of these protocols for commercial purposes without the written consent of the College.

The CAP also authorizes physicians and other health care practitioners to make modified versions of the Protocols solely for their individual use in reporting on surgical specimens for individual patients, teaching, and carrying out medical research for non-profit purposes.

The CAP further authorizes the following uses by physicians and other health care practitioners, in reporting on surgical specimens for individual patients, in teaching, and in carrying out medical research for non-profit purposes: (1) **Dictation** from the original or modified protocols for the purposes of creating a text-based patient record on paper, or in a word processing document; (2) **Copying** from the original or modified protocols into a text-based patient record on paper, or in a word processing document; (3) The use of a **computerized system** for items (1) and (2), provided that the protocol data is stored intact as a single text-based document, and is not stored as multiple discrete data fields.

Other than uses (1), (2), and (3) above, the CAP does not authorize any use of the Protocols in electronic medical records systems, pathology informatics systems, cancer registry computer systems, computerized databases, mappings between coding works, or any computerized system without a written license from the CAP.

Any public dissemination of the original or modified protocols is prohibited without a written license from the CAP.

The College of American Pathologists offers these protocols to assist pathologists in providing clinically useful and relevant information when reporting results of surgical specimen examinations of surgical specimens. The College regards the reporting elements in the “Surgical Pathology Cancer Case Summary” portion of the protocols as essential elements of the pathology report. However, the manner in which these elements are reported is at the discretion of each specific pathologist, taking into account clinician preferences, institutional policies, and individual practice.

The College developed these protocols as an educational tool to assist pathologists in the useful reporting of relevant information. It did not issue the protocols for use in litigation, reimbursement, or other contexts. Nevertheless, the College recognizes that the protocols might be used by hospitals, attorneys, payers, and others. Indeed, effective January 1, 2004, the Commission on Cancer of the American College of Surgeons mandated the use of the required data elements of the protocols as part of its Cancer Program Standards for Approved Cancer Programs. Therefore, it becomes even more important for pathologists to familiarize themselves with these documents. At the same time, the College cautions that use of the protocols other than for their intended educational purpose may involve additional considerations that are beyond the scope of this document.

The inclusion of a product name or service in a CAP publication should not be construed as an endorsement of such product or service, nor is failure to include the name of a product or service to be construed as disapproval.

CAP Retinoblastoma Protocol Revision History

Version Code

The definition of the version code can be found at www.cap.org/cancerprotocols.

Version: Retinoblastoma 3.2.0.0

Summary of Changes

The following changes have been made since the October 2013 release.

The following data elements were modified:

- Procedure
- Tumor Site
- Tumor Site After Sectioning
- Tumor Involvement of Other Ocular Structures
- Growth Pattern
- Histologic Features
- Distant Metastasis (pM)
- Additional Pathologic Findings

The following data element was added:

- Anaplasia Grade

The following data elements were deleted:

- Specimen Size
- Tumor Basal Area on Transillumination (changed from required to optional)

Surgical Pathology Cancer Case Summary

Protocol web posting date: January 2016

RETINOBLASTOMA: Enucleation, Partial or Complete Exenteration (Notes A, B, C)

Select a single response unless otherwise indicated.

Procedure

- Enucleation
Length of optic nerve: ___ mm
- Partial exenteration
- Complete exenteration
- Other (specify): _____
- Not specified

Specimen Laterality

- Right
- Left
- Not specified

Tumor Site (macroscopic examination/transillumination) (select all that apply) (Notes D, E)

- Cannot be determined
- Superotemporal quadrant of globe
- Superonasal quadrant of globe
- Inferotemporal quadrant of globe
- Inferonasal quadrant of globe
- Between ___ and ___ o'clock
- Other (specify): _____

Tumor Size After Sectioning (Note F)

- Cannot be determined
- Greatest basal diameter: ___ mm
- + Base at cut edge: ___ mm
- Greatest height: ___ mm
- + Height at cut edge: ___ mm

Tumor Site After Sectioning (Notes G, H)

- Cannot be determined
 - Superonasal
 - Inferonasal
 - Superotemporal
 - Inferotemporal
- + Distance from anterior edge of tumor to limbus at cut edge: ___ mm
 + Distance of posterior margin of tumor base from edge of optic disc: ___ mm

Tumor Involvement of Other Ocular Structures (select all that apply) (Note I)

- Cannot be determined
- Cornea
- Anterior chamber
- Iris
- Angle

+ Data elements preceded by this symbol are not required. However, these elements may be clinically important but are not yet validated or regularly used in patient management.

- Lens
- Ciliary body
- Vitreous
- Retina
- Sub-retinal space
- Optic disc
- Choroid, minimal (solid tumor nest less than 3 mm in maximum diameter [width or thickness])
- Choroid, massive (solid tumor nest 3 mm or more in maximum diameter [width or thickness])
- Sclera
- Vortex vein
- Orbit
- Other (specify): _____

Growth Pattern (Note J)

- Cannot be determined
- Endophytic
- Exophytic
- Combined endophytic/exophytic
- Diffuse
- Anterior diffuse

Extent of Optic Nerve Invasion

- Cannot be determined
- None
- Anterior to lamina cribrosa
- At lamina cribrosa
- Posterior to lamina cribrosa but not to end of nerve
- To cut end of optic nerve

Histologic Grade

- pGX: Grade cannot be assessed
- pG1: Well differentiated
- pG2: Moderately differentiated
- pG3: Poorly differentiated
- pG4: Undifferentiated

+ Histologic Features (applicable to differentiated tumors only) (select all that apply) (Notes K, L)

- + Homer Wright rosettes
- + Flexner-Wintersteiner rosettes
- + Fleurettes

+ Anaplasia Grade

Note: Grade based on the highest level of anaplasia in the tumor, with at least 30% of the tumor being able to be graded.

- + Mild
- + Moderate
- + Severe
- + Cannot be determined

Margins (select all that apply)

- Cannot be assessed
- No tumor at margins
- Tumor present at surgical margin of optic nerve
- Extrascleral extension (for enucleation specimens)
- Other margin(s) involved (specify): _____

Pathologic Staging (pTNM) (Note M)TNM Descriptors (required only if applicable) (select all that apply)

- m (multiple primary tumors)
 r (recurrent)
 y (posttreatment)

Primary Tumor (pT)

- pTX: Primary tumor cannot be assessed
 pT0: No evidence of primary tumor
 pT1: Tumor confined to the eye with no optic nerve or choroidal invasion
 pT2: Tumor with minimal optic nerve and/or choroidal invasion:
 pT2a: Tumor superficially invades optic nerve head but does not extend past lamina cribrosa *or* tumor exhibits focal choroidal invasion
 pT2b: Tumor superficially invades optic nerve head but does not extend past lamina cribrosa *and* exhibits focal choroidal invasion
 pT3: Tumor with significant optic nerve and/or choroidal invasion:
 pT3a: Tumor invades optic nerve past lamina cribrosa but not to surgical resection line *or* tumor exhibits massive choroidal invasion
 pT3b: Tumor invades optic nerve past lamina cribrosa but not to surgical resection line *and* exhibits massive choroidal invasion
 pT4: Tumor invades optic nerve to resection line or exhibits extra-ocular extension elsewhere:
 pT4a: Tumor invades optic nerve to resection line but no extra-ocular extension identified
 pT4b: Tumor invades optic nerve to resection line and extra-ocular extension identified

Regional Lymph Nodes (pN)

- pNX: Regional lymph nodes cannot be assessed
 pN0: No regional lymph node involvement
 pN1: Regional lymph node involvement (preauricular, cervical, submandibular)
 pN2: Distant lymph node involvement

Distant Metastasis (pM) (required only if confirmed pathologically in this case)

- pM1: Metastasis to sites other than CNS
 pM1a: Single lesion
 pM1b: Multiple lesions
 pM1c: CNS metastasis
 pM1d: Discrete mass(es) without leptomeningeal and/or CSF involvement
 pM1e: Leptomeningeal and/or CSF involvement

Specify sites(s), if known: _____

+ Additional Pathologic Findings (select all that apply)

- + None identified
 + Calcifications
 + Mitotic rate: Number of mitoses per 40x objective with a field area of 0.152 mm² (specify): _____
 + Apoptosis
 + Necrosis
 + Basophilic vascular deposits
 + Inflammatory cells
 + Hemorrhage
 + Retinal detachment
 + Neovascularization (specify site): _____
 + Other (specify): _____

+ Comment(s)

+ Data elements preceded by this symbol are not required. However, these elements may be clinically important but are not yet validated or regularly used in patient management.

Explanatory Notes

A. Cytology/Biopsy

Cytologic and biopsy specimens are rarely obtained from eyes with suspected retinoblastoma owing to the potential risk of tumor seeding. An anterior chamber paracentesis may be performed, if indicated by clinical findings, and is not associated with risk of tumor seeding.^{1,2}

B. Fixation

The minimum recommended fixation time for whole globes with intraocular tumors is 48 hours. The globe should be fixed in an adequate volume of fixative with a 10:1 ratio of fixative volume to specimen volume recommended. Incisions or windows in the globe are not necessary for adequate penetration of fixative and are not recommended. Injection of fixative into the globe is also not recommended.

C. Additional Studies

Genetic studies may be requested on neoplastic tissue and should be harvested prior to fixation.³ The surgical margin of the optic nerve should be obtained prior to opening the globe (Note E). Once tissue is harvested for genetic studies, the globe can be fixed prior to completing macroscopic examination. The appropriate materials/medium required by the laboratory performing genetic testing should be obtained prior to the procedure.

D. Processing With Tumor Sampling:

To collect the tumor specimen, the optic nerve should be removed before opening the globe to prevent the optic nerve from accidentally becoming contaminated with artifactual clumps of tumor cells (so-called “floaters”). The surgeon should first ink the surgical margin of the optic nerve, then cut the optic nerve stump off from the sclera with a sharp razor about 2 mm behind the globe. The optic nerve stump, which should be kept separate from the globe, should be placed into a jar of 10% buffered formaldehyde. Then, a sample of tumor should be obtained by opening a small sclero-choroidal window adjacent to the tumor near the equator with a 6- to 8-mm corneal trephine. Once the opening into the vitreous chamber is established, tumor tissue should be gently removed with forceps and scissors. It is best to leave a hinge on 1 side of the scleral flap so that it can be closed with 1 or 2 suture(s) following the removal of tumor sample. This is done in an attempt to maintain the overall spherical architecture of the specimen during fixation. The globe should be placed in a second jar of formalin (separate from the optic nerve stump) and be allowed to fix for at least 24 to 48 hours.

E. Orientation of Globe

The orientation of a globe may be determined by identifying extraocular muscle insertions, optic nerve and other landmarks as illustrated in Figure 1. The terms *temporal* and *nasal* are generally used in place of *lateral* and *medial* with reference to ocular anatomy.

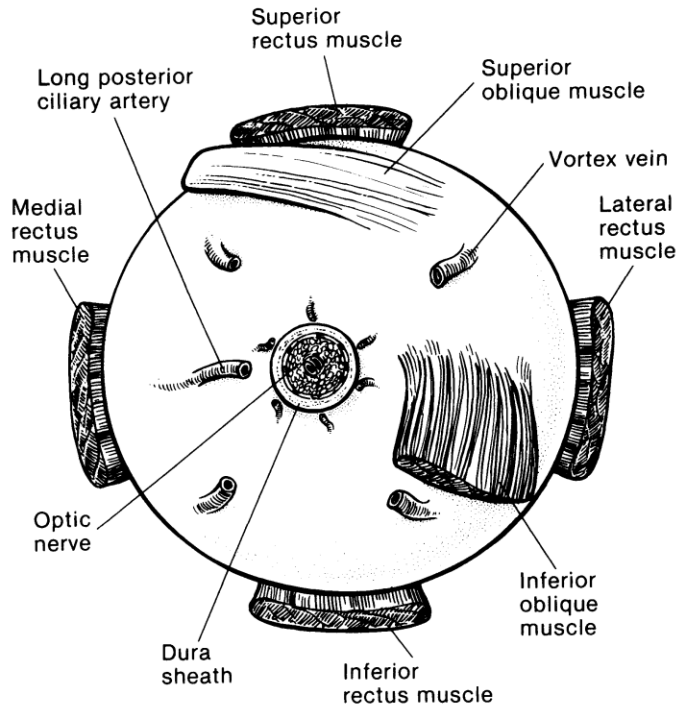


Figure 1. Anatomic landmarks of the posterior aspect of the globe (right eye). The position of the inferior oblique muscle relative to the optic nerve is most helpful in orienting the globe. The inferior oblique muscle insertion is located temporal (lateral) to the optic nerve on the sclera, and its fibers travel inferonasally from its insertion. The long posterior ciliary artery is often seen as a blue-gray line in the sclera on either side of the optic nerve and marks the horizontal meridian of the globe. Reprinted with permission from WB Saunders Company.

F. Processing Without Tumor Sampling

If there is no need for fresh tissue sampling, the enucleated globe should simply be fixed in 10% buffered formaldehyde for at least 24 and preferably 48 hours. When the fixed globe is examined by the pathologist, if the optic nerve was not previously amputated in the operative room, that should be performed first as described above. The surgical margin of the nerve stump should be embedded face down in paraffin for sectioning (ie, thereby obtaining cross-sections of the nerve, starting at the surgical margin). Then, the eye itself is sectioned. First, a section should be made that extends from pupil through the optic nerve (the “P-O” section), which contains the center of the optic nerve with all the optic nerve structures (optic nerve head, lamina cribrosa, and postlaminar optic nerve). Preferably this plane should bisect the largest dimension of the tumor, previously identified by transillumination and during clinical examination. When possible, the plane should avoid the scleral opening if one was made for fresh tumor sampling. This section is critical for evaluation of the optic nerve for tumor invasion. The P-O section and minor calottes are then embedded in paraffin. The embedded P-O calotte is then sectioned every 100 to 150 microns (each section being about 5 microns thick), for a total of about 10 to 20 sections. Additional sections should also be made anterior-posteriorly in a bread-loaf fashion through the minor calottes. These segments should be submitted in 1 cassette per calotte on edge to evaluate the choroid for invasion. Three levels of this block are usually sufficient for examination. In total, 4 cassettes are submitted: the optic nerve stump, the P-O section, and the 2 minor calottes (unless 1 or both of these has no visible tumor).

G. Sectioning the Globe

The globe is generally sectioned in the horizontal or vertical plane, with care to include the pupil and optic nerve in the cassette to be submitted for microscopic examination. If the mass cannot be included with horizontal or vertical sectioning, the globe is sectioned obliquely to include tumor, pupil, and optic nerve (Figure 2). The surgical margin of the optic nerve should be sectioned and submitted prior to sectioning the globe to ensure that intraocular malignant cells do not contaminate this important surgical margin.³ Retinoblastoma is an extremely friable tumor.

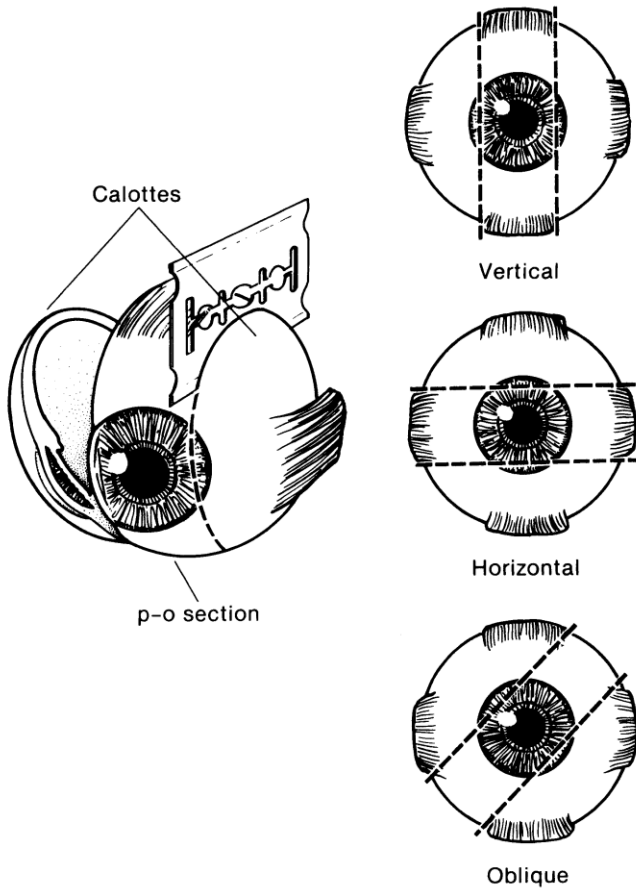


Figure 2. The most common methods of sectioning a globe. After transillumination, the tumor base is marked, if possible, and included in the pupil-optic (p-o) nerve section and submitted for processing. If tumor is found in either of the calottes, these may also be submitted for sectioning. The meridian in which the globe was sectioned should be included in the gross description of the pathology report. It is not uncommon to induce an artifactual retinal detachment while sectioning the globe. This can be minimized by gentle handling and by avoiding a sawing motion with the blade. Reprinted with permission from WB Saunders Company.

Each calotte should also be sampled. The calottes should be breadloafed and submitted in a cassette on edge for processing as shown in Figure 3.

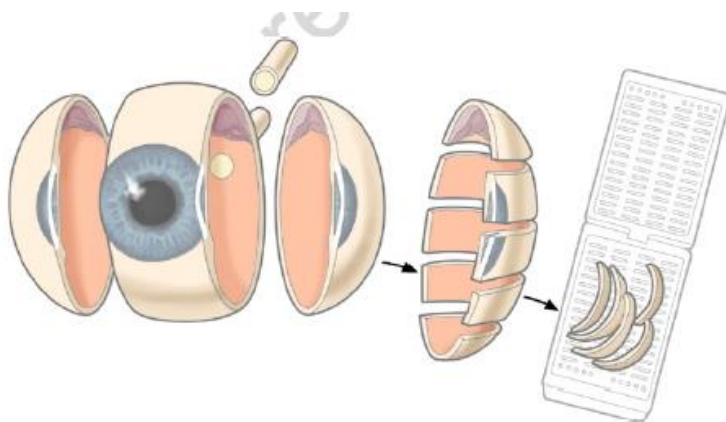


Figure 3. Calotte sampling. From Grossniklaus HE.¹⁹ Reproduced with kind permission of Springer Science+Business Media.

H. Sections Submitted for Microscopic Examination

Multiple sections should be examined, with special attention to sections containing optic nerve and tumor. The nerve should be sectioned along the various levels to determine tumor extension.

I. Rules for Classification

Choroidal Invasion: The presence and the extent (focal versus massive) of choroidal invasion by tumor should be stated. Differentiation should be made between true choroidal invasion and artifactual invasion due to seeding of fresh tumor cells during post-enucleation retrieval of tumor tissue and/or gross sectioning.

Artifactual invasion is identified when there are groups of tumor cells present in the open spaces between intraocular structures, extraocular tissues and/or subarachnoid space.

True invasion is defined as 1 or more solid nests of tumor cells that fills or replaces the choroid and has pushing borders. Note: Invasion of the sub-retinal pigment epithelium (RPE) space, where tumor cells are present under the RPE (but not beyond Bruch's membrane into the choroid) is not choroidal invasion.

Focal choroidal invasion is defined as a solid nest of tumor that measures less than 3 mm in maximum diameter (width or thickness).

Massive choroidal invasion is defined as a solid tumor nest 3 mm or more in maximum diameter (width or thickness) in contact with the underlying sclera.

J. Growth Pattern

Endophytic growth pattern indicates growth from the inner retinal surface into the vitreous cavity. Exophytic tumors grow primarily from the outer surface of the retina into the subretinal space toward the choroid. Mixed growth pattern exhibits features of both endophytic and exophytic growth. Diffuse infiltrating tumors grow laterally within the retina without significant thickening.

K. Histologic Features

Typical histologic features include cells with large, basophilic nuclei and scant cytoplasm. Mitoses are generally frequent. Calcification and necrosis are common with sleeves of viable cells typically surrounding blood vessels (pseudorosettes). Apoptotic cells may be seen. The extent of differentiation may be judged based on the presence and type of rosettes. Homer-Wright rosettes similar to those seen in neuroblastoma or medulloblastoma may be seen and are not a sign of significant differentiation. Flexner-Wintersteiner rosettes are evidence of higher differentiation. Fleurettes are considered the most differentiated form of rosette found in the tumor. A benign variant of retinoblastoma termed *retinocytoma* or *retinoma* has been described. This tumor consists entirely of benign, well-differentiated cells often with associated calcification. The cells have smaller, less hyperchromatic nuclei and abundant cytoplasm. Necrosis is typically absent and mitotic figures are rare.⁴⁻⁹ Retinoblastomas may arise in multicentric foci.

L. Histologic Features of Additional Prognostic Significance

Histologic features with prognostic significance for survival include the following: invasion of optic nerve, particularly if tumor is present at the surgical margin (most important feature); invasion of sclera; invasion of choroid; tumor size; basophilic staining of tumor vessels; seeding of vitreous; degree of differentiation; involvement of anterior segment; and growth pattern.¹⁰⁻¹⁶ This list should not be confused with the Reese-Ellsworth classification, which is intended as a predictor for visual outcome, not survival.¹⁷

M. TNM and Stage Groupings

The American Joint Committee on Cancer (AJCC) and the International Union Against Cancer (UICC) TNM staging system for retinoblastoma is shown below.¹⁸

By AJCC/UICC convention, the designation "T" refers to a primary tumor that has not been previously treated. The symbol "p" refers to the pathologic classification of the TNM, as opposed to the clinical classification, and is based on gross and microscopic examination. pT entails a resection of the primary tumor or biopsy adequate to evaluate the highest pT category, pN entails removal of nodes adequate to validate lymph node metastasis, and pM implies

microscopic examination of distant lesions. Clinical classification (cTNM) is usually carried out by the referring physician before treatment during initial evaluation of the patient or when pathologic classification is not possible.

Pathologic staging is usually performed after surgical resection of the primary tumor. Pathologic staging depends on pathologic documentation of the anatomic extent of disease, whether or not the primary tumor has been completely removed. If a biopsied tumor is not resected for any reason (eg, when technically unfeasible) and if the highest T and N categories or the M1 category of the tumor can be confirmed microscopically, the criteria for pathologic classification and staging have been satisfied without total removal of the primary cancer.

Clinical TNM Classifications:

Primary Tumor (T)

- TX Primary tumor cannot be assessed.
- T0 No evidence of primary tumor.
- T1 Tumors no more than 2/3 the volume of the eye with no vitreous or subretinal seeding.
- T1a No tumor in either eye is greater than 3 mm in largest dimension or located closer than 1.5 mm to the optic nerve or fovea.
- T1b At least one tumor is greater than 3 mm in largest dimension or located closer than 1.5 mm to the optic nerve or fovea. No retinal detachment or subretinal fluid beyond 5 mm from the base of the tumor.
- T1c At least one tumor is greater than 3 mm in largest dimension or located closer than 1.5 mm to the optic nerve or fovea. With retinal detachment or subretinal fluid beyond 5 mm from the base of the tumor.
- T2 Tumors no more than 2/3 the volume of the eye with vitreous or subretinal seeding. Can have retinal detachment.
- T2a Focal vitreous and/or subretinal seeding of fine aggregates of tumor cells is present, but no large clumps or "snowballs" of tumor cells.
- T2b Massive vitreous and/or subretinal seeding is present, defined as diffuse clumps or "snowballs" of tumor cells.
- T3 Severe intraocular disease.
- T3a Tumor fills more than 2/3 of the eye.
- T3b One or more complications present, which may include tumor-associated neovascular or angle closure glaucoma, tumor extension into the anterior segment, hyphema, vitreous hemorrhage, or orbital cellulitis.
- T4 Extraocular disease detected by imaging studies.
- T4a Invasion of optic nerve.
- T4b Invasion into the orbit.
- T4c Intracranial extension not past chiasm.
- T4d Intracranial extension past chiasm.

Regional Lymph Nodes (N)

- NX Regional lymph nodes cannot be assessed
- N0 No regional lymph node involvement
- N1 Regional lymph node involvement (preauricular, cervical, submandibular)
- N2 Distant lymph node involvement

Metastasis (M)

- M0 No metastasis
- M1 Systemic metastasis
- M1a Single lesion to sites other than CNS
- M1b Multiple lesions to sites other than CNS
- M1c Prechiasmatic CNS lesion(s)
- M1d Postchiasmatic CNS lesion(s)
- M1e Leptomeningeal and/or CSF involvement

Pathologic Classification (pTNM):

Primary Tumor (pT)

- pTX Primary tumor cannot be assessed.
- pT0 No evidence of primary tumor.
- pT1 Tumor confined to eye with no optic nerve or choroidal invasion.

- pT2 Tumor with minimal optic nerve and/or choroidal invasion:
 pT2a Tumor superficially invades optic nerve head but does not extend past lamina cribrosa *or* tumor exhibits focal choroidal invasion.
 pT2b Tumor superficially invades optic nerve head but does not extend past lamina cribrosa *and* exhibits focal choroidal invasion.
 pT3 Tumor with significant optic nerve and/or choroidal invasion:
 pT3a Tumor invades optic nerve past lamina cribrosa but not to surgical resection line *or* tumor exhibits massive choroidal invasion.
 pT3b Tumor invades optic nerve past lamina cribrosa but not to surgical resection line *and* exhibits massive choroidal invasion.
 pT4 Tumor invades optic nerve to resection line or exhibits extra-ocular extension elsewhere.
 pT4a Tumor invades optic nerve to resection line but no extra-ocular extension identified.
 pT4b Tumor invades optic nerve to resection line and extra-ocular extension identified.

Regional Lymph Nodes (pN)

- pNX Regional lymph nodes cannot be assessed
 pN0 No regional lymph node involvement
 pN1 Regional lymph node involvement (preauricular, cervical)
 pN2 Distant lymph node involvement

Metastasis (pM)

- pM0 No metastasis
 pM1 Metastasis to sites other than CNS
 pM1a Single lesion
 pM1b Multiple lesions
 pM1c CNS metastasis
 pM1d Discrete mass(es) without leptomeningeal and/or CSF involvement
 pM1e Leptomeningeal and/or CSF involvement

TNM Stage Groupings

No stage grouping applies.

TNM Descriptors

For identification of special cases of TNM or pTNM classifications, the “m” suffix and “y,” “r,” and “a” prefixes are used. Although they do not affect the stage grouping, they indicate cases needing separate analysis.

The “m” suffix indicates the presence of multiple primary tumors in a single site and is recorded in parentheses: pT(m)NM.

The “y” prefix indicates those cases in which classification is performed during or following initial multimodality therapy (ie, neoadjuvant chemotherapy, radiation therapy, or both chemotherapy and radiation therapy). The cTNM or pTNM category is identified by a “y” prefix. The ycTNM or ypTNM categorizes the extent of tumor actually present at the time of that examination. The “y” categorization is not an estimate of tumor prior to multimodality therapy (ie, before initiation of neoadjuvant therapy).

The “r” prefix indicates a recurrent tumor when staged after a documented disease-free interval, and is identified by the “r” prefix: rTNM.

The “a” prefix designates the stage determined at autopsy: aTNM.

Additional DescriptorsResidual Tumor (R)

Tumor remaining in a patient after therapy with curative intent (eg, surgical resection for cure) is categorized by a system known as R classification, shown below.

RX	Presence of residual tumor cannot be assessed
R0	No residual tumor
R1	Microscopic residual tumor
R2	Macroscopic residual tumor

For the surgeon, the R classification may be useful to indicate the known or assumed status of the completeness of a surgical excision. For the pathologist, the R classification is relevant to the status of the margins of a surgical resection specimen. That is, tumor involving the resection margin on pathologic examination may be assumed to correspond to residual tumor in the patient and may be classified as macroscopic or microscopic according to the findings at the specimen margin(s).

Lymph-Vascular Invasion (LVI)

LVI indicates whether microscopic lymph-vascular invasion is identified in the pathology report. LVI includes lymphatic invasion, vascular invasion, or lymph-vascular invasion. By AJCC/UICC convention, LVI does not affect the T category indicating local extent of tumor unless specifically included in the definition of a T category.

References

- Karcioglu ZA, Gordon RA, Karcioglu GL. Tumor seeding in ocular fine needle aspiration biopsy. *Ophthalmology*. 1985;92:1763-1767.
- Stevenson KE, Hungerford J, Garner A. Local extraocular extension of retinoblastoma following intraocular surgery. *Br J Ophthalmol*. 1989;73:739-742.
- Shields JA, Shields CL, De Potter P. Enucleation technique for children with retinoblastoma. *J Ped Ophthalmol Strabismus*. 1992;29:213-215.
- Zimmerman LE. Retinoblastoma and retinocytoma. In: Spencer WH, ed. *Ophthalmic Pathology. An Atlas and Textbook*. 3rd ed. Philadelphia, Pa: WB Saunders Co; 1986:1292-1351.
- Tso MOM, Fine BS, Zimmerman LE. The Flexner-Wintersteiner rosettes in retinoblastoma. *Arch Pathol*. 1969;88:665-671.
- Tso MOM, Fine BS, Zimmerman LE. The nature of retinoblastoma, I: photoreceptor differentiation: a clinical and histologic study. *Am J Ophthalmol*. 1970;69:339-350.
- Tso MOM, Fine BS, Zimmerman LE. The nature of retinoblastoma, II: photoreceptor differentiation: an electron microscopic study. *Am J Ophthalmol*. 1970;69:350-359.
- Margo C, Hidayat A, Kopelman J, Zimmerman LE. Retinocytoma: a benign variant of retinoblastoma. *Arch Ophthalmol*. 1983;101:1519-1531.
- Gallie BL, Ellsworth RM, Abramson DH, Phillips RA. Retinoma: spontaneous regression of retinoblastoma or benign manifestation of the mutation? *Br J Cancer*. 1982;45:513-521.
- Redler LD, Ellsworth RM. Prognostic importance of choroidal invasion in retinoblastoma. *Arch Ophthalmol*. 1973;90:294-296.
- Kopelman JE, McLean IW. Multivariate analysis of clinical and histological risk factors for metastasis in retinoblastoma [abstract]. *Invest Ophthalmol Vis Sci*. 1983;24(ARVO suppl):50.
- Kopelman JE, McLean IW. Multivariate analysis of risk factors for metastasis in retinoblastoma treated by enucleation. *Ophthalmology*. 1987;94:371-377.
- Haik BG, Dunleavy SA, Cooke C, et al. Retinoblastoma with anterior chamber extension. *Ophthalmology*. 1987;94:367-370.
- Magrann I, Abramson DH, Ellsworth RM. Optic nerve involvement in retinoblastoma. *Ophthalmology*. 1989;96:217-222.
- Shields CL, Shields JA, Baez KA, Cater J, De Potter PV. Choroidal invasion of retinoblastoma: metastatic potential and clinical risk factors. *Br J Ophthalmol*. 1993;77:544-548.
- Shields CL, Shields JA, Baez K, Cater JR, De Potter P. Optic nerve invasion of retinoblastoma: metastatic potential and clinical risk factors. *Cancer*. 1994;73:692-698.
- Reese AB, Ellsworth RM. The evaluation and current concept of retinoblastoma therapy. *Trans Am Acad Ophthalmol Otolaryngol*. 1963;67:164-172.
- Chapter 44: Retinoblastoma. In: Edge SD, Byrd DR, Carducci MA, Compton CC, eds. *AJCC Cancer Staging Manual*. 7th ed. New York, NY: Springer; 2009.
- Brown HH, Wells JR, Grossniklaus HE. Chapter 11. Tissue preparation for pathologic examination. In: Grossniklaus HE, ed. *Pocket Guide to Ocular Oncology and Pathology*. Heidelberg, Germany: Springer; 2013.

20. Finger PT, Harbour JW, Karcioğlu Z. Risk factors for metastasis in retinoblastoma. *Surv Ophthalmol.* 2002;47:1-16.
21. Mendoza PR, Specht CS, Hubbard GB, Wells JR, Lynn MJ, Zhang Q, Kong J, Grossniklaus HE. Histopathologic grading of anaplasia in retinoblastoma. *Am J Ophthalmol.* 2015;159:764-776.

Bibliography

- Albert DM. Principles of pathology. In: Albert DM, Jakobiec FA, eds. *Principles and Practice of Ophthalmology.* Vol. 4. Philadelphia, Pa: WB Saunders Co; 1994:2101-2126.
- Albert DM, Dryja TP. The eye. In: Cotran RS, Kumar V, Robbins SL, eds. *Pathologic Basis of Disease.* 4th ed. Philadelphia, Pa: WB Saunders Co; 1998.
- Sahel JA, Brini A, Albert DM. Pathology of the retina and vitreous. In: Albert DM, Jakobiec FA. *Principles and Practice of Ophthalmology.* Vol. 4. Philadelphia, Pa: WB Saunders Co; 1994:2239-2280.
- Yanoff MF, Fine BS. *Ocular Pathology. A Text and Atlas.* 3rd ed. Philadelphia, Pa: JB Lippincott Co; 1989:684-694.
- Zimmerman LE. Retinoblastoma and retinocytoma. In: Spencer WH, ed. *Ophthalmic Pathology. An Atlas and Textbook.* 3rd ed. Philadelphia, Pa: WB Saunders Co; 1986:1292-1351.