

Protocol for the Examination of Specimens From Patients With Carcinomas of the Lip and Oral Cavity

Protocol applies to all invasive carcinomas of the oral cavity,
including lip and tongue. Mucosal melanoma is included.
Lymphomas and sarcomas are not included.

Based on AJCC/UICC TNM, 7th edition
Protocol web posting date: October 2013

Procedures

- Biopsy
- Resection

Authors

Raja R. Seethala, MD, FCAP*

Department of Pathology, University of Pittsburgh School of Medicine, Pittsburgh, PA

Ilan Weinreb, MD, FCAP

Department of Anatomical Pathology, University Health Network, Toronto, ON

Diane L. Carlson, MD, FCAP

Department of Pathology, Memorial Sloan-Kettering Cancer Center, New York, NY

Jonathan B. McHugh, MD, FCAP

Department of Pathology, University of Michigan, Ann Arbor, MI

Louis B. Harrison, MD

Department of Radiation Oncology, Beth Israel Medical Center, St. Luke's and Roosevelt Hospitals,
New York, NY

Mary S. Richardson, MD, DDS

Department of Pathology, Medical University of South Carolina, Charleston, SC

Jatin Shah, MD, FACS

Head and Neck Service, Department of Surgery, Memorial Sloan Kettering Cancer Center, New York,
NY

Robert L Ferris, MD, PhD, FACS

Department of Otolaryngology, University of Pittsburgh School of Medicine, Pittsburgh, PA

Bruce M. Wenig, MD, FCAP

Department of Pathology and Laboratory Medicine, Beth Israel Medical Center, St. Luke's and
Roosevelt Hospitals, New York, NY

Lester D. R. Thompson, MD, FCAP†

Department of Pathology, Southern California Permanente Medical Group, Woodland Hills, CA

For the Members of the Cancer Committee, College of American Pathologists

* Denotes primary author. † Denotes senior author. All other contributing authors are listed alphabetically.

Previous contributors: Richard Zarbo, MD, DMD; Jennifer L. Hunt; Leon Barnes, MD; Gary Ellis, MD, John Chan, MD.

© 2013 College of American Pathologists (CAP). All rights reserved.

The College does not permit reproduction of any substantial portion of these protocols without its written authorization. The College hereby authorizes use of these protocols by physicians and other health care providers in reporting on surgical specimens, in teaching, and in carrying out medical research for nonprofit purposes. This authorization does not extend to reproduction or other use of any substantial portion of these protocols for commercial purposes without the written consent of the College.

The CAP also authorizes physicians and other health care practitioners to make modified versions of the Protocols solely for their individual use in reporting on surgical specimens for individual patients, teaching, and carrying out medical research for non-profit purposes.

The CAP further authorizes the following uses by physicians and other health care practitioners, in reporting on surgical specimens for individual patients, in teaching, and in carrying out medical research for non-profit purposes: (1) **Dictation** from the original or modified protocols for the purposes of creating a text-based patient record on paper, or in a word processing document; (2) **Copying** from the original or modified protocols into a text-based patient record on paper, or in a word processing document; (3) The use of a **computerized system** for items (1) and (2), provided that the protocol data is stored intact as a single text-based document, and is not stored as multiple discrete data fields.

Other than uses (1), (2), and (3) above, the CAP does not authorize any use of the Protocols in electronic medical records systems, pathology informatics systems, cancer registry computer systems, computerized databases, mappings between coding works, or any computerized system without a written license from the CAP.

Any public dissemination of the original or modified protocols is prohibited without a written license from the CAP.

The College of American Pathologists offers these protocols to assist pathologists in providing clinically useful and relevant information when reporting results of surgical specimen examinations of surgical specimens. The College regards the reporting elements in the "Surgical Pathology Cancer Case Summary" portion of the protocols as essential elements of the pathology report. However, the manner in which these elements are reported is at the discretion of each specific pathologist, taking into account clinician preferences, institutional policies, and individual practice.

The College developed these protocols as an educational tool to assist pathologists in the useful reporting of relevant information. It did not issue the protocols for use in litigation, reimbursement, or other contexts. Nevertheless, the College recognizes that the protocols might be used by hospitals, attorneys, payers, and others. Indeed, effective January 1, 2004, the Commission on Cancer of the American College of Surgeons mandated the use of the required data elements of the protocols as part of its Cancer Program Standards for Approved Cancer Programs. Therefore, it becomes even more important for pathologists to familiarize themselves with these documents. At the same time, the College cautions that use of the protocols other than for their intended educational purpose may involve additional considerations that are beyond the scope of this document.

The inclusion of a product name or service in a CAP publication should not be construed as an endorsement of such product or service, nor is failure to include the name of a product or service to be construed as disapproval.

CAP Lip and Oral Cavity Protocol Revision History

Version Code

The definition of the version code can be found at www.cap.org/cancerprotocols.

Version: LipOralCavity 3.2.0.0

Summary of Changes

The following changes have been made since the June 2012 release.

Entire Document

"Mucosal malignant melanoma" was changed to "Mucosal melanoma."

Excisional Biopsy, Resection

Procedure

"Incisional biopsy" was deleted.

Specimen Laterality

"Bilateral" was deleted and "(select all that apply)" was added, as follows:

Specimen Laterality (select all that apply)

- ☐ Right
- ☐ Left
- ☐ Midline
- ☐ Not specified

Histologic Type

Neuroendocrine Carcinoma

"Large cell carcinoma, neuroendocrine type (poorly differentiated neuroendocrine carcinoma)" was added.

Carcinomas of Minor Salivary Glands

Low, intermediate, and high grade were added to adenoid cystic carcinoma as follows:

- ☐ Adenoid cystic carcinoma
 - ☐ Low grade
 - ☐ Intermediate grade
 - ☐ High grade

Margins

Reporting on margins was updated, as follows:

- ☐ Cannot be assessed
- ☐ Margins uninvolved by invasive carcinoma
 - Distance from closest margin:
Specify distance: ____ mm
 - ☐ Cannot be determined
 - Specify location of closest margin, per orientation, if possible: _____
 - + Location and distance of other close margins (Note D): _____
- ☐ Margins involved by invasive carcinoma
 - Specify margin(s), per orientation, if possible: _____
- ☐ Margins uninvolved by carcinoma in situ (includes moderate and severe dysplasia#) (Note D)
 - Distance from closest margin:
Specify distance: ____ mm
 - ☐ Cannot be determined
 - Specify location of closest margin, per orientation, if possible: _____

___ Margins involved by carcinoma in situ (includes moderate and severe dysplasia[#]) (Note D)

Specify margin(s), per orientation, if possible: _____

[#] Applicable only to squamous cell carcinoma and histologic variants.

Pathologic Staging (pTNM)

Regional Lymph Nodes (pN)

Number of Lymph Nodes Involved

Size was changed from "largest positive lymph node" to largest metastatic focus in the lymph node."

Extracapsular extension was added, as follows:

Extracapsular Extension

___ Not identified

___ Present

+ Distance from lymph node capsule: _____ mm

___ Indeterminate

Distant Metastasis (pM)

Deleted "Source of pathologic metastatic specimen (specify)."

Explanatory Notes

B. Histologic Type

Neuroendocrine carcinoma: added "Large cell carcinoma, neuroendocrine type (poorly differentiated neuroendocrine carcinoma)."

D. Histologic Grade

E. Surgical Margins

F. Orientation of Specimen

G. Perineural Invasion

O. Ancillary Testing

Edits were made to these notes.

K. Regional Lymph Nodes (pN0): Isolated Tumor Cells

Classification scheme for ITCs was deleted.

L. Lymph Nodes

Measurement of Tumor Metastasis

Deleted: There is conflicting data in the literature on the significance of the size of the largest metastatic lymph node on the risk of regional recurrence and a predictor of poor overall survival.²⁴ While the diameter of the largest positive lymph node may potentially serve as a predictor of outcome, it may not represent an independent predictor of outcome when other pathologic factors are considered.²⁴

References

References were updated.

Surgical Pathology Cancer Case Summary

Protocol web posting date: October 2013

LIP AND ORAL CAVITY: Excisional Biopsy, Resection

Select a single response unless otherwise indicated.

Specimen (select all that apply) (Note A)

- ☐ Vermilion border upper lip
- ☐ Vermilion border lower lip
- ☐ Mucosa of upper lip
- ☐ Mucosa of lower lip
- ☐ Commissure of lip
- ☐ Lateral border of tongue
- ☐ Ventral surface of tongue, not otherwise specified (NOS)
- ☐ Dorsal surface of tongue, NOS
- ☐ Anterior two-thirds of tongue, NOS
- ☐ Upper gingiva (gum)
- ☐ Lower gingiva (gum)
- ☐ Anterior floor of mouth
- ☐ Floor of mouth, NOS
- ☐ Hard palate
- ☐ Buccal mucosa (inner cheek)
- ☐ Vestibule of mouth
 - ☐ Upper
 - ☐ Lower
- ☐ Alveolar process
 - ☐ Upper
 - ☐ Lower
- ☐ Mandible
- ☐ Maxilla
- ☐ Other (specify): _____
- ☐ Not specified

Received:

- ☐ Fresh
- ☐ In formalin
- ☐ Other (specify): _____

Procedure (select all that apply)

- ☐ Excisional biopsy
- ☐ Resection
 - ☐ Glossectomy (specify): _____
 - ☐ Mandibulectomy (specify): _____
 - ☐ Maxillectomy (specify): _____
 - ☐ Palatotomy
- ☐ Neck (lymph node) dissection (specify): _____
- ☐ Other (specify): _____
- ☐ Not specified

+ Data elements preceded by this symbol are not required. However, these elements may be clinically important but are not yet validated or regularly used in patient management.

+ Specimen Integrity

- + ☐ Intact
- + ☐ Fragmented

Specimen Size

Greatest dimensions: ____ x ____ x ____ cm

+ Additional dimensions (if more than 1 part): ____ x ____ x ____ cm

Specimen Laterality (select all that apply)

- ☐ Right
- ☐ Left
- ☐ Midline
- ☐ Not specified

Tumor Site (select all that apply) (Note A)

- ☐ Vermilion border upper lip
- ☐ Vermilion border lower lip
- ☐ Mucosa of upper lip
- ☐ Mucosa of lower lip
- ☐ Commissure of lip
- ☐ Lateral border of tongue
- ☐ Ventral surface of tongue, NOS
- ☐ Dorsal surface of tongue, NOS
- ☐ Anterior two-thirds of tongue, NOS
- ☐ Upper gingiva (gum)
- ☐ Lower gingiva (gum)
- ☐ Anterior floor of mouth
- ☐ Floor of mouth, NOS
- ☐ Hard palate
- ☐ Buccal mucosa (inner cheek)
- ☐ Vestibule of mouth
 - ☐ Upper
 - ☐ Lower
- ☐ Alveolar process
 - ☐ Upper
 - ☐ Lower
- ☐ Mandible
- ☐ Maxilla
- ☐ Other (specify): _____
- ☐ Not specified

Tumor Focality

- ☐ Single focus
- ☐ Multifocal (specify): _____

Tumor Size

Greatest dimension: ____ cm

+ Additional dimensions: ____ x ____ cm

☐ Cannot be determined (see Comment)

+ Tumor Thickness (pT1 and pT2 tumors) (Note B)

- + Tumor thickness: ____ mm
- + Intact surface mucosa: ____; or ulcerated surface: ____

+ Tumor Description (select all that apply)

- + Gross subtype:
 - + ____ Polypoid
 - + ____ Exophytic
 - + ____ Endophytic
 - + ____ Ulcerated
 - + ____ Sessile
 - + ____ Other (specify): _____

+ Macroscopic Extent of Tumor

- + Specify: _____

Histologic Type (select all that apply) (Note C)Squamous Cell Carcinoma

- ____ Squamous cell carcinoma, conventional
- Variants of Squamous Cell Carcinoma*
- ____ Acantholytic squamous cell carcinoma
- ____ Adenosquamous carcinoma
- ____ Basaloid squamous cell carcinoma
- ____ Papillary squamous cell carcinoma
- ____ Spindle cell squamous cell carcinoma
- ____ Verrucous carcinoma

- ____ Giant cell carcinoma
- ____ Lymphoepithelial carcinoma (non-nasopharyngeal)

Carcinomas of Minor Salivary Glands

- ____ Acinic cell carcinoma
- ____ Adenoid cystic carcinoma
 - ____ Low grade
 - ____ Intermediate grade
 - ____ High grade
- ____ Adenocarcinoma, not otherwise specified (NOS)
 - ____ Low grade
 - ____ Intermediate grade
 - ____ High grade
- ____ Basal cell adenocarcinoma
- ____ Carcinoma ex pleomorphic adenoma (malignant mixed tumor)
 - ____ Low-grade
 - ____ High-grade
 - ____ Invasive
 - ____ Minimally invasive (Note C)
 - ____ Invasive (Note C)
 - ____ Intracapsular (noninvasive)

- ____ Carcinoma, type cannot be determined
- ____ Carcinosarcoma

+ Data elements preceded by this symbol are not required. However, these elements may be clinically important but are not yet validated or regularly used in patient management.

- ☐ Clear cell adenocarcinoma
- ☐ Cystadenocarcinoma
- ☐ Epithelial-myoepithelial carcinoma
- ☐ Mucoepidermoid carcinoma
 - ☐ Low grade
 - ☐ Intermediate grade
 - ☐ High grade
- ☐ Mucinous adenocarcinoma (colloid carcinoma)
- ☐ Myoepithelial carcinoma (malignant myoepithelioma)
- ☐ Oncocytic carcinoma
- ☐ Polymorphous low-grade adenocarcinoma
- ☐ Salivary duct carcinoma
- ☐ Other (specify): _____

Adenocarcinoma, Non-Salivary Gland Type

- ☐ Adenocarcinoma, not otherwise specified (NOS)
 - ☐ Low grade
 - ☐ Intermediate grade
 - ☐ High grade
- ☐ Other (specify): _____

Neuroendocrine Carcinoma

- ☐ Typical carcinoid tumor (well differentiated neuroendocrine carcinoma)
- ☐ Atypical carcinoid tumor (moderately differentiated neuroendocrine carcinoma)
- ☐ Large cell carcinoma, neuroendocrine type (poorly differentiated neuroendocrine carcinoma)
- ☐ Small cell carcinoma, neuroendocrine type (poorly differentiated neuroendocrine carcinoma)
- ☐ Combined (or composite) small cell carcinoma, neuroendocrine type with (specify type):

- ☐ Mucosal melanoma

- ☐ Other (specify): _____
- ☐ Carcinoma, type cannot be determined

Histologic Grade (Note D)

- ☐ Not applicable
- ☐ GX: Cannot be assessed
- ☐ G1: Well differentiated
- ☐ G2: Moderately differentiated
- ☐ G3: Poorly differentiated
- ☐ Other (specify): _____

+ Microscopic Tumor Extension

- + Specify: _____

Margins (select all that apply) (Notes E and F)

- ☐ Cannot be assessed
- ☐ Margins uninvolved by invasive carcinoma
Distance from closest margin:
Specify distance: ____ mm
☐ Cannot be determined
Specify location of closest margin, per orientation, if possible: _____
+ Location and distance of other close margins (Note D): _____
- ☐ Margins involved by invasive carcinoma
Specify margin(s), per orientation, if possible: _____
- ☐ Margins uninvolved by carcinoma in situ (includes moderate and severe dysplasia[#]) (Note E)
Distance from closest margin:
Specify distance: ____ mm
☐ Cannot be determined
Specify location of closest margin, per orientation, if possible: _____
- ☐ Margins involved by carcinoma in situ (includes moderate and severe dysplasia[#]) (Note E)
Specify margin(s), per orientation, if possible: _____

[#] Applicable only to squamous cell carcinoma and histologic variants.

+ Treatment Effect (applicable to carcinomas treated with neoadjuvant therapy)

- + ☐ Not identified
- + ☐ Present (specify): _____
- + ☐ Indeterminate

Lymph-Vascular Invasion

- ☐ Not identified
- ☐ Present
- ☐ Indeterminate

Perineural Invasion (Note G)

- ☐ Not identified
- ☐ Present
- ☐ Indeterminate

Lymph Nodes, Extranodal Extension (Note H)

- ☐ Not identified
- ☐ Present
- ☐ Indeterminate

Pathologic Staging (pTNM) (Note I)

TNM Descriptors (required only if applicable) (select all that apply)

- ☐ m (multiple primary tumors)
- ☐ r (recurrent)
- ☐ y (posttreatment)

For All Carcinomas Excluding Mucosal MelanomaPrimary Tumor (pT)

- ☐ pTX: Cannot be assessed
- ☐ pT0: No evidence of primary tumor
- ☐ pTis: Carcinoma in situ

+ Data elements preceded by this symbol are not required. However, these elements may be clinically important but are not yet validated or regularly used in patient management.

- ☐ pT1: Tumor 2 cm or less in greatest dimension
☐ pT2: Tumor more than 2 cm but not more than 4 cm in greatest dimension
☐ pT3: Tumor more than 4 cm in greatest dimension
☐ pT4a: Moderately advanced local disease.
 Lip: Tumor invades through cortical bone, inferior alveolar nerve, floor of mouth, or skin of face, ie, chin or nose
 Oral cavity: Tumor invades adjacent structures only (eg, through cortical bone [mandible, maxilla], into deep [extrinsic] muscle of tongue [genioglossus, hyoglossus, palatoglossus, and styloglossus], maxillary sinus, skin of face)
☐ pT4b: Very advanced local disease. Tumor invades masticator space, pterygoid plates, or skull base, and/or encases internal carotid artery

Note: Superficial erosion alone of bone/tooth socket by gingival primary is not sufficient to classify a tumor as T4.

Regional Lymph Nodes (pN)# (Notes J through M)

- ☐ pNX: Cannot be assessed
☐ pN0: No regional lymph node metastasis
☐ pN1: Metastasis in a single ipsilateral lymph node, 3 cm or less in greatest dimension
☐ pN2a: Metastasis in a single ipsilateral lymph node, more than 3 cm but not more than 6 cm in greatest dimension
☐ pN2b: Metastasis in multiple ipsilateral lymph nodes, none more than 6 cm in greatest dimension
☐ pN2c: Metastasis in bilateral or contralateral lymph nodes, none more than 6 cm in greatest dimension
☐ pN3: Metastasis in a lymph node more than 6 cm in greatest dimension
☐ No nodes submitted or found

Number of Lymph Nodes Examined

Specify: ☐

☐ Number cannot be determined (explain): _____

Number of Lymph Nodes Involved

Specify: ☐

+ Size (greatest dimension) of the largest metastatic focus in the lymph node: ☐ cm (Note L)

☐ Number cannot be determined (explain): _____

Extracapsular Extension (Note G)

☐ Not identified

☐ Present

+ Distance from lymph node capsule: ☐ mm

☐ Indeterminate

Superior mediastinal lymph nodes are considered regional lymph nodes (level VII). Midline nodes are considered ipsilateral nodes.

Distant Metastasis (pM)

☐ Not applicable

☐ pM1: Distant metastasis

+ Specify site(s), if known: _____

For Mucosal Melanoma (Note I)Primary Tumor (pT)

- ☐ pT3: Mucosal disease
- ☐ pT4a: Moderately advanced disease. Tumor involving deep soft tissue, cartilage, bone, or overlying skin
- ☐ pT4b: Very advanced disease. Tumor involving brain, dura, skull base, lower cranial nerves (IX, X, XI, XII), masticator space, carotid artery, prevertebral space, or mediastinal structures

Regional Lymph Nodes (pN)

- ☐ pNX: Regional lymph nodes cannot be assessed
- ☐ pN0: No regional lymph node metastases
- ☐ pN1: Regional lymph node metastases present

Distant Metastasis (pM)

- ☐ Not applicable
- ☐ pM1: Distant metastasis present
+ Specify site(s), if known: _____

+ Additional Pathologic Findings (select all that apply)

- + ☐ None identified
- + ☐ Keratinizing dysplasia (Note N)
- + ☐ Mild
- + ☐ Moderate
- + ☐ Severe (carcinoma in situ)
- + ☐ Nonkeratinizing dysplasia (Note N)
- + ☐ Mild
- + ☐ Moderate
- + ☐ Severe (carcinoma in situ)
- + ☐ Inflammation (specify type): _____
- + ☐ Epithelial hyperplasia
- + ☐ Colonization
- + ☐ Fungal
- + ☐ Bacterial
- + ☐ Other (specify): _____

+ Ancillary Studies (Note O)

- + Specify type(s): _____
- + Specify result(s): _____

+ Clinical History (select all that apply)

- + ☐ Neoadjuvant therapy
- + ☐ Yes (specify type): _____
- + ☐ No
- + ☐ Indeterminate
- + ☐ Other (specify): _____

+ Comment(s)

Explanatory Notes

Scope of Guidelines

The reporting of oral cancer including the lip is facilitated by the provision of a case summary illustrating the features required for comprehensive patient care. However, there are many cases in which the individual practicalities of applying such a case summary may not be straightforward. Common examples include finding the prescribed number of lymph nodes, trying to determine the levels of the radical neck dissection, and determining if isolated tumor cells in a lymph node represent metastatic disease. Case summaries have evolved to include clinical, radiographic, morphologic, immunohistochemical, and molecular results in an effort to guide clinical management. Adjuvant and neoadjuvant therapy can significantly alter histologic findings, making accurate classification an increasingly complex and demanding task. This protocol tries to remain simple while still incorporating important pathologic features as proposed by the American Joint Committee on Cancer (AJCC) cancer staging manual, the World Health Organization classification of tumors, the TNM classification, the American College of Surgeons Commission on Cancer, and the International Union on Cancer (UICC). This protocol is to be used as a guide and resource, an adjunct to diagnosing and managing cancers of the oral cavity in a standardized manner. It should not be used as a substitute for dissection or grossing techniques and does not give histologic parameters to reach the diagnosis. Subjectivity is always a factor, and elements listed are not meant to be arbitrary but are meant to provide uniformity of reporting across all the disciplines that use the information. It is a foundation of practical information that will help to meet the requirements of daily practice to benefit both clinicians and patients alike.

A. Anatomic Sites and Subsites for Lip and Oral Cavity (Figure 1)

Lip

- External upper lip (vermillion border)
- External lower lip (vermillion border)
- Commissures

Oral Cavity

- Buccal mucosa
 - Mucosa of upper and lower lips
 - Cheek mucosa
 - Retromolar areas
 - Bucco-alveolar sulci, upper and lower (vestibule of mouth)
- Upper alveolus and gingiva (upper gum)
- Lower alveolus and gingiva (lower gum)
- Hard palate
- Tongue
 - Dorsal surface and lateral borders anterior to circumvallate papillae (anterior two-thirds)
 - Inferior (ventral) surface
- Floor of mouth

The protocol applies to all carcinomas arising at these sites.¹

Mucosal Lip. The lip begins at the junction of the vermillion border with the skin and includes only the vermillion surface or that portion of the lip that comes in contact with the opposing lip. It is well defined into an upper and lower lip joined at the commissures of the mouth.

Buccal Mucosa (Inner Cheek). This includes all the membrane lining of the inner surface of the cheeks and lips from the line of contact of the opposing lips to the line of attachment of mucosa of the alveolar ridge (upper and lower) and pterygomandibular raphe.

Lower Alveolar Ridge. This refers to the mucosa overlying the alveolar process of the mandible, which extends from the line of attachment of mucosa in the buccal gutter to the line of free mucosa of the floor of the mouth. Posteriorly it extends to the ascending ramus of the mandible.

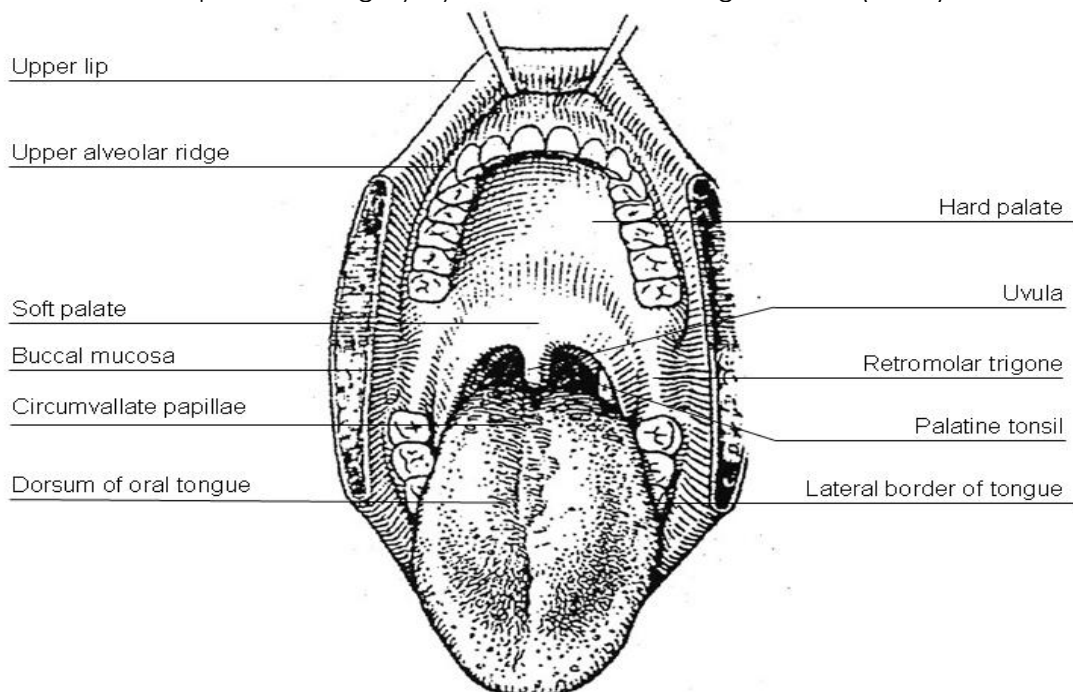
Upper Alveolar Ridge. This refers to the mucosa overlying the alveolar process of the maxilla, which extends from the line of attachment of mucosa in the upper gingival buccal gutter to the junction of the hard palate. Its posterior margin is the upper end of the pterygopalatine arch.

Retromolar Gingiva (Retromolar Trigone). This is the attached mucosa overlying the ascending ramus of the mandible from the level of the posterior surface of the last molar tooth and the apex superiorly, adjacent to the tuberosity of the maxilla.

Floor of the Mouth. This is a semilunar space over the myelohyoid and hypoglossus muscles, extending from the inner surface of the lower alveolar ridge to the undersurface of the tongue. Its posterior boundary is the base of the anterior pillar of the tonsil. It is divided into two sides of the submaxillary and sublingual salivary glands.

Hard Palate. This is the semilunar area between the upper alveolar ridge and the mucous membrane covering the palatine process of the maxillary palatine bones. It extends from the inner surface of the superior alveolar ridge to the posterior edge of the palatine bone.

Anterior Two-Thirds of the Tongue (Oral Tongue). This is the freely mobile portion of the tongue that extends anteriorly from the line of circumvallate papillae to the undersurface of the tongue at the junction of the floor of the mouth. It is composed of four areas: the tip, the lateral borders, the dorsum, and the undersurface (nonvillous ventral surface of the tongue). The undersurface of the tongue is considered a separate category by the World Health Organization (WHO).



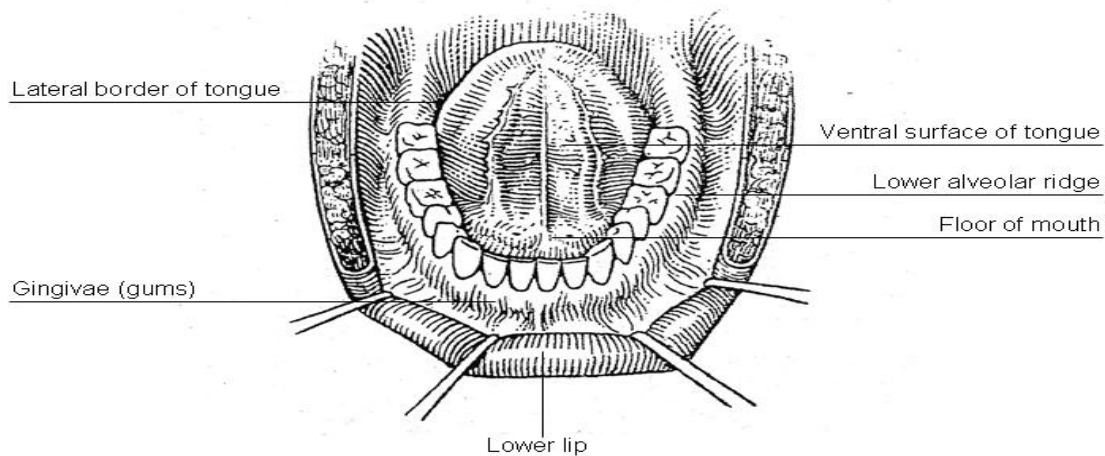
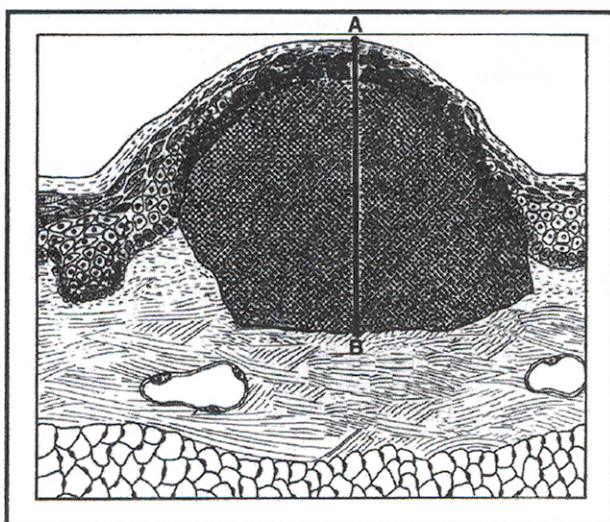


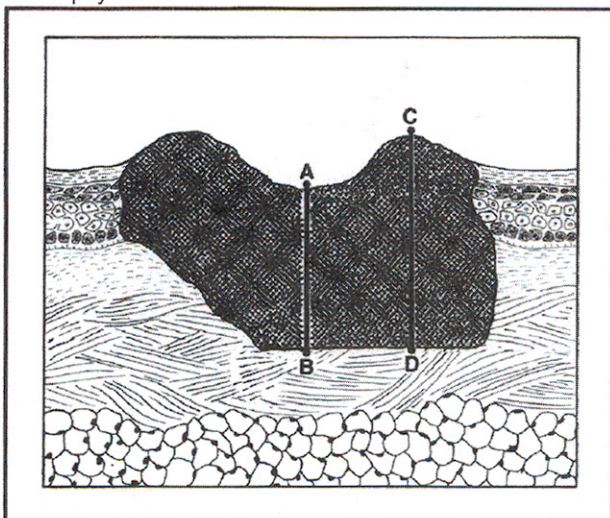
Figure 1. Diagrams illustrating the oral cavity anatomic subsites. Figure courtesy of Beth Israel Medical Center, St. Luke's and Roosevelt Hospitals, New York.

B. Tumor Thickness/Depth of Invasion

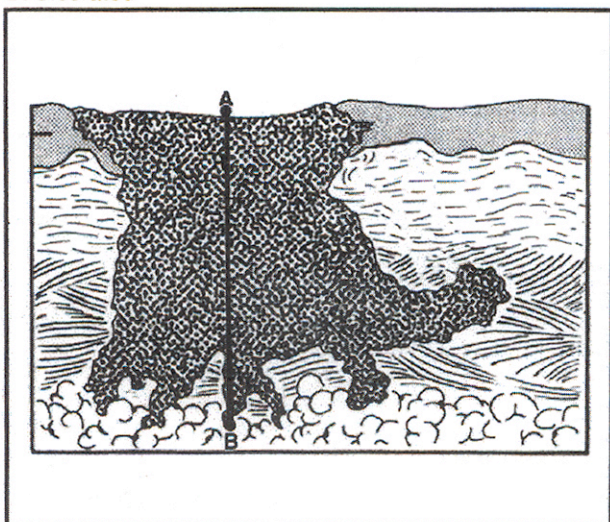
For small (T1, T2) oral squamous cell carcinomas, the microscopic measurement of tumor thickness is considered a valuable parameter for predicting regional nodal involvement and survival in oral cavity squamous cell carcinoma.² Measurement of tumor thickness has been controversial in the literature and there is no standard method for measuring. Submission of 3- to 4-mm consecutive sections through the lesion will facilitate locating the deepest point of invasion and maximum tumor dimension. Tumor thickness is usually measured from the mucosal surface of the tumor to the deepest point of tissue invasion in a perpendicular fashion with an optical micrometer. The dimension should be recorded in millimeters. In heavily keratinized lesions, measurement occurs from the surface of the tumor exclusive of the keratin layer; alternatively, measurement might more appropriately occur from the epithelial basement membrane. If the lesion is ulcerated, then measurement should be from the surface of the ulcer.³⁻⁶ to the deepest point of invasion (Figure 2). Gross examination of consecutive sections through the lesion and measuring tumor thickness from a histologic section with the least amount of tangential artifact should aid in accurately measuring tumor thickness.



A. Exophytic



B. Ulcerated



C Endophytic

Figure 2. Tumor thickness can be measured from an exophytic or heavily keratinized surface (A), ulcerated surface (B) or endophytic surface (C). Measurement occurs from the surface of the tumor exclusive of the keratin layer to the deepest point of invasion. From *AJCC Cancer Staging Manual*, 6th ed. New York: Springer; 2002. © American Joint Committee on Cancer. Reproduced with permission.

C. Histological Type

A modification of the World Health Organization (WHO) classification of carcinomas of the oral cavity including the lip is shown below.⁷ This list may not be complete. This protocol applies only to carcinomas and melanomas but does not apply to lymphomas or sarcomas.

Carcinomas of the Oral Cavity

Squamous cell carcinoma, conventional

Squamous cell carcinoma, variant

 Acantholytic squamous cell carcinoma

 Adenosquamous carcinoma

 Basaloid squamous cell carcinoma

 Carcinoma cuniculatum

 Papillary squamous cell carcinoma

 Spindle cell squamous carcinoma

 Verrucous carcinoma

Lymphoepithelial carcinoma (non-nasopharyngeal)

Carcinomas of Minor Salivary Glands

Acinic cell carcinoma

Adenoid cystic carcinoma

Adenocarcinoma, not otherwise specified (NOS)

Basal cell adenocarcinoma

Carcinoma ex pleomorphic adenoma (malignant mixed tumor)

Carcinoma, type cannot be determined

Carcinosarcoma

Clear cell carcinoma, NOS

Cystadenocarcinoma

Epithelial-myoepithelial carcinoma

Mucoepidermoid carcinoma,

Mucinous adenocarcinoma (colloid carcinoma)

Myoepithelial carcinoma (malignant myoepithelioma)

Oncocytic carcinoma

Polymorphous low-grade adenocarcinoma

Salivary duct carcinoma

Adenocarcinoma, Non-salivary Gland Type

Papillary adenocarcinoma

Intestinal-type adenocarcinoma

Adenocarcinoma, not otherwise specified (NOS)

 Low grade

 Intermediate grade

 High grade

Neuroendocrine Carcinoma[#]

Typical carcinoid tumor (well differentiated neuroendocrine carcinoma)

Atypical carcinoid tumor (moderately differentiated neuroendocrine carcinoma)

Large cell carcinoma, neuroendocrine type (poorly differentiated neuroendocrine carcinoma)

Small cell carcinoma, neuroendocrine type (poorly differentiated neuroendocrine carcinoma)

Combined (or composite) small cell carcinoma, neuroendocrine type^{##}

Mucosal Melanoma

Not included in WHO Classification.

Represents a carcinoma showing combined features of small cell neuroendocrine carcinoma associated with a squamous or adenocarcinomatous component.⁷

D. Histologic Grade

For histologic types of carcinomas that are amenable to grading, 3 histologic grades are suggested, as shown below. For conventional squamous cell carcinoma, histologic grading as a whole does not perform well as a prognosticator.⁷ Nonetheless, it should be recorded when applicable, as it is a basic tumor characteristic. Selecting either the most prevalent grade or the highest grade for this synoptic protocol is acceptable. Variants of squamous cell carcinoma (ie, verrucous, basaloid, etc) have an intrinsic biologic potential and currently do not appear to require grading.

| | |
|---------|---------------------------|
| Grade 1 | Well differentiated |
| Grade 2 | Moderately differentiated |
| Grade 3 | Poorly differentiated |
| Grade X | Cannot be assessed |

The histologic (microscopic) grading of salivary gland carcinomas has been shown to be an independent predictor of behavior and plays a role in optimizing therapy.⁸⁻¹³ Further, there is often a positive correlation between histologic grade and clinical stage. Most salivary carcinomas have a biologic behavior defined by their categorization and do not require grading.¹³ The 3 major categories that are amenable to grading include adenoid cystic carcinoma, mucoepidermoid carcinoma (the 2 most frequent histologic types seen in larynx), and adenocarcinoma, not otherwise specified.^{8,10,14}

Generally, 3 histologic grades are suggested, as follows:

| | |
|---------|--|
| Grade 1 | Well differentiated = Low-grade |
| Grade 2 | Moderately differentiated = Intermediate-grade |
| Grade 3 | Poorly differentiated = High-grade |
| Grade X | Cannot be assessed |

In some carcinomas, histologic grading may be based on growth pattern, such as in adenoid cystic carcinoma, for which a histologic high-grade variant has been recognized based on the percentage of solid growth.¹⁰ Those adenoid cystic carcinomas showing 30% or greater of solid growth pattern are considered to be histologically high-grade carcinomas. The histologic grading of mucoepidermoid carcinoma includes a combination of growth pattern characteristics (eg, cystic, solid, neurotropism) and cytomorphologic findings (eg, anaplasia, mitoses, necrosis).¹⁵⁻¹⁷ Adenocarcinomas, not otherwise specified, do not have a formalized grading scheme and are graded intuitively, based on cytomorphologic features.¹³

Carcinoma ex pleomorphic adenoma is subclassified by histologic grade (low grade and high grade) and extent of invasion, the latter including minimally invasive, invasive and noninvasive cancers. Minimally invasive cancers measure less than or equal to 1.5 mm with penetration of the malignant component into extracapsular tissue; invasive carcinomas measure more than 1.5 mm of invasion; noninvasive cancers are completely confined to within the capsule without evidence of penetration into extracapsular tissue. Prior to diagnosing a noninvasive carcinoma ex pleomorphic adenoma, sectioning of the entire lesion for histologic evaluation is recommended in order to exclude the presence of invasive growth. Prognosis has been linked to degree of invasion with noninvasive and minimally invasive cancers apparently having a better prognosis than invasive cancers.^{13,18}

E. Surgical Margins

The definition of a positive margin is somewhat controversial given the varied results from prior studies.^{19,20} However, overall, several studies support the definition of a positive margin to be invasive carcinoma *or* carcinoma in situ/ high-grade dysplasia present at margins (microscopic cut-through of tumor).¹⁹ Furthermore, reporting of surgical margins should also include information regarding the distance of invasive carcinoma, carcinoma in situ, or high-grade dysplasia (moderate to severe) from the surgical margin. Tumors with "close" margins also carry an increased risk for local recurrence.^{19,21} The definition of a "close" margin is not standardized as the effective cut-off varies between studies and between anatomic subsites. Commonly used cut points to define close margins are 5 mm in general, and 2 mm with respect to glottis larynx.¹⁹ However, values ranging from 3 mm to 7 mm have been used with success,^{19,23} and for glottic tumors as low as 1 mm.²⁴ Thus distance of tumor from the nearest margin should be recorded.

Reporting of surgical margins for carcinomas of the minor salivary glands should follow those used for squamous cell carcinoma of oral cavity.

Keratinizing Dysplasia

The types of intraepithelial dysplasia of the upper aerodigestive tract (UADT) include nonkeratinizing ("classic") dysplasia and keratinizing dysplasia. Of the two types of dysplasias, the keratinizing dysplasias are significantly more common than the nonkeratinizing dysplasias. For both types of UADT intraepithelial dysplasias, grading includes mild, moderate, and severe forms, with the latter category being synonymous with carcinoma in situ. It must be noted that in the setting of keratinizing dysplasia, full thickness dysplasia of the surface epithelium, representing the histologic definition for carcinoma in situ, is an uncommon occurrence. Nevertheless, there are keratinizing dysplasias that lack full thickness dysplasia and yet carry a significant risk to develop invasive carcinoma. Due to the fact that invasive carcinoma can develop from keratinizing dysplasia in which there is an absence of full thickness dysplasia, the grading of UADT dysplasias is problematic and lacks reproducibility among pathologists (see below under Note M). Since there is no significant statistical difference in the risk to invasive carcinoma between the category of keratinizing moderate dysplasia and keratinizing severe dysplasia,²⁵ the suggestion has been entertained of adopting a Bethesda-like classification to keratinizing dysplasias of the UADT, including a low-grade category limited to keratinizing mild dysplasia and a high-grade category to include keratinizing moderate and severe dysplasias.²⁶ As such, it must be recognized that keratinizing severe dysplasia, even if not "full thickness," should for all intents and purposes be dealt with in a similar manner as classically defined carcinoma in situ so that in evaluating surgical margins for the presence or absence of dysplasia/carcinoma in situ, keratinizing moderate and severe dysplasias should be viewed as a single category relative to risk of progression to invasive carcinoma. Such a risk does not include keratinizing mild dysplasia. In summary, the presence of keratinizing mild dysplasia at (or near) a surgical margin should not be viewed/reported as a positive margin, whereas the presence of keratinizing moderate or severe dysplasia at (or near) a surgical margin should be viewed/reported as a positive margin.

F. Orientation of Specimen

Complex specimens should be examined and oriented with the assistance of the operating surgeon(s). Direct communication between the surgeon and pathologist is a critical component in specimen orientation and proper sectioning. Whenever possible, the tissue examination request form should include a drawing or photograph of the resected specimen showing the extent of the tumor and its relation to the anatomic structures of the region. The lines and extent of the resection can be depicted on preprinted adhesive labels and attached to the surgical pathology request forms.

G. Perineural Invasion

Traditionally, the presence of perineural invasion (neurotropism) is an important predictor of poor prognosis in head and neck cancer of virtually all sites.²⁷ The presence of perineural invasion

(neurotropism) in the primary cancer is associated with poor local disease control and regional control, as well as being associated with metastasis to regional lymph nodes.²⁷ Further, perineural invasion is associated with decrease in disease-specific survival and overall survival.²⁷ There is conflicting data relative to an association between the presence of perineural invasion and the development of distant metastasis, with some studies showing an increased association with distant metastasis, while other studies showing no correlation with distant metastasis.²⁷ The relationship between perineural invasion and prognosis is independent of nerve diameter.²⁸ Additionally, emerging evidence suggests that extratumoral perineural invasion may be more prognostically relevant.²⁹ Although perineural invasion of small unnamed nerves may not produce clinical symptoms, the reporting of perineural invasion includes nerves of all sizes including small peripheral nerves (ie, less than 1 mm in diameter). Aside from the impact on prognosis, the presence of perineural invasion also guides therapy. Concurrent adjuvant chemoradiation therapy has been shown to improve outcomes in patients with perineural invasion (as well as in patients with extranodal extension and bone invasion).^{30,31} Given the significance relative to prognosis and treatment, perineural invasion is a required data element in the reporting of head and neck cancers.

H. Extranodal Extension

The status of cervical lymph nodes is the single most important prognostic factor in aerodigestive cancer. All macroscopically negative or equivocal lymph nodes should be submitted in toto. Grossly positive nodes may be partially submitted for microscopic documentation of metastasis. Reporting of lymph nodes containing metastasis should include whether there is presence or absence of extranodal extension (EE). This finding consists of extension of metastatic tumor, present within the confines of the lymph node, through the lymph node capsule into the surrounding connective tissue, with or without associated stromal reaction. A distance of extension from the native lymph node capsule is optional and has not yet been shown to have a definitive impact on prognosis or treatment for head and neck subsites. If macroscopic examination suggests EE, this tissue should be submitted for microscopic confirmation. EE is a predictor of regional relapse and a criterion for postoperative radiotherapy.³²⁻³⁵

I. TNM and Stage Groupings

The protocol recommends the TNM staging system of the American Joint Committee on Cancer (AJCC) and the International Union Against Cancer (UICC) for lip and oral cavity cancer.^{1,36} Of note in the 7th edition of the AJCC staging of head and neck cancers¹ is the division of T4 lesions into T4a (moderately advanced local disease) and T4b (very advanced local disease), leading to the stratification of stage IV into stage IVA (moderately advanced local/regional disease), stage IVB (very advanced local/regional disease), and stage IVC (distant metastatic disease).

The 7th edition of the AJCC staging of head and neck cancers includes mucosal melanomas.¹ Approximately two-thirds of mucosal melanomas arise in the sinonasal tract, one quarter are found in the oral cavity and the remainder occur only sporadically in other mucosal sites of the head and neck.¹ Even small cancers behave aggressively with high rates of recurrence and death.¹ To reflect this aggressive behavior, primary cancers limited to the mucosa are considered T3 lesions. Advanced mucosal melanomas are classified as T4a and T4b. The anatomic extent criteria to define *moderately advanced* (T4a) and *very advanced* (T4b) disease are given below. The AJCC staging for mucosal melanomas does not provide for the histologic definition of a T3 lesion; as the majority of mucosal melanomas are invasive at presentation, mucosal based melanomas (T3 lesions) include those lesions that involve either the epithelium and/or lamina propria of the involved site. Rare examples of in situ mucosal melanomas occur, but In situ mucosal melanomas are excluded from staging, as they are extremely rare.¹

Carcinomas of minor salivary glands of the upper aerodigestive tract site, including the oral cavity, are staged according to schemes corresponding to the anatomic site of occurrence. A proposed staging

system for rare salivary gland cancers that occur within gnathic bone (eg, mandible) is based on the status of the overlying bone³⁷ including:

Stage I – intact overlying cortex with no evidence of bony expansion;

Stage II - intact overlying cortex with some degree of bony expansion;

Stage III – perforation of the cortex or metastatic spread.

For All Carcinomas Excluding Mucosal Melanoma

Primary Tumor

| | |
|-----|---|
| TX | Cannot be assessed |
| T0 | No evidence of primary tumor |
| Tis | Carcinoma in situ |
| T1 | Tumor 2 cm or less in greatest dimension |
| T2 | Tumor more than 2 cm but not more than 4 cm in greatest dimension |
| T3 | Tumor more than 4 cm in greatest dimension |
| T4a | Moderately advanced local disease. Lip: Tumor invades through cortical bone, inferior alveolar nerve, floor of mouth, or skin of face, ie, chin or nose Oral cavity: Tumor invades adjacent structures (eg, through cortical bone [mandible, maxilla], into deep [extrinsic] muscle of tongue [genioglossus, hyoglossus, palatoglossus, and styloglossus], maxillary sinus, skin of face) |
| T4b | Very advanced local disease. Tumor invades masticator space, pterygoid plates, or skull base, and/or encases internal carotid artery |

Regional Lymph Nodes[#]

| | |
|-----|--|
| NX | Cannot be assessed |
| N0 | No regional lymph node metastasis |
| N1 | Metastasis in a single ipsilateral lymph node, 3 cm or less in greatest dimension |
| N2a | Metastasis in a single ipsilateral lymph node, more than 3 cm but not more than 6 cm in greatest dimension |
| N2b | Metastasis in multiple ipsilateral lymph nodes, none more than 6 cm in greatest dimension |
| N2c | Metastasis in bilateral or contralateral lymph nodes, none more than 6 cm in greatest dimension |
| N3 | Metastasis in a lymph node more than 6 cm in greatest dimension |

[#]Superior mediastinal lymph nodes are considered regional lymph nodes (level VII).

Midline nodes are considered ipsilateral nodes.

Distant Metastasis

| | |
|----|-----------------------|
| M0 | No distant metastasis |
| M1 | Distant metastasis |

For Mucosal Melanoma

Primary Tumor

| | |
|-----|---|
| T3 | Mucosal disease |
| T4a | Moderately advanced disease. Tumor involving deep soft tissue, cartilage, bone, or overlying skin. |
| T4b | Very advanced disease. Tumor involving brain, dura, skull base, lower cranial nerves (IX, X, XI, XII), masticator space, carotid artery, prevertebral space, or mediastinal structures. |

Regional Lymph Nodes

| | |
|----|---|
| NX | Regional lymph nodes cannot be assessed |
| N0 | No regional lymph node metastases |
| N1 | Regional lymph node metastases present |

Distant Metastasis

| | |
|----|-----------------------|
| M0 | No distant metastasis |
| M1 | Distant metastasis |

By AJCC/UICC convention, the designation "T" refers to a primary tumor that has not been previously treated. The symbol "p" refers to the pathologic classification of the TNM, as opposed to the clinical classification, and is based on gross and microscopic examination. pT entails a resection of the primary tumor or biopsy adequate to evaluate the highest pT category, pN entails removal of nodes adequate to validate lymph node metastasis, and pM implies microscopic examination of distant lesions. Clinical classification (cTNM) is usually carried out by the referring physician before treatment during initial evaluation of the patient or when pathologic classification is not possible.

Pathologic staging is usually performed after surgical resection of the primary tumor. Pathologic staging depends on pathologic documentation of the anatomic extent of disease, whether or not the primary tumor has been completely removed. If a biopsied tumor is not resected for any reason (eg, when technically unfeasible) and if the highest T and N categories or the M1 category of the tumor can be confirmed microscopically, the criteria for pathologic classification and staging have been satisfied without total removal of the primary cancer.

T Category Considerations

Superficial erosion alone of bone/tooth socket by primary gingival tumor is not sufficient to classify a tumor as T4.

Stage Groupings – For All Cancers Except Mucosal Melanoma

| | | | |
|-----------|----------|----------|----|
| Stage 0 | Tis | N0 | M0 |
| Stage I | T1 | N0 | M0 |
| Stage II | T2 | N0 | M0 |
| Stage III | T1,T2 | N1 | M0 |
| | T3 | N0,N1 | M0 |
| Stage IVA | T1,T2,T3 | N2 | M0 |
| | T4a | N0,N1,N2 | M0 |
| Stage IVB | Any T | N3 | M0 |
| | T4b | Any N | M0 |
| Stage IVC | Any T | Any N | M1 |

Stage Groupings – For Mucosal Melanoma

| | | | |
|-----------|--------|-------|----|
| Stage III | T3 | N0 | M0 |
| Stage IVA | T4a | N0 | M0 |
| | T3-T4a | N1 | M0 |
| Stage IVB | T4b | Any N | M0 |
| Stage IVC | Any T | Any N | M1 |

TNM Descriptors

For identification of special cases of TNM or pTNM classifications, the "m" suffix and "y" and "r" prefixes are used. Although they do not affect the stage grouping, they indicate cases needing separate analysis.

The “m” suffix indicates the presence of multiple primary tumors in a single site and is recorded in parentheses: pT(m)NM.

The “y” prefix indicates those cases in which classification is performed during or following initial multimodality therapy (ie, neoadjuvant chemotherapy, radiation therapy, or both chemotherapy and radiation therapy). The cTNM or pTNM category is identified by a “y” prefix. The ycTNM or ypTNM categorizes the extent of tumor actually present at the time of that examination. The “y” categorization is not an estimate of tumor prior to multimodality therapy (ie, before initiation of neoadjuvant therapy).

The “r” prefix indicates a recurrent tumor when staged after a documented disease-free interval, and is identified by the “r” prefix: rTNM.

Additional Descriptors

Residual Tumor (R)

Tumor remaining in a patient after therapy with curative intent (eg, surgical resection for cure) is categorized by a system known as R classification, shown below.

| | |
|----|---|
| RX | Presence of residual tumor cannot be assessed |
| R0 | No residual tumor |
| R1 | Microscopic residual tumor |
| R2 | Macroscopic residual tumor |

For the surgeon, the R classification may be useful to indicate the known or assumed status of the completeness of a surgical excision. For the pathologist, the R classification is relevant to the status of the margins of a surgical resection specimen. That is, tumor involving the resection margin on pathologic examination may be assumed to correspond to residual tumor in the patient and may be classified as macroscopic or microscopic according to the findings at the specimen margin(s).

J. Classification of Neck Dissection

1. Radical neck dissection
2. Modified radical neck dissection, internal jugular vein and/or sternocleidomastoid muscle spared
3. Selective neck dissection (SND), as specified by the surgeon (Figure 3), defined by dissection of less than the 5 traditional levels of a radical and modified radical neck dissection. The following dissections are now under this category³⁸⁻⁴⁰:
 - a. Supraomohyoid neck dissection
 - b. Posterolateral neck dissection
 - c. Lateral neck dissection
 - d. Central compartment neck dissection
4. Superselective neck dissection (SSND), a relatively new term defined by dissection of the fibrofatty elements of 2 or less levels.⁴¹
5. Extended radical neck dissection, as specified by the surgeon

K. Regional Lymph Nodes (pN0): Isolated Tumor Cells

Isolated tumor cells (ITCs) are single cells or small clusters of cells not more than 0.2 mm in greatest dimension. While the generic recommendation is that for lymph nodes with ITCs found by either histologic examination, immunohistochemistry, or non-morphologic techniques (eg, flow cytometry, DNA analysis, polymerase chain reaction [PCR] amplification of a specific tumor marker) they should be classified as N0 or M0, respectively,^{36,42} evidence for the validity of this practice in head and neck squamous cell carcinoma and other histologic subtypes is lacking. In fact, rare studies relevant to head and neck sites indicate that isolated tumor cells may actually be a poor prognosticator in terms of local control.⁴³

For purposes of pathologic evaluation, lymph nodes are organized by levels as shown in Figure 3.

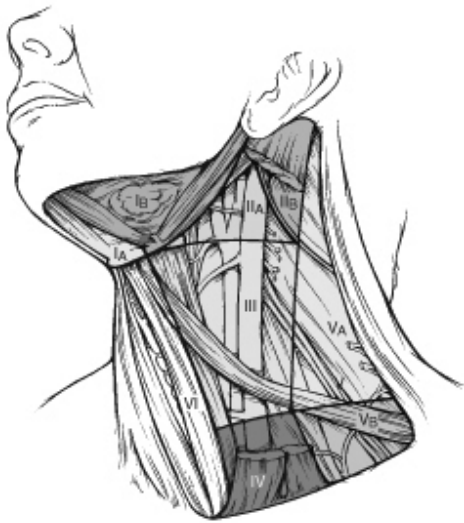

Figure 3. The six sublevels of the neck for describing the location of lymph nodes within levels I, II, and V. Level IA, submental group; level IB, submandibular group; level IIA, upper jugular nodes along the carotid sheath, including the subdigastric group; level IIB, upper jugular nodes in the submuscular recess; level VA, spinal accessory nodes; and level VB, the supraclavicular and transverse cervical nodes. From: Flint PW, et al, eds. *Cummings Otolaryngology: Head and Neck Surgery*. 5th ed. Philadelphia, PA; Saunders: 2010. Reproduced with permission © Elsevier.

In order for pathologists to properly identify these nodes, they must be familiar with the terminology of the regional lymph node groups and with the relationships of those groups to the regional anatomy. Which lymph node groups surgeons submit for histopathologic evaluation depends on the type of neck dissection they perform. Therefore, surgeons must supply information on the types of neck dissections that they perform and on the details of the local anatomy in the specimens they submit for examination or, in other manners, orient those specimens for pathologists.

If it is not possible to assess the levels of lymph nodes (for instance, when the anatomic landmarks in the excised specimens are not specified), then the lymph node levels may be estimated as follows: level II, upper third of internal jugular (IJ) vein or neck specimen; level III, middle third of IJ vein or neck specimen; level IV, lower third of IJ vein or neck specimen, all anterior to the sternocleidomastoid muscle.

Level I. Submental Group (Sublevel IA)

Lymph nodes within the triangular boundary of the anterior belly of the digastric muscles and the hyoid bone.

Level I. Submandibular Group (Sublevel IB)

Lymph nodes within the boundaries of the anterior and posterior bellies of the digastric muscle and the body of the mandible. The submandibular gland is included in the specimen when the lymph nodes within this triangle are removed.

Level II. Upper Jugular Group (Sublevels IIA and IIB)

Lymph nodes located around the upper third of the internal jugular vein and adjacent spinal accessory nerve extending from the level of the carotid bifurcation (surgical landmark) or hyoid bone (clinical

landmark) to the skull base. The posterior boundary is the posterior border of the sternocleidomastoid muscle, and the anterior boundary is the lateral border of the stylohyoid muscle.

Level III. Middle Jugular Group

Lymph nodes located around the middle third of the internal jugular vein extending from the carotid bifurcation superiorly to the omohyoid muscle (surgical landmark), or cricothyroid notch (clinical landmark) inferiorly. The posterior boundary is the posterior border of the sternocleidomastoid muscle, and the anterior boundary is the lateral border of the sternohyoid muscle.

Level IV. Lower Jugular Group

Lymph nodes located around the lower third of the internal jugular vein extending from the omohyoid muscle superiorly to the clavicle inferiorly. The posterior boundary is the posterior border of the sternocleidomastoid muscle, and the anterior boundary is the lateral border of the sternohyoid muscle.

Level V. Posterior Triangle Group (Sublevels VA and VB)

This group comprises predominantly the lymph nodes located along the lower half of the spinal accessory nerve and the transverse cervical artery. The supraclavicular nodes are also included in this group. The posterior boundary of the posterior triangle is the anterior border of the trapezius muscle, the anterior boundary of the posterior triangle is the posterior border of the sternocleidomastoid muscle, and the inferior boundary of the posterior triangle is the clavicle.

Level VI. Anterior (Central) Compartment

Lymph nodes in this compartment include the pre- and paratracheal nodes, precricoid (Delphian) node, and the perithyroidal nodes, including the lymph nodes along the recurrent laryngeal nerve. The superior boundary is the hyoid bone, the inferior boundary is the suprasternal notch, the lateral boundaries are the common carotid arteries, and the posterior boundary by the prevertebral fascia.

Level VII. Superior Mediastinal Lymph Nodes

Metastases at level VII are considered regional lymph node metastases; all other mediastinal lymph node metastases are considered distant metastases.

Lymph node groups removed from areas not included in the above levels, eg, scalene, suboccipital, and retropharyngeal, should be identified and reported from all levels separately. Midline nodes are considered ipsilateral nodes.

L. Lymph Nodes

Lymph Node Number

Histological examination of a selective neck dissection specimen will ordinarily include 6 or more lymph nodes. Histological examination of a radical or modified radical neck dissection specimen will ordinarily include 10 or more lymph nodes in the untreated neck.

Measurement of Tumor Metastasis

The cross-sectional diameter of the largest lymph node metastasis (not the lymph node itself) is measured in the gross specimen at the time of macroscopic examination or, if necessary, on the histologic slide at the time of microscopic examination.^{27,38}

M. Special Procedures for Lymph Nodes

At the current time, no additional special techniques are required other than routine histology for the assessment of nodal metastases. Immunohistochemistry and polymerase chain reaction (PCR) to detect isolated tumor cells are considered investigational techniques at this time.

N. Dysplasia of the Upper Aerodigestive Tract (UADT)

In contrast to the uterine cervix in which the nonkeratinizing ("classic") form of epithelial dysplasia most commonly results in a reproducible and clinically useful grading scheme of mild, moderate, and severe dysplasia (ie, carcinoma in situ), the majority of the UADT mucosal lesions fall under the designation of keratinizing dysplasias. The criteria for evaluating keratinizing dysplasias are less well defined, and the diagnosis of severe keratinizing (intraepithelial) dysplasia remains controversial. In particular, the definition of severe dysplasia in the setting of keratosis is broader than the highly reproducible pattern seen in the uterine cervix and includes a microscopically heterogeneous group of lesions. In the setting of keratinizing dysplasia where surface maturation is retained with only partial replacement of the epithelium by atypical cells, severe dysplasia includes those lesions in which the epithelial alterations are so severe that there would be a high probability for the progression to an invasive carcinoma if left untreated. The evaluation of keratinizing dysplasia includes cellular abnormalities (ie, cytomorphology) and maturation abnormalities (ie, architectural alterations). At present, the preferred grading for keratinizing dysplasias of the UADT include mild, moderate, and severe dysplasia depending on the degree and extent of cellular and maturation alterations that are present.⁴⁴ Using the definition of carcinoma in situ (CIS) as applied to the uterine cervix requires loss of maturation of squamous epithelium; therefore, by this definition most keratotic lesion would not be classified as CIS because keratinization would represent a type of maturation. Therefore, the use of the specific term CIS in keratinizing dysplasias of the UADT has been questioned and is likely inappropriate in this setting; a more appropriate designation is keratinizing severe dysplasia.

Several points should be stressed relative to keratinizing dysplasia of the UADT:

- Invasive carcinoma can develop from keratinizing dysplasia that is limited in extent and in the absence of full thickness dysplasia (ie, "classic" carcinoma in situ) progression can occur even in the setting of lesions with atypia limited to the lower third (basal zone region) of the surface epithelium.
- Keratinizing severe dysplasia is often multifocal and frequently occurs adjacent to or near synchronous foci of invasive carcinoma.
- Keratinizing severe dysplasia has a rate of progression to invasive carcinoma that is greater than that of "classic" carcinoma in situ.
- A diagnosis of severe dysplasia requires therapeutic intervention, as well as clinical evaluation of the entire upper aerodigestive tract to exclude the possible presence of additional foci of dysplasia or carcinoma that may exist from field effect.

The end point for the grading of dysplasia is to convey to the clinician what is the potential biologic behavior of a given epithelial lesion. Relative to the oral cavity, clinical lesions include leukoplakia (white mucosal) lesions and erythroplakia (red mucosal) lesions. Leukoplakic lesions can be divided into homogenous (thick white lesion with smooth appearance) and nonhomogenous (thickened leukoplakia with irregular appearing surface). The clinical diagnosis of leukoplakia is not necessarily an indicator and does not necessarily correlate with histopathologic confirmation of an underlying dysplasia. The precancerous potential of leukoplakia is predicated on the fact that keratosis is associated with an increase risk of malignant transformation as compared to non-keratotic oral lesions, and that keratosis is present in a significant percentage (greater than one-third of cases) of oral carcinomas.²⁶ There is a correlation between the site of leukoplakia and the incidence of an associated dysplasia; the greatest frequency of epithelial dysplasia is found in leukoplakic lesions of the floor of mouth, tongue (lateral and ventral), and vermilion border of the lip. The incidence of malignant transformation for homogeneous leukoplakia is 3% and for non-homogeneous leukoplakia is 15%.⁴⁵

In contrast to leukoplakia, the presence of erythroplakia is thought to correlate with a higher incidence of significant dysplasia (ie, moderate to severe dysplasia) and of carcinomas. Despite this association, not all erythroplakic lesions herald dysplasia/carcinoma; a subset will be attributed to inflammatory etiologies. Oral erythroplakia occurs most commonly on the floor of the mouth, tongue (lateral and ventral), soft palate, tonsillar region, and retromolar region. Given the clinical appearance of

erythroplakia, the surface epithelium is usually devoid of keratinization, and therefore these epithelial dysplasias are usually of the nonkeratinizing ("classical") type.²⁶ In erythroplakic lesions, invasive carcinoma is present in 50% of cases, carcinoma in situ in 40%, and mild to moderate dysplasia in 10%.⁴⁵

O. Ancillary Testing

It is now well established that human papillomavirus (HPV) plays a pathogenic role in a subset of head and neck cancers, termed HPV-associated head and neck squamous cell carcinoma (HPV-HNSCC).^{46,47} HPV, in particular the high risk type 16 (HPV-16), is present in most oropharyngeal carcinomas.⁴⁶ These carcinomas arise predominantly from the palatine tonsil and lingual tonsils of the oropharynx (ie, tonsil or base of tongue) and are nonkeratinizing carcinomas characterized by a somewhat basaloid morphology recapitulating tonsillar crypt epithelium (not to be confused with the specific variant basaloid squamous cell carcinoma).⁴⁸ A similar association has been suggested but not confirmed for oral cavity carcinoma. To date, there are no data linking HPV with laryngeal carcinoma, and the utility of testing for the presence of HPV in laryngeal carcinomas is unproven.

References

1. Patel S, Shah JP. Lip and oral cavity. In: Edge SB, Byrd DR, Carducci MA, Compton CA, eds. *AJCC Cancer Staging Manual*. New York: Springer; 2009:29-40.
2. Pentenero M, Navone R, Motta F, et al. Clinical features of microinvasive stage I oral carcinoma. *Oral Dis*. 2011;17(3):298-303.
3. Moore C, Kuhns JG, Greenberg RA. Thickness as prognostic aid in upper aerodigestive tract cancer. *Arch Surg*. 1986;121(12):1410-1414.
4. Pentenero M, Gandolfo S, Carrozzo M. Importance of tumor thickness and depth of invasion in nodal involvement and prognosis of oral squamous cell carcinoma: a review of the literature. *Head Neck*. 2005;27(12):1080-1091.
5. Woolgar JA. Histopathological prognosticators in oral and oropharyngeal squamous cell carcinoma. *Oral Oncol*. 2006;42(3):229-239.
6. Gonzalez-Moles MA, Esteban F, Rodriguez-Archilla A, Ruiz-Avila I, Gonzalez-Moles S. Importance of tumour thickness measurement in prognosis of tongue cancer. *Oral Oncol*. 2002;38(4):394-397.
7. Barnes L, Eveson JW, Reichart P, Sidransky D. WHO histological classification of tumours of the oral cavity and oropharynx. In: Barnes L, Eveson JW, Reichart P, Sidransky D, eds. *Pathology and Genetics of Head and Neck Tumours*. Lyon, France: IARC Press; 2005:164. *World Health Organization Classification of Tumours*.
8. Ellis GL, Auclair PL, eds. *Tumors of the Salivary Glands*. Silver Spring, MD: ARP Press; 2008. *AFIP Atlas of Tumor Pathology*. Series 4, Vol. 9.
9. Spiro RH, Huvos AG, Strong EW. Adenocarcinoma of salivary origin: clinicopathologic study of 204 patients. *Am J Surg*. 1982;144(4):423-431.
10. Szanto PA, Luna MA, Tortoledo ME, White RA. Histologic grading of adenoid cystic carcinoma of the salivary glands. *Cancer*. 1984;54(6):1062-1069.
11. Spiro RH, Thaler HT, Hicks WF, Kher UA, Huvos AH, Strong EW. The importance of clinical staging of minor salivary gland carcinoma. *Am J Surg*. 1991;162(4):330-336.
12. Kane WJ, McCaffrey TV, Olsen KD, Lewis JE. Primary parotid malignancies: a clinical and pathologic review. *Arch Otolaryngol Head Neck Surg*. 1991;117(3):307-315.
13. Seethala RR. Histologic grading and prognostic biomarkers in salivary gland carcinomas. *Adv Anat Pathol*. 2011;18(1):29-45.
14. Grimm EE, Rulyak SJ, Sekijima JH, Yeh MM. Canalicular adenoma arising in the esophagus. *Arch Pathol Lab Med*. 2007;131(10):1595-1597.
15. Auclair PL, Goode RK, Ellis GL. Mucoepidermoid carcinoma of intraoral salivary glands: evaluation and application of grading criteria in 143 cases. *Cancer*. 1992;69(8):2021-2030.
16. Brandwein MS, Ivanov K, Wallace DI, et al. Mucoepidermoid carcinoma: a clinicopathologic study of 80 patients with special reference to histological grading. *Am J Surg Pathol*. 2001;25(7):835-845.

17. Seethala RR, Dacic S, Cieply K, Kelly LM, Nikiforova MN. A reappraisal of the MECT1/MAML2 translocation in salivary mucoepidermoid carcinomas. *Am J Surg Pathol*. 2010;34(8):1106-1121.
18. Brandwein M, Huvos AG, Dardick I, Thomas MJ, Theise ND. Noninvasive and minimally invasive carcinoma ex mixed tumor: a clinicopathologic and ploidy study of 12 patients with major salivary tumors of low (or no?) malignant potential. *Oral Surg Oral Med Oral Pathol Oral Radiol Endod*. 1996;81(6):655-664.
19. Hinni ML, Ferlito A, Brandwein-Gensler MS, et al. Surgical margins in head and neck cancer: a contemporary review. *Head Neck*. 2012 Sep 3. [Epub ahead of print]
20. Brandwein-Gensler M, Teixeira MS, Lewis CM, et al. Oral squamous cell carcinoma: histologic risk assessment, but not margin status, is strongly predictive of local disease-free and overall survival. *Am J Surg Pathol*. 2005;29(2):167-178.
21. Alicandri-Ciufelli M, Bonali M, Piccinini A, et al. Surgical margins in head and neck squamous cell carcinoma: what is 'close'? *Eur Arch Otorhinolaryngol*. 2012 Dec 28. [Epub ahead of print]
22. Bradley PJ, MacLennan K, Brakenhoff RH, Leemans CR. Status of primary tumour surgical margins in squamous head and neck cancer: prognostic implications. *Curr Opin Otolaryngol Head Neck Surg*. 2007;15(2):74-81.
23. Liao CT, Chang JT, Wang HM, et al. Analysis of risk factors of predictive local tumor control in oral cavity cancer. *Ann Surg Oncol*. 2008;15(3):915-922.
24. Ansarin M, Santoro L, Cattaneo A, et al. Laser surgery for early glottic cancer: impact of margin status on local control and organ preservation. *Arch Otolaryngol Head Neck Surg*. 2009;135(4):385-390.
25. Barnes L. Disease of the larynx, hypopharynx and trachea. In: Barnes L, ed. *Surgical Pathology of the Head and Neck*. New York: Informa Healthcare; 2009:109-201.
26. Wenig BM. Squamous cell carcinoma of the upper aerodigestive tract: precursors and problematic variants. *Mod Pathol*. 2002;15(3):229-254.
27. Smith BD, Haffty BG. Prognostic factoris in patients with head and neck cancer. In: Harrison LB, Sessions RB, Hong WK, eds. *Head and Neck Cancer: A Multidisciplinary Approach*. Philadelphia: Lippincott Williams and Wilkins; 2009:51-75.
28. Fagan JJ, Collins B, Barnes L, D'Amico F, Myers EN, Johnson JT. Perineural invasion in squamous cell carcinoma of the head and neck. *Arch Otolaryngol Head Neck Surg*. 1998;124(6):637-640.
29. Miller ME, Palla B, Chen Q, et al. A novel classification system for perineural invasion in noncutaneous head and neck squamous cell carcinoma: histologic subcategories and patient outcomes. *Am J Otolaryngol*. 2012;33(2):212-215.
30. Cooper JS, Pajak TF, Forastiere AA, et al. Postoperative concurrent radiotherapy and chemotherapy for high-risk squamous-cell carcinoma of the head and neck. *N Engl J Med*. 2004;350(19):1937-1944.
31. Bernier J, Domenge C, Ozsahin M, et al. Postoperative irradiation with or without concomitant chemotherapy for locally advanced head and neck cancer. *N Engl J Med*. 2004;350(19):1945-1952.
32. Woolgar J, Triantafyllou A. Neck dissections: a practical guid for the reporting histopathologist. *Curr Diag Pathol*. 2007;13:499-511.
33. Leemans CR, Tiwari R, Nauta JJ, van der Waal I, Snow GB. Regional lymph node involvement and its significance in the development of distant metastases in head and neck carcinoma. *Cancer*. 1993;71(2):452-456.
34. Woolgar JA, Rogers SN, Lowe D, Brown JS, Vaughan ED. Cervical lymph node metastasis in oral cancer: the importance of even microscopic extracapsular spread. *Oral Oncol*. 2003;39(2):130-137.
35. Johnson JT, Myers EN, Bedetti CD, Barnes EL, Schramm VL Jr, Thearle PB. Cervical lymph node metastases: incidence and implications of extracapsular carcinoma. *Arch Otolaryngol*. 1985;111(8):534-537.
36. Sobin LH, Gospodarowicz MK, Wittekind CH, eds. *TNM Classification of Malignant Tumours*. New York: Wiley-Liss; 2009.
37. Martinez-Madrigal F, Pineda-Daboin K, Casiraghi O, Luna MA. Salivary gland tumors of the mandible. *Ann Diagn Pathol*. 2000;4(6):347-353.

38. Seethala RR. Current state of neck dissection in the United States. *Head Neck Pathol.* 2009;3(3):238-245.
39. Robbins KT, Shaha AR, Medina JE, et al. Consensus statement on the classification and terminology of neck dissection. *Arch Otolaryngol Head Neck Surg.* 2008;134(5):536-538.
40. Ferlito A, Robbins KT, Shah JP, et al. Proposal for a rational classification of neck dissections. *Head Neck.* 2011;33(3):445-450.
41. Suarez C, Rodrigo JP, Robbins KT, et al. Superselective neck dissection: rationale, indications, and results. *Eur Arch Otorhinolaryngol.* 2013 Jan 16. [Epub ahead of print]
42. Singletary SE, Greene FL, Sobin LH. Classification of isolated tumor cells: clarification of the 6th edition of the American Joint Committee on Cancer Staging Manual. *Cancer.* 2003;98(12):2740-2741.
43. Broglie MA, Haerle SK, Huber GF, Haile SR, Stoeckli SJ. Occult metastases detected by sentinel node biopsy in patients with early oral and oropharyngeal squamous cell carcinomas: impact on survival. *Head Neck.* 2013;35(5):660-666.
44. Gale N, Pilch BZ, Sidransky D, Westra WH, Califano JA. Epithelial precursor lesions. In: Barnes L, Eveson JW, Reichart P, Sidransky D, eds. *Pathology and Genetics of Head and Neck Tumours.* Lyon, France: IARC Press; 2005:140-143. *World Health Organization Classification of Tumours.*
45. Slootweg P, Merkx TMAW. Premalignant lesions of the oral cavity. In: Barnes L, ed. *Surgical Pathology of the Head and Neck.* New York: Informa Healthcare; 2009:267-284.
46. Chung CH, Gillison ML. Human papillomavirus in head and neck cancer: its role in pathogenesis and clinical implications. *Clin Cancer Res.* 2009;15(22):6758-6762.
47. IARC Working Group on the Evaluation of Carcinogenic Risks to Humans. Human papillomaviruses. *IARC Monogr Eval Carcinog Risks Hum.* 2007.
48. Lewis JS Jr, Khan RA, Masand RP, et al. Recognition of nonkeratinizing morphology in oropharyngeal squamous cell carcinoma: a prospective cohort and interobserver variability study. *Histopathology.* 2012;60(3):427-436.