

## Protocol for the Examination of Specimens from Patients with Invasive Carcinoma of Renal Tubular Origin

Version: Kidney 4.0.1.1

Protocol Posting Date: June 2017

Includes pTNM requirements from the 8<sup>th</sup> Edition, AJCC Staging Manual

**For accreditation purposes, this protocol should be used for the following procedures AND tumor types:**

Procedure	Description
Nephrectomy	Includes specimens designated partial, total, or radical nephrectomy
Tumor Type	Description
Renal cell carcinomas	Includes all renal cell carcinoma variants

**This protocol is NOT required for accreditation purposes for the following:**

Procedure
Biopsy (needle, incisional or wedge)
Primary resection specimen with no residual cancer (eg, following neoadjuvant therapy)
Cytologic specimens

**The following tumor types should NOT be reported using this protocol:**

Tumor Type
Urothelial tumors (consider Ureter, Renal Pelvis protocol)
Wilm's tumors (Consider Wilm's Tumor protocol)
Lymphoma (consider the Hodgkin or non-Hodgkin Lymphoma protocols)
Sarcoma (consider the Soft Tissue protocol)

### Authors

John R. Srigley, MD\*; Ming Zhou, MD, PhD\*; Robert Allan, MD; Mahul B. Amin, MD; Steven C. Campbell, MD, PhD; Anthony Chang, MD; Brett Delahunt, MD; David J. Grignon, MD; Peter A. Humphrey, MD, PhD; Bradley C. Leibovich, MD; Rodolfo Montironi, MD; Jason Pettus, MD; Victor E. Reuter, MD

With guidance from the CAP Cancer and CAP Pathology Electronic Reporting Committees.

\* Denotes primary author. All other contributing authors are listed alphabetically.

### Accreditation Requirements

This protocol can be utilized for a variety of procedures and tumor types for clinical care purposes. For accreditation purposes, only the definitive primary cancer resection specimen is required to have the core and conditional data elements reported in a synoptic format.

- Core data elements are required in reports to adequately describe appropriate malignancies. For accreditation purposes, essential data elements must be reported in all instances, even if the response is “not applicable” or “cannot be determined.”
- Conditional data elements are only required to be reported if applicable as delineated in the protocol. For instance, the total number of lymph nodes examined must be reported, but only if nodes are present in the specimen.
- Optional data elements are identified with “+” and although not required for CAP accreditation purposes, may be considered for reporting as determined by local practice standards.

The use of this protocol is not required for recurrent tumors or for metastatic tumors that are resected at a different time than the primary tumor. Use of this protocol is also not required for pathology reviews performed at a second institution (ie, secondary consultation, second opinion, or review of outside case at second institution).

### Synoptic Reporting

All core and conditionally required data elements outlined on the surgical case summary from this cancer protocol must be displayed in synoptic report format. Synoptic format is defined as:

- Data element: followed by its answer (response), outline format without the paired "Data element: Response" format is NOT considered synoptic.
- The data element should be represented in the report as it is listed in the case summary. The response for any data element may be modified from those listed in the case summary, including “Cannot be determined” if appropriate.
- Each diagnostic parameter pair (Data element: Response) is listed on a separate line or in a tabular format to achieve visual separation. The following exceptions are allowed to be listed on one line:
  - Anatomic site or specimen, laterality, and procedure
  - Pathologic Stage Classification (pTNM) elements
  - Negative margins, as long as all negative margins are specifically enumerated where applicable
- The synoptic portion of the report can appear in the diagnosis section of the pathology report, at the end of the report or in a separate section, but all Data element: Responses must be listed together in one location

Organizations and pathologists may choose to list the required elements in any order, use additional methods in order to enhance or achieve visual separation, or add optional items within the synoptic report. The report may have required elements in a summary format elsewhere in the report IN ADDITION TO but not as replacement for the synoptic report i.e. all required elements must be in the synoptic portion of the report in the format defined above.

### CAP Laboratory Accreditation Program Protocol Required Use Date: March 2018\*

\* Beginning January 1, 2018, the 8th edition AJCC Staging Manual should be used for reporting pTNM.

## CAP Kidney Protocol Summary of Changes

---

### Version 4.0.1.1

**Modified** Histologic Type

### Version 4.0.1.0 errata:

**Modified** Size of Largest Metastatic Deposit - Unit of measure from millimeters to centimeters

### Version 4.0.0.0:

**The following data elements were modified:**

Pathologic Stage Classification (pTNM, AJCC 8th Edition)

**Surgical Pathology Cancer Case Summary**

---

Protocol posting date: June 2017

**KIDNEY: Biopsy****Note: This case summary is recommended for reporting biopsy specimens, but is not required for accreditation purposes.****Select a single response unless otherwise indicated.****+ Procedure**

- +  Needle biopsy
- +  Incisional biopsy, wedge
- +  Other (specify): \_\_\_\_\_
- +  Not specified

**+ Specimen Laterality**

- +  Right
- +  Left
- +  Not specified

**+ Histologic Type (Note A)**

- +  Clear cell renal cell carcinoma
- +  Multilocular cystic clear cell renal cell neoplasm of low malignant potential
- +  Papillary renal cell carcinoma
- +  Papillary renal cell carcinoma, Type 1
- +  Papillary renal cell carcinoma, Type 2
- +  Chromophobe renal cell carcinoma
- +  Collecting duct carcinoma
- +  Renal medullary carcinoma
- +  MiT family translocation renal cell carcinoma
- +  Xp11 translocation renal cell carcinoma
- +  t(6;11) renal cell carcinoma
- +  Mucinous tubular and spindle renal cell carcinoma
- +  Tubulocystic renal cell carcinoma
- +  Acquired cystic disease associated renal cell carcinoma
- +  Clear cell papillary renal cell carcinoma
- +  Hereditary leiomyomatosis and renal cell carcinoma-associated renal cell carcinoma
- +  Succinate dehydrogenase (SDH) deficient renal cell carcinoma
- +  Renal cell carcinoma, unclassified
- +  Other histologic type not listed (specify): \_\_\_\_\_

**+ Sarcomatoid Features (Note B)**

- +  Not identified
- +  Present
  - + Specify percentage of sarcomatoid element: \_\_\_\_\_%

**+ Rhabdoid Features (Note B)**

- +  Not identified
- +  Present

**+ Histologic Grade (World Health Organization [WHO] / International Society of Urological Pathology [ISUP] Grade) (Note C)**

- +  G1: Nucleoli absent or inconspicuous and basophilic at 400x magnification

+ Data elements preceded by this symbol are not required for accreditation purposes. These optional elements may be clinically important but are not yet validated or regularly used in patient management.

- + \_\_\_ G2: Nucleoli conspicuous and eosinophilic at 400x magnification, visible but not prominent at 100x magnification
- + \_\_\_ G3: Nucleoli conspicuous and eosinophilic at 100x magnification
- + \_\_\_ G4: Extreme nuclear pleomorphism and/or multinuclear giant cells and/or rhabdoid and/or sarcomatoid differentiation
- + \_\_\_ GX: Cannot be assessed
- + \_\_\_ Not applicable

**+ Necrosis (Note D)**

- + \_\_\_ Not identified
- + \_\_\_ Present

**+ Lymphovascular Invasion**

- + \_\_\_ Not identified
- + \_\_\_ Present

**+ Additional Pathologic Findings**

- + \_\_\_ None identified
- + \_\_\_ Other pathology present (specify): \_\_\_\_\_

**+ Comment(s)**

**Surgical Pathology Cancer Case Summary**

---

Protocol posting date: June 2017

**KIDNEY: Nephrectomy****Select a single response unless otherwise indicated.****Procedure (Note E)**

- Partial nephrectomy  
 Radical nephrectomy  
 Total nephrectomy  
 Other (specify): \_\_\_\_\_  
 Not specified

**Specimen Laterality**

- Right  
 Left  
 Not specified

**+ Tumor Site (select all that apply)**

- Upper pole  
 Middle  
 Lower pole  
 Other (specify): \_\_\_\_\_  
 Not specified

**Tumor Size***Note: If multiple tumors present, document the size of the largest tumor.*

- Greatest dimension (centimeters): \_\_\_ cm  
 + Additional dimensions (centimeters): \_\_\_ x \_\_\_ cm  
 Cannot be determined (explain): \_\_\_\_\_

**Tumor Focality**

- Unifocal  
 Multifocal

**Histologic Type (Note A)**

- Clear cell renal cell carcinoma  
 Multilocular cystic clear cell renal cell neoplasm of low malignant potential  
 Papillary renal cell carcinoma  
 Papillary renal cell carcinoma, Type 1  
 Papillary renal cell carcinoma, Type 2  
 Chromophobe renal cell carcinoma  
 Collecting duct carcinoma  
 Renal medullary carcinoma  
 MiT family translocation renal cell carcinoma  
 Xp11 translocation renal cell carcinoma  
 t(6;11) renal cell carcinoma  
 Mucinous tubular and spindle renal cell carcinoma  
 Tubulocystic renal cell carcinoma  
 Acquired cystic disease associated renal cell carcinoma  
 Clear cell papillary renal cell carcinoma  
 Hereditary leiomyomatosis and renal cell carcinoma-associated renal cell carcinoma  
 Succinate dehydrogenase (SDH) deficient renal cell carcinoma

+ Data elements preceded by this symbol are not required for accreditation purposes. These optional elements may be clinically important but are not yet validated or regularly used in patient management.

- Renal cell carcinoma, unclassified  
 Other histologic type not listed (specify): \_\_\_\_\_

**Sarcomatoid Features (Note B)**

- Not identified  
 Present  
     + Specify percentage of sarcomatoid element: \_\_\_\_\_%

**Rhabdoid Features (Note B)**

- Not identified  
 Present

**Histologic Grade (WHO / ISUP Grade) (Note C)**

- G1: Nucleoli absent or inconspicuous and basophilic at 400x magnification  
 G2: Nucleoli conspicuous and eosinophilic at 400x magnification, visible but not prominent at 100x magnification  
 G3: Nucleoli conspicuous and eosinophilic at 100x magnification  
 G4: Extreme nuclear pleomorphism and/or multi-nuclear giant cells and/or rhabdoid and/or sarcomatoid differentiation  
 GX: Cannot be assessed  
 Not applicable

**Tumor Necrosis (Note D)**

- Not identified  
 Present  
     + Specify percentage of necrosis: \_\_\_\_\_ %

**Tumor Extension (select all that apply) (Notes F and G)**

- No evidence of primary tumor  
 Tumor limited to kidney  
 Tumor extension into perinephric tissue (beyond renal capsule)  
 Tumor extension into renal sinus  
 Tumor extension beyond Gerota's fascia  
 Tumor extension into major vein (renal vein or its segmental branches, inferior vena cava)  
 Tumor extension into pelvic/lyceal system  
 Tumor extension into adrenal gland  
      Direct invasion (T4)  
      Noncontiguous (M1)  
 Tumor extension into other organ(s)/structure(s) (specify): \_\_\_\_\_  
 Cannot be assessed

**Margins (select all that apply) (Note H)**

- Cannot be assessed  
 Uninvolved by invasive carcinoma  
 Involved by invasive carcinoma  
      Renal parenchymal margin (partial nephrectomy only)  
      Renal capsular margin (partial nephrectomy only)  
      Perinephric fat margin  
      Renal sinus soft tissue margin  
      Gerota's fascial margin  
      Renal vein margin  
      Ureteral margin  
      Other (specify): \_\_\_\_\_

**+ Lymphovascular Invasion (excluding renal vein and its segmental branches and inferior vena cava)**

- + \_\_\_ Not identified  
 + \_\_\_ Present  
 + \_\_\_ Cannot be determined

**Regional Lymph Nodes**

\_\_\_ No lymph nodes submitted or found

Lymph Node Examination (required only if lymph nodes are present in the specimen)

Number of Lymph Nodes Involved: \_\_\_\_\_

\_\_\_ Number cannot be determined (explain): \_\_\_\_\_

+ Specify Site(s): \_\_\_\_\_ #

# Note: Sites may include hilar, precaval, interaortocaval, paracaval, retrocaval, preaortic, paraaortic, retroaortic, or other lymph nodes.

Number of Lymph Nodes Examined: \_\_\_\_\_

\_\_\_ Number cannot be determined (explain): \_\_\_\_\_

+ Size of Largest Metastatic Deposit (centimeters): \_\_\_ cm

+ Specify Site: \_\_\_\_\_

+ Size of Largest Lymph Node Involved (centimeters): \_\_\_ cm

+ Specify Site: \_\_\_\_\_

**Pathologic Stage Classification (pTNM, AJCC 8<sup>th</sup> Edition) (Note I)**

*Note: Reporting of pT, pN, and (when applicable) pM categories is based on information available to the pathologist at the time the report is issued. Only the applicable T, N, or M category is required for reporting; their definitions need not be included in the report. The categories (with modifiers when applicable) can be listed on 1 line or more than 1 line.*

TNM Descriptors (required only if applicable) (select all that apply)

\_\_\_ m (multiple primary tumors)

\_\_\_ r (recurrent)

\_\_\_ y (posttreatment)

Primary Tumor (pT)

\_\_\_ pTX: Primary tumor cannot be assessed

\_\_\_ pT0: No evidence of primary tumor

\_\_\_ pT1: Tumor ≤7 cm in greatest dimension, limited to the kidney

\_\_\_ pT1a: Tumor ≤4 cm in greatest dimension, limited to the kidney

\_\_\_ pT1b: Tumor >4 cm but ≤7 cm in greatest dimension limited to the kidney

\_\_\_ pT2: Tumor >7 cm in greatest dimension, limited to the kidney

\_\_\_ pT2a: Tumor >7 cm but ≤10 cm in greatest dimension, limited to the kidney

\_\_\_ pT2b: Tumor >10 cm, limited to the kidney

\_\_\_ pT3: Tumor extends into major veins or perinephric tissues, but not into the ipsilateral adrenal gland and not beyond Gerota's fascia

\_\_\_ pT3a: Tumor extends into the renal vein or its segmental branches, or invades the pelvicalyceal system, or invades perirenal and/or renal sinus fat but not beyond Gerota's fascia

\_\_\_ pT3b: Tumor extends into the vena cava below the diaphragm

\_\_\_ pT3c: Tumor extends into vena cava above the diaphragm or invades the wall of the vena cava

\_\_\_ pT4: Tumor invades beyond Gerota's fascia (including contiguous extension into the ipsilateral adrenal gland)

Regional Lymph Nodes (pN)

- pNX: Regional lymph nodes cannot be assessed
- pN0: No regional lymph node metastasis
- pN1: Metastasis in regional lymph node(s)

Distant Metastasis (pM) (required only if confirmed pathologically in this case)

- pM1: Distant metastasis  
Specify site(s), if known: \_\_\_\_\_

**Pathologic Findings in Nonneoplastic Kidney (select all that apply) (Note J)**

- Insufficient tissue
- None identified
- Glomerular disease (specify type): \_\_\_\_\_
- Tubulointerstitial disease (specify type): \_\_\_\_\_
- Vascular disease (specify type): \_\_\_\_\_
- Other (specify): \_\_\_\_\_

**+ Additional Pathological Findings (select all that apply)**

- +  Cyst(s) (specify type): \_\_\_\_\_
- +  Tubular (papillary) adenoma(s)
- +  Other (specify): \_\_\_\_\_

**+ Comment(s)**



## Explanatory Notes

---

### A. Histologic Type

The current World Health Organization (WHO) classification (2016) is based on the International Society of Urological Pathology (ISUP) Vancouver Classification of Renal Neoplasia 2012.<sup>1,2</sup>

Clear cell renal cell carcinoma

Multilocular clear cell renal cell neoplasm of low malignant potential

Papillary renal cell carcinoma

    Type 1

    Type 2

Chromophobe renal cell carcinoma

Collecting duct carcinoma

Renal medullary carcinoma

MiT family translocation renal cell carcinoma

Mucinous tubular and spindle cell carcinoma

Tubulocystic renal cell carcinoma

Acquired cystic disease associated renal cell carcinoma

Clear cell papillary/tubulopapillary renal cell carcinoma

Hereditary leiomyomatosis and renal cell carcinoma-associated renal cell carcinoma

Succinate dehydrogenase (SDH) deficient renal carcinoma

Renal cell carcinoma, unclassified

Papillary adenoma

Renal oncocytoma

Many subtypes of renal cell carcinoma, including many newly described variants, have differing clinical behaviors and prognosis.<sup>1-4</sup> Additionally the usage of adjuvant therapy is related to tumor subtype.<sup>5</sup> The concept of an emerging/provisional category of renal cell carcinoma was introduced in the 2012 ISUP Vancouver classification.<sup>2</sup> These tumors, while appearing distinctive, had not been fully characterized morphologically or by ancillary techniques. This category in the 2016 WHO classification includes the following entities: oncocytoid renal cell carcinoma (RCC) postneuroblastoma, thyroid-like follicular RCC, anaplastic lymphoma kinase (ALK) rearrangement-associated RCC, and RCC with (angio) leiomyomatous stroma.<sup>1</sup> For the purpose of the protocol, these emerging tumors should be classified under “other” and the name specified.

Occasionally more than 1 histologic type of carcinoma occurs within the same kidney specimen. Each tumor type should be separately recorded along with its associated prognostic factors.<sup>6</sup>

### B. Sarcomatoid and Rhabdoid Features

Sarcomatoid carcinoma is not a specific morphogenetic subtype of renal cell carcinoma but is considered as a pattern of dedifferentiation.<sup>1,6-8</sup> Sarcomatoid change in a renal cell carcinoma is associated with an adverse outcome.<sup>1,8</sup> Sarcomatoid morphology may be found in any histologic subtypes of renal cell carcinomas, including clear cell, papillary, chromophobe, collecting duct, and other rare and unclassified subtypes.<sup>1,6-8</sup> When the background carcinoma subtype is recognized, it should be specified under histologic type (see Note A). Pure sarcomatoid carcinoma or sarcomatoid carcinoma associated with epithelial elements that do not conform to usual renal carcinoma cell types should be considered as unclassified renal cell carcinoma. Sarcomatoid morphology is also incorporated into the WHO/ISUP grading system as grade 4.

There is some indication that the percentage of sarcomatoid component in a renal cell carcinoma has prognostic importance.<sup>6,8</sup>

Rhabdoid features, like sarcomatoid, are a characteristic of high-grade disease. Rhabdoid cells have abundant eosinophilic cytoplasm with an eccentric nucleus often with a prominent nucleolus.<sup>8-11</sup> Rhabdoid changes are associated with an adverse outcome and in cases with rhabdoid morphology, about 25% of them also show sarcomatoid features.<sup>1</sup> Rhabdoid morphology is an important component of the new WHO/ISUP grading system (grade 4).<sup>8</sup> No solid evidence exists on the prognostic significance of the extent of rhabdoid morphology.<sup>1</sup>

### C. Histologic Grade

The WHO/ISUP grading system has supplanted the Fuhrman system as the grading standard.<sup>1,8</sup> This grading system has been validated for both clear cell and papillary renal cell carcinoma; however, it has not been validated for other RCC subtypes.<sup>12,13</sup> Nevertheless, the WHO/ISUP grade may be included for descriptive purposes. Currently it is recommended that chromophobe renal cell carcinoma not be graded with the WHO/ISUP system. Details are shown below:

Not applicable

Grade X- Cannot be assessed

Grade 1 - Nucleoli absent or inconspicuous and basophilic at 400x magnification

Grade 2 - Nucleoli conspicuous and eosinophilic at 400x magnification, visible but not prominent at 100x magnification

Grade 3 - Nucleoli conspicuous and eosinophilic at 100x magnification

Grade 4 - Extreme nuclear pleomorphism and/or multinuclear giant cells and/or rhabdoid and/or sarcomatoid differentiation

Although the grading system does reference the tinctorial characteristics of the nucleoli, the determining feature is the nucleolar prominence. Grade should be assigned based on the single high-power field showing the greatest degree of pleomorphism.

### D. Necrosis

Tumor necrosis is an important prognostic factor in renal cell carcinoma.<sup>8,14,15</sup> It is recommended that both macroscopic and microscopic (coagulative) necrosis be recorded. The prognostic significance of necrosis independent of tumor stage has been identified in clear cell and chromophobe renal cell carcinoma.<sup>14</sup> The prognostic significance of necrosis in papillary renal cell carcinoma is controversial. Large papillary carcinomas not uncommonly display cystic necrosis and yet don't exhibit extra renal spread. Tumor necrosis as a prognostic factor cannot be assessed in a situation where patients have undergone presurgical arterial embolization.

At present, the prognostic significance of the extent of necrosis is unclear; however, it is recommended that this be recorded as a percentage.<sup>15</sup>

### E. Specimen Type

A standard radical nephrectomy specimen consists of the entire kidney including the calyces, pelvis, and a variable length of ureter. The adrenal gland is usually removed en bloc with the kidney. The entire perirenal fatty tissue is removed to the level of Gerota's fascia, a membranous structure that is similar to the consistency of the renal capsule that encases the kidney in perirenal fat. Variable lengths of the major renal vessels at the hilus are submitted.

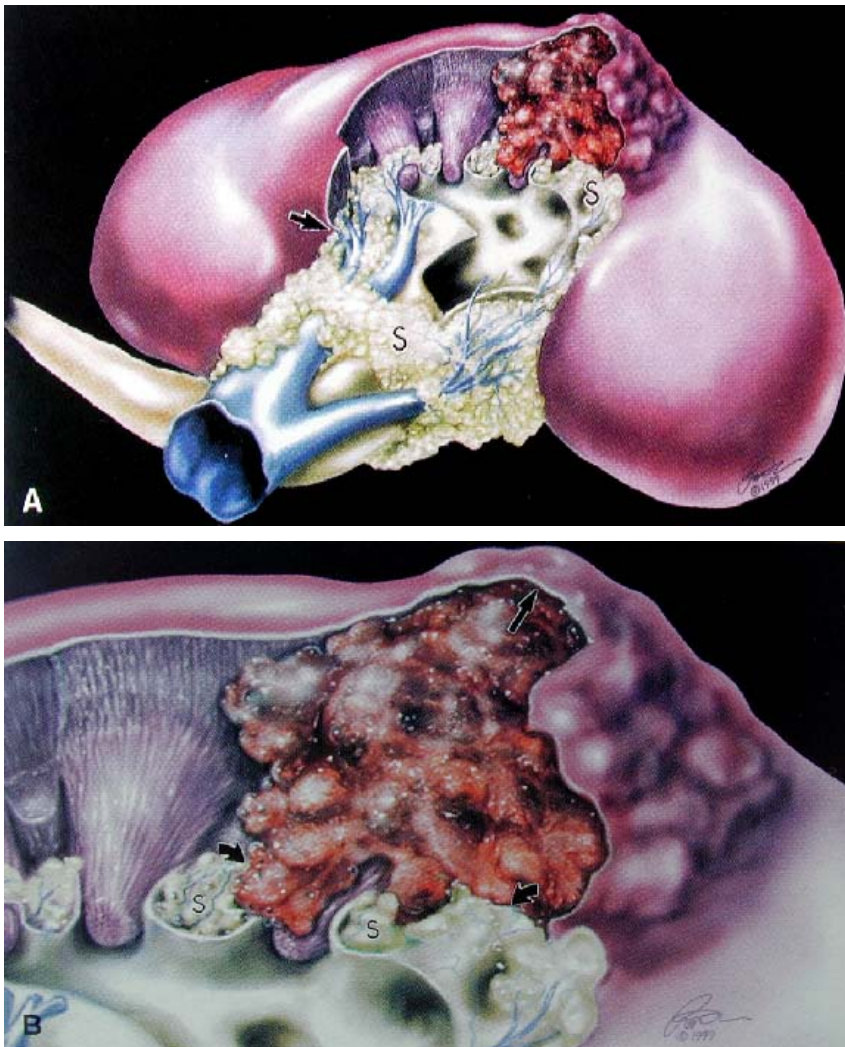
Regional lymphadenectomy is not generally performed even with a radical nephrectomy. A few lymph nodes may occasionally, be seen in the renal hilus around major vessels. Other regional lymph nodes (eg, paracaval, para-aortic, and retroperineal) may be submitted separately.

A partial nephrectomy specimen may vary from a simple enucleation of the tumor to part of a kidney containing variable portions of calyceal or renal pelvic collecting system. The perirenal fat immediately overlying the resected portion of the kidney but not to a level of Gerota's fascia is usually included.

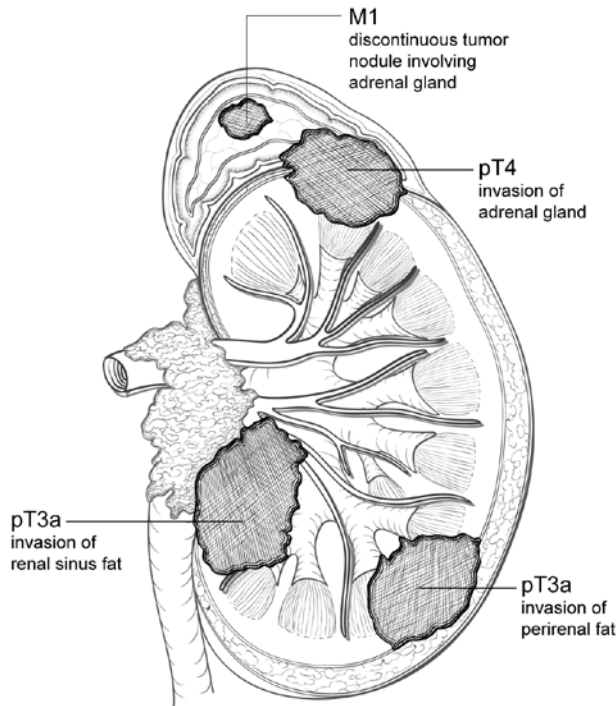
### F. Macroscopic Extent of Tumor

A careful gross analysis and description of tumor extension in a nephrectomy specimen is important and should guide blocking of tissue samples for histologic assessment.<sup>16</sup> Careful documentation of the tumor extension beyond kidney into perinephric fat and Gerota's fascia provides important staging information.<sup>17,18</sup> Renal sinus involvement in renal cell carcinoma is an under-recognized phenomenon.<sup>19</sup> The renal sinus is an important pathway of spread of renal cell carcinoma (Figure 1, A and B). The renal sinus should be carefully assessed and generously sampled in order to detect renal sinus fat and vessel involvement.<sup>16</sup> There is evolving literature suggesting that renal sinus involvement predicts a more aggressive outcome than peripheral perinephric fat invasion.<sup>20,21</sup> If a tumor thrombus is present in the renal vein it is important to determine if the tumor is confined to

the renal vein (pT3a) or whether it extends into inferior vena cava (pT3b/c). When renal carcinoma involves adrenal gland, it is important to document whether the involvement is contiguous spread of tumor or a separate (noncontiguous) nodule of carcinoma, the latter representing metastatic disease (pM1) (Figure 2).<sup>17</sup>



**Figure 1.** A, Diagram showing the renal sinus fat (S) and its rich venous system that envelops the collecting system. The renal capsule terminates (arrow) just inside the vestibule of the hilus. B, A renal malignancy is constrained by the renal capsule (arrow), yet no fibrous capsule impedes its growth into the vascular tissue of the renal sinus (curved arrows). From Bonsib et al.<sup>19</sup> Reproduced with permission of the American Journal of Surgical Pathology. © 2000 Wolters Kluwer Health.



**Figure 2.** Diagram showing relationship between local tumor extension and pT designation. When a tumor shows direct invasion into the perirenal fat or renal sinus fat, it is designated as pT3a. A tumor that directly invades the adrenal gland is designated as pT4, while a tumor that shows discontinuous (noncontiguous) involvement of the adrenal gland is considered metastatic (M1).

### G. Microscopic Tumor Extension

The microscopic documentation of extrarenal extension is critical in assigning a pT category in renal cell carcinoma. Invasion of perirenal fat is considered pT3a and invasion beyond Gerota's fascia is a feature of pT4 disease.<sup>17</sup>

The renal sinus is an anatomical compartment separating the renal parenchyma from the upper collecting system (renal pelvis and calyces).<sup>16,19</sup> In this area abundant adipose tissue, lymphatics, and thin walled veins are noted in the renal sinus. Clear cell renal cell carcinomas  $\geq 7$  cm in diameter show renal sinus invasion in greater than 90% of cases.<sup>20</sup> In recent years, the definition of renal sinus involvement has been clarified and includes the following: (1) tumor in contact with renal sinus fat, (2) tumor in loose connective tissue of sinus clearly beyond the renal parenchyma, and (3) involvement of endothelial lined spaces (with or without mural smooth muscle), including lymphatics.<sup>16,22,23</sup>

Involvement of the renal vein or segmental branches is generally identified macroscopically and is definitional for the pT3a category.<sup>17</sup> It is important to document renal involvement microscopically.

Direct spread of tumor into the adrenal gland (if present) is considered pT4 disease.<sup>24,25</sup> However, if there is a discrete separate nodule in the adrenal gland, this would be considered pM1 disease. Additionally, the presence of metastatic disease in any other accompanying organs would be considered pM1 disease for the purpose of the TNM system.<sup>17</sup>

### H. Margins

In a partial nephrectomy specimen, the renal parenchymal margin should be inked and histologically assessed.<sup>16</sup> Most partial nephrectomy specimens also contain a portion of perinephric fat overlying the tumor site. The perirenal fat margin should also be assessed. In situations where no perirenal fat is present, the renal capsular margin should be inked and examined histologically.<sup>16</sup>

In radical nephrectomy specimens the ureteric, major vascular (renal vein, renal artery) and soft tissue (Gerota's fascia, renal sinus) margins should be examined and documented in the report.

### I. TNM and Stage Groupings

The TNM staging system of the American Joint Committee on Cancer (AJCC) for renal cell carcinoma is recommended.<sup>17</sup>

By AJCC convention, the designation "T" refers to a primary tumor that has not been previously treated. The symbol "p" refers to the pathologic classification of the TNM, as opposed to the clinical classification, and is based on gross and microscopic examination. pT entails a resection of the primary tumor or biopsy adequate to evaluate the highest pT category, pN entails removal of nodes adequate to validate lymph node metastasis, and pM implies microscopic examination of distant lesions. Clinical classification (cTNM) is usually carried out by the referring physician before treatment during initial evaluation of the patient or when pathologic classification is not possible.

Pathologic staging is usually performed after surgical resection of the primary tumor. Pathologic staging depends on pathologic documentation of the anatomic extent of disease, whether or not the primary tumor has been completely removed. If a biopsied tumor is not resected for any reason (eg, when technically unfeasible) and if the highest T and N categories or the M1 category of the tumor can be confirmed microscopically, the criteria for pathologic classification and staging have been satisfied without total removal of the primary cancer.

#### TNM Descriptors

For identification of special cases of TNM or pTNM classifications, the "m" suffix and "y," "r," and "a" prefixes are used. Although they do not affect the stage grouping, they indicate cases needing separate analysis.

The "m" suffix indicates the presence of multiple primary tumors in a single site and is recorded in parentheses: pT(m)NM.

The "y" prefix indicates those cases in which classification is performed during or following initial multimodality therapy (ie, neoadjuvant chemotherapy, radiation therapy, or both chemotherapy and radiation therapy). The cTNM or pTNM category is identified by a "y" prefix. The ycTNM or ypTNM categorizes the extent of tumor actually present at the time of that examination. The "y" categorization is not an estimate of tumor prior to multimodality therapy (ie, before initiation of neoadjuvant therapy).

The "r" prefix indicates a recurrent tumor when staged after a documented disease-free interval, and is identified by the "r" prefix: rTNM.

The "a" prefix designates the stage determined at autopsy: aTNM.

#### Additional Descriptors

##### Residual Tumor (R)

Tumor remaining in a patient after therapy with curative intent (eg, surgical resection for cure) is categorized by a system known as R classification, shown below.

RX	Presence of residual tumor cannot be assessed
R0	No residual tumor
R1	Microscopic residual tumor
R2	Macroscopic residual tumor

For the surgeon, the R classification may be useful to indicate the known or assumed status of the completeness of a surgical excision. For the pathologist, the R classification is relevant to the status of the margins of a surgical resection specimen. That is, tumor involving the resection margin on pathologic examination may be assumed to correspond to residual tumor in the patient and may be classified as macroscopic or microscopic according to the findings at the specimen margin(s).

### Lymphovascular Invasion

By AJCC convention, vessel invasion (lymphatic or venous) does not affect the T category indicating local extent of tumor unless specifically included in the definition of a T category. In all other cases, lymphatic and venous invasion by tumor are coded separately.

### **J. Pathologic Findings in Nonneoplastic Kidney**

It is important to recognize that medical kidney diseases may be present in nonneoplastic renal tissue in nephrectomy and nephroureterectomy specimens.<sup>26,27</sup> Arterionephrosclerosis (or hypertensive nephropathy) and diabetic nephropathy are seen in approximately 30% and 20% of cases, respectively. Other medical renal diseases that have been identified include thrombotic microangiopathy, focal segmental glomerulosclerosis, and IgA nephropathy. The findings of greater than 20% global glomerulosclerosis or advanced diffuse diabetic glomerulosclerosis are predictive of significant decline in renal function 6 months after radical nephrectomy.<sup>24</sup> Evaluation for medical renal disease should be performed in each case; PAS and/or Jones methenamine silver stains should be applied if necessary. Consultation with a nephropathologist should be pursued as needed.

However, no studies have specifically measured peritumoral-related changes in the renal cortex. Some tumors have no peritumoral changes. Oncocytoma is the best example. While some large tumors often have a large zone of peritumoral changes compared with smaller tumors. The pseudocapsule may contain sclerotic glomeruli, tubular atrophy and show fibrointimal thickening of arteries, followed by a zone of several millimeters of acute tubular injury, none of which is representative of the cortex elsewhere.<sup>28</sup> A judgement whether the amount of nonneoplastic renal parenchyma is sufficient for evaluation of medical kidney diseases should be made on a case by case basis. Two studies have used 1 mm to 5 mm as the cut-off for insufficient renal parenchyma.<sup>29,30</sup> Five millimeters of nonneoplastic renal parenchyma is a reasonable recommendation.

### **References**

1. Humphrey PA, Moch H, Reuter VE, Ulbright TM, eds. *World Health Organization (WHO) Classification of Tumours. Pathology and Genetics of the Urinary System and Male Genital Organs*. Geneva, Switzerland: WHO Press; 2016.
2. Srigley JR, Delahunt B, Eble JN, et al. The International Society of Urological Pathology (ISUP) Vancouver classification of renal neoplasia. *Am J Surg Pathol*. 2013;37:1469-1489.
3. Murphy WM, Grignon DJ, Perlman EJ, eds. *Tumours of the Kidney, Bladder, and Related Urinary Structures*. AFIP Atlas of Tumour Pathology. Series 4. Washington, DC: American Registry of Pathology; 2004.
4. Srigley JR, Delahunt B. Uncommon and recently described renal carcinomas. *Mod Pathol*. 2009;22:S2-S23.
5. O'Brien MF, Russo P, Motzer RJ. Sunitinib therapy in renal cell carcinoma. *BJU Int*. 2008;101:1339-1342.
6. de Peralta-Venturina M, Moch H, Amin M, et al. Sarcomatoid differentiation in renal cell carcinoma: a study of 101 cases. *Am J Surg Pathol*. 2001;25:275-278.
7. Cheville JC, Lohse CM, Zincke H, et al. Sarcomatoid renal cell carcinoma: an examination of underlying histologic subtype and an analysis of associations with patient outcome. *Am J Surg Pathol*. 2004;28:435-441.
8. Delahunt B, Cheville JC, Martignoni G, et al. The International Society of Urological Pathology (ISUP) grading system for renal cell carcinoma and other prognostic parameters. *Am J Surg Pathol*. 2013;37:1490-1504.
9. Kuroiwa K, Kinoshita Y, Shiratsuchi H, et al. Renal cell carcinoma with rhabdoid features: an aggressive neoplasm. *Histopathology*. 2002;41:538-548.
10. Gokden N, Nappi O, Swanson PE, et al. Renal cell carcinoma with rhabdoid features. *Am J Surg Pathol*. 2000;24:1329-1338.
11. Leroy X, Zini L, Buob D, et al. Renal cell carcinoma with rhabdoid features. *Arch Pathol Lab Med*. 2007;131:102-106.
12. Sika-Paotonu D, Bethwaite PB, McCredie MRE, Jordan TW, Delahunt B. Nucleolar grade but not Fuhrman grade is applicable to papillary renal cell carcinoma. *Am J Surg Pathol*. 2006;30:1091-1096.
13. Delahunt B, Sika-Paotonu D, Bethwaite PB, et al. Grading of clear cell renal cell carcinoma should be based on nucleolar prominence. *Am J Surg Pathol*. 2011;135:1134-1139.
14. Cheville JC, Lohse CM, Zincke H, Weaver AL, Blute ML. Comparison of outcome and prognostic features among histologic subtypes of renal cell carcinoma. *Am J Surg Pathol*. 2003;27:612-624.
15. Klatte T, Said JW, de Martino M, et al. Presence of tumour necrosis is not a significant predictor of survival in clear cell renal cell carcinoma: higher prognostic accuracy of extent based rather than presence/absence classification. *J Urol*. 2009;181:1558-1564.

16. Trpkov K, Grignon DJ, Bonsib SN, et al. Handling and staging of renal cell carcinoma: the International Society of Urological Pathology (ISUP) consensus conference recommendations. *Am J Surg Pathol*. 2013;37:1505-1517.
17. Amin MB, Edge SB, Greene FL, et al, eds. *AJCC Cancer Staging Manual*. 8<sup>th</sup> ed. New York, NY: Springer; 2017.
18. Brierley JD, Gospodarowicz MK, Wittekind CH, et al, eds. *TNM classification of malignant tumours*. 8<sup>th</sup> ed. Oxford:Wiley;2016.
19. Bonsib SM, Gibson D, Mhoon M, Greene GF. Renal sinus involvement in renal cell carcinoma. *Am J Surg Pathol*. 2000;24:451-458.
20. Bonsib SM. T2 clear cell renal cell carcinoma is a rare entity: a study of 120 clear cell renal cell carcinomas. *J Urol*. 2005;174:1199-1202.
21. Thompson RH, Leibovich BC, Cheville JC, et al. Is renal sinus fat invasion the same as perinephric fat invasion for pT3a renal cell carcinoma? *J Urol*. 2005;174:1218-1221.
22. Bonsib SM. Renal lymphatics and lymphatic involvement in sinus vein invasive (pT3b) clear cell renal cell carcinoma: a study of 40 cases. *Mod Pathol*. 2006;19:746-753.
23. Madbouly K, Al-Qahtani SM, Ghazwani Y, et al. Microvascular tumour invasion: prognostic significance in low stage renal cell carcinoma. *Urology*. 2007;69:670-674.
24. Thompson RH, Cheville JC, Lohse CM, et al. Reclassification of patients with pT3 and pT4 renal cell carcinoma improves prognostic accuracy. *Cancer*. 2005;104:53-60.
25. Ficcaro V, Novara G, Iafrate M, et al. Proposal for reclassification of the TNM staging system in patients with locally advanced (pT3-4) renal cell carcinoma according to the cancer-related outcome. *Eur Urol*. 2007;51:722-729.
26. Henriksen KJ, Meehan SM, Chang A. Non-neoplastic renal diseases are often unrecognized in adult tumor nephrectomy specimens: a review of 246 cases. *Am J Surg Pathol*. 2007;31:1703-1708.
27. Bijol V, Mendez GP, Hurwitz S, Rennke HG, Nose V. Evaluation of the non-neoplastic pathology in tumor nephrectomy specimens: predicting the risk of progressive failure. *Am J Surg Pathol*. 2006;30:575-584.
28. Bonsib SM, Pei Y. The non-neoplastic kidney in tumor nephrectomy specimens: what can it show and what is important? *Adv Annt Pathol*. 2010;17(4):235-250.
29. Garcia-Roig M, Gorin MA, Parra-Herran C, et al. Pathologic evaluation of non-neoplastic renal parenchyma in partial nephrectomy specimens. *World J Urol*, 2013; 8(4):835-839.
30. Henriksen KJ, Meehan SM, Chamng A. Nonneoplastic kidney diseases in adult tumor nephrectomy and nephroureterectomy specimens: common, harmful, yet underappreciated. *Arch Pathol Lab Med*. 2009;133(7):1012-1025.