



Protocol for the Examination of Specimens From Patients With Carcinoma of the Intrahepatic Bile Ducts

Version: IntrahepaticBileDuct 4.0.0.0

Protocol Posting Date: June 2017

Includes pTNM requirements from the 8th Edition, AJCC Staging Manual

For accreditation purposes, this protocol should be used for the following procedures AND tumor types:

Procedure	Description
Resection	Includes specimens designated hepatic resection, partial or total
Tumor Type	Description
Carcinoma	Invasive carcinomas including combined hepatocellular-cholangiocarcinoma, small cell and large cell (poorly differentiated) neuroendocrine carcinoma

This protocol is NOT required for accreditation purposes for the following:

Procedure
Biopsy
Primary resection specimen with no residual cancer (eg, following neoadjuvant therapy)
Cytologic specimens

The following tumor types should NOT be reported using this protocol:

Tumor Type
Intraductal papillary neoplasm without associated invasive carcinoma
Mucinous cystic neoplasm without associated invasive carcinoma
Well-differentiated neuroendocrine tumors of liver
Hepatocellular carcinoma and fibrolamellar carcinoma (consider the Hepatocellular Carcinoma protocol)
Lymphoma (consider the Hodgkin or non-Hodgkin Lymphoma protocols)
Sarcoma (consider the Soft Tissue protocol)

Authors

Sanjay Kakar, MD*; Chanjuan Shi, MD, PhD*; Oyedele A. Adeyi, MBBS; Wendy L. Frankel, MD; Dhanpat Jain, MD; Alyssa M. Krasinskas, MD; Mari Mino-Kenudson, MD; Timothy Pawlik, MD, MPH, PhD; Vaibhav Sahai, MD; Michael S Torbenson, MD; Jean-Nicolas Vauthey, MD; Mary K. Washington, MD, PhD

With guidance from the CAP Cancer and CAP Pathology Electronic Reporting Committees.

* Denotes primary author. All other contributing authors are listed alphabetically.

Accreditation Requirements

This protocol can be utilized for a variety of procedures and tumor types for clinical care purposes. For accreditation purposes, only the definitive primary cancer resection specimen is required to have the core and conditional data elements reported in a synoptic format.

- Core data elements are required in reports to adequately describe appropriate malignancies. For accreditation purposes, essential data elements must be reported in all instances, even if the response is “not applicable” or “cannot be determined.”
- Conditional data elements are only required to be reported if applicable as delineated in the protocol. For instance, the total number of lymph nodes examined must be reported, but only if nodes are present in the specimen.
- Optional data elements are identified with “+” and although not required for CAP accreditation purposes, may be considered for reporting as determined by local practice standards.

The use of this protocol is not required for recurrent tumors or for metastatic tumors that are resected at a different time than the primary tumor. Use of this protocol is also not required for pathology reviews performed at a second institution (ie, secondary consultation, second opinion, or review of outside case at second institution).

Synoptic Reporting

All core and conditionally required data elements outlined on the surgical case summary from this cancer protocol must be displayed in synoptic report format. Synoptic format is defined as:

- Data element: followed by its answer (response), outline format without the paired "Data element: Response" format is NOT considered synoptic.
- The data element must be represented in the report as it is listed in the case summary. The response for any data element may be modified from those listed in the case summary, including “Cannot be determined” if appropriate.
- Each diagnostic parameter pair (Data element: Response) is listed on a separate line or in a tabular format to achieve visual separation. The following exceptions are allowed to be listed on one line:
 - Anatomic site or specimen, laterality, and procedure
 - Pathologic Stage Classification (pTNM) elements
 - Negative margins, as long as all negative margins are specifically enumerated where applicable
- The synoptic portion of the report can appear in the diagnosis section of the pathology report, at the end of the report or in a separate section, but all Data element: Responses must be listed together in one location

Organizations and pathologists may choose to list the required elements in any order, use additional methods in order to enhance or achieve visual separation, or add optional items within the synoptic report. The report may have required elements in a summary format elsewhere in the report IN ADDITION TO but not as replacement for the synoptic report i.e. all required elements must be in the synoptic portion of the report in the format defined above.

CAP Laboratory Accreditation Program Protocol Required Use Date: March 2018*

* Beginning January 1, 2018, the 8th edition AJCC Staging Manual should be used for reporting pTNM.

CAP Intrahepatic Bile Duct Protocol Summary of Changes

The following data elements were modified:

Pathologic Stage Classification (pTNM, AJCC 8th Edition)

Histologic Type

Margins

Additional Pathological Findings

The following data element was deleted:

Clinical History

Surgical Pathology Cancer Case Summary

Protocol posting date: June 2017

INTRAHEPATIC BILE DUCTS:**Select a single response unless otherwise indicated.****Procedure (Note A)**

- Wedge resection
 Partial hepatectomy
 Total hepatectomy
 Other (specify): _____
 Not specified

Tumor Size

- Greatest dimension (centimeters): ____ cm
 + Additional dimensions (centimeters): ____ x ____ cm
 Cannot be determined (see "Comment")

Tumor Focality (Note B)

- Solitary (specify location): _____
 Multiple (specify locations): _____

Histologic Type (Note C)

- Intrahepatic cholangiocarcinoma
 Combined hepatocellular-cholangiocarcinoma
 Intraductal papillary neoplasm with an associated invasive carcinoma
 Mucinous cystic neoplasm with an associated invasive carcinoma
 Large cell neuroendocrine carcinoma
 Small cell neuroendocrine carcinoma
 Neuroendocrine carcinoma (poorly differentiated)[#]
 Other histologic type not listed (specify): _____

[#] Note: Select this option only if large cell or small cell cannot be determined.**Histologic Grade (Note D)**

- G1: Well-differentiated
 G2: Moderately differentiated
 G3: Poorly differentiated
 Other (specify): _____
 GX: Cannot be assessed
 Not applicable

+ Tumor Growth Pattern (Note E)

- + Mass-forming
 + Periductal infiltrating
 + Mixed mass-forming and periductal infiltrating
 + Cannot be determined

Tumor Extension (select all that apply)

- No evidence of primary tumor
 Tumor confined to the intrahepatic bile ducts (carcinoma in situ/high-grade dysplasia)
 Tumor confined to hepatic parenchyma
 Tumor involves visceral peritoneal surface
 Tumor directly invades gallbladder

+ Data elements preceded by this symbol are not required for accreditation purposes. These optional elements may be clinically important but are not yet validated or regularly used in patient management.

___ Tumor directly invades adjacent organs other than the gallbladder (specify): _____
___ Cannot be assessed

Margins (Note F)

Hepatic Parenchymal Margin

___ Cannot be assessed
___ Uninvolved by invasive carcinoma
 + Distance of invasive carcinoma from margin (millimeters or centimeters): ___ mm or ___ cm
___ Involved by invasive carcinoma

Bile Duct Margin (required only if applicable)

___ Not applicable
___ Cannot be assessed
___ Uninvolved by invasive carcinoma and high-grade intraepithelial neoplasia
 + Distance of invasive carcinoma from margin (millimeters or centimeters): ___ mm or ___ cm
___ Uninvolved by invasive carcinoma
 + Distance of invasive carcinoma from margin (millimeters or centimeters): ___ mm or ___ cm
___ Involved by invasive carcinoma
___ Involved by high-grade intraepithelial neoplasia

Other Margin (required only if applicable)

Specify margin: _____
___ Cannot be assessed
___ Uninvolved by invasive carcinoma
___ Involved by invasive carcinoma

Lymphovascular Invasion

___ Not identified
___ Present
___ Cannot be determined

+ Perineural Invasion

+ ___ Not identified
+ ___ Present
+ ___ Cannot be determined

Regional Lymph Nodes

___ No lymph nodes submitted or found

Lymph Node Examination (required only if lymph nodes are present in the specimen)

Number of Lymph Nodes Involved: _____
___ Number cannot be determined (explain): _____

Number of Lymph Nodes Examined: _____
___ Number cannot be determined (explain): _____

Pathologic Stage Classification (pTNM, AJCC 8th Edition) (Note G)

Note: Reporting of pT, pN, and (when applicable) pM categories is based on information available to the pathologist at the time the report is issued. Only the applicable T, N, or M category is required for reporting; their definitions need not be included in the report. The categories (with modifiers when applicable) can be listed on 1 line or more than 1 line.

TNM Descriptors (required only if applicable) (select all that apply)

___ m (multiple primary tumors)

+ Data elements preceded by this symbol are not required for accreditation purposes. These optional elements may be clinically important but are not yet validated or regularly used in patient management.

___ r (recurrent)
___ y (posttreatment)

Primary Tumor (pT)

- ___ pTX: Primary tumor cannot be assessed
- ___ pT0: No evidence of primary tumor
- ___ pTis: Carcinoma in situ (intraductal tumor)
- ___ pT1: Solitary tumor without vascular invasion, ≤5 cm or >5 cm
- ___ pT1a: Solitary tumor ≤5 cm without vascular invasion
- ___ pT1b: Solitary tumor >5 cm without vascular invasion
- ___ pT2: Solitary tumor with intrahepatic vascular invasion, or multiple tumors, with or without vascular invasion
- ___ pT3: Tumor perforating the visceral peritoneum
- ___ pT4: Tumor involving local extrahepatic structures by direct invasion

Regional Lymph Nodes (pN) (Note H)

- ___ pNX: Regional lymph nodes cannot be assessed
- ___ pN0: No regional lymph node metastasis
- ___ pN1: Regional lymph node metastasis present

Distant Metastasis (pM) (required only if confirmed pathologically in this case)

- ___ pM1: Distant metastasis
Specify site(s), if known: _____

+ Additional Pathologic Findings (select all that apply) (Note I)

- + Fibrosis:
 - + ___ Cirrhosis
 - + ___ Extent of fibrosis (specify name of the scheme and scale used for assessing stage of fibrosis):

- + ___ Primary sclerosing cholangitis
- + ___ Biliary stones
- + ___ Chronic hepatitis (specify type): _____
- + ___ Other (specify): _____
- + ___ None identified

+ Ancillary Studies

+ Specify: _____

+ Comment(s)

+ Data elements preceded by this symbol are not required for accreditation purposes. These optional elements may be clinically important but are not yet validated or regularly used in patient management.

Explanatory Notes

A. Application

This protocol applies only to hepatic resection specimens containing intrahepatic cholangiocarcinoma, combined hepatocellular-cholangiocarcinoma and primary high grade neuroendocrine carcinomas. Hepatocellular carcinomas and carcinomas arising in the perihilar bile ducts are staged using separate TNM systems.¹

Anatomically, the intrahepatic bile ducts extend from the periphery of the liver to the second-order bile ducts (Figure 1). The perihilar bile ducts extend from the hepatic duct bifurcation to include the extrahepatic biliary tree proximal to the origin of the cystic duct. The distal extrahepatic bile duct extends from the junction of the cystic duct-common hepatic duct to the ampulla of Vater.¹

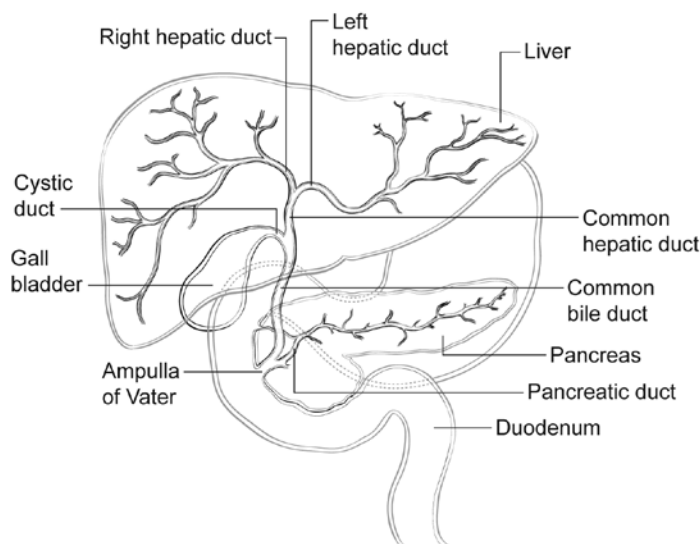


Figure 1. Anatomy of the intrahepatic and extrahepatic biliary system.

B. Tumor Focality

Sections should be prepared from each major tumor nodule, with representative sampling of smaller nodules. For purposes of staging, satellite nodules, multifocal primary cholangiocarcinomas, and intrahepatic metastases are considered to be multiple tumors.¹ In intrahepatic cholangiocarcinoma, multiple tumor deposits have been associated with poorer survival.^{2,3}

C. Histologic Type

The protocol recommends the following modified classification of the World Health Organization (WHO).⁴ In the United States, approximately 30% of the primary malignant tumors of the liver are biliary carcinomas.⁴

WHO Classification of Carcinomas of the Intrahepatic Bile Ducts (Modified)

Intrahepatic cholangiocarcinoma

Combined hepatocellular-cholangiocarcinoma

Intraductal papillary neoplasm with an associated invasive carcinoma

Mucinous cystic neoplasm with an associated invasive carcinoma

Poorly differentiated neuroendocrine carcinoma

Large cell neuroendocrine carcinoma

Small cell neuroendocrine carcinoma

Combined or mixed hepatocellular-cholangiocarcinoma should show histologic evidence of both hepatocellular and biliary differentiation by morphology, and supported by immunohistochemistry.⁴ Hepatocellular markers with high sensitivity and specificity such as arginase-1 should be included in the panel (in addition to markers like Hep Par 1),⁵ and a cholangiocarcinoma component should not be diagnosed based solely on immunoreactivity with markers like CK7, CK19, and/or MOC31, which can be positive in a subset of HCC, especially in variants like

scirrhous HCC.⁶ Discrete gland formation with or without mucin, positive staining of these areas with CK7, CK19, and/or MOC31, and negative results in these areas with hepatocellular markers is the most reliable evidence of a cholangiocarcinoma component. The proportion of each component can be provided. The size of the entire tumor is used for staging. The demographics and clinical features of combined HCC-cholangiocarcinoma such as age, sex, viral hepatitis status, and cirrhosis tend to resemble that of HCC,^{7,8} while some studies have reported molecular changes similar to cholangiocarcinoma.⁹ Many studies show that combined HCC-cholangiocarcinoma is more aggressive compared to classical HCC and has a higher recurrence rate after liver transplantation.^{10,11} Carcinosarcoma is mentioned as a histologic type in the AJCC 8th edition.

D. Histologic Grade

For cholangiocarcinomas, definitive criteria for histologic grading have not been established; however, the following quantitative grading system based on the proportion of gland formation within the tumor is suggested:

Grade X	Grade cannot be assessed
Grade 1	Well differentiated (more than 95% of tumor composed of glands)
Grade 2	Moderately differentiated (50% to 95% of tumor composed of glands)
Grade 3	Poorly differentiated (less than 49% of tumor composed of glands)

Undifferentiated category is rarely used and is reserved for tumors that do not show obvious glandular, squamous, or neuroendocrine differentiation on morphology and/or immunohistochemistry. It is more appropriate to categorize these as undifferentiated carcinomas rather than cholangiocarcinoma. This category is not included in the AJCC scheme. There is no separate grading scheme for combined hepatocellular-cholangiocarcinoma; both the components can be separately graded. This grading system is not applicable to poorly differentiated neuroendocrine carcinoma.

E. Tumor Growth Pattern

Three tumor growth patterns of intrahepatic cholangiocarcinoma are described: the mass-forming type, the periductal infiltrating type, and mixed mass-forming/periductal-infiltrating type. Mass-forming intrahepatic cholangiocarcinoma (60% of cases) forms a well-demarcated nodule growing in a radial pattern and invading the adjacent liver parenchyma (Figure 2). In contrast, the periductal-infiltrating type of cholangiocarcinoma (20% of cases) spreads in a diffuse longitudinal growth pattern along the bile duct. The remaining 20% of cases of intrahepatic cholangiocarcinoma grow in a mixed mass-forming/periductal-infiltrating pattern. Earlier studies suggested a poor outcome for diffuse periductal-infiltrating type, while some recent studies have suggested a relatively favorable prognosis.¹²⁻¹⁵

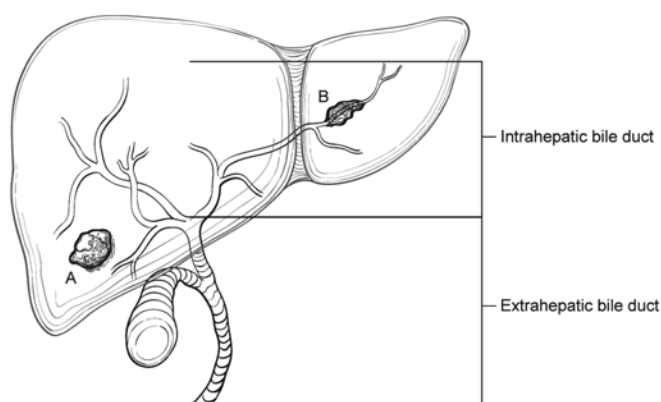


Figure 2. Tumor growth pattern in intrahepatic cholangiocarcinoma. From Amin MB et al.¹ Used with permission of the American Joint Committee on Cancer (AJCC), Chicago, Illinois. The original source for this material is the *AJCC Cancer Staging Manual*, 8th edition (2017), published by Springer Science and Business Media LLC, www.springerlink.com.

F. Margins

The evaluation of margins for total or partial hepatectomy specimens depends on the method and extent of resection. It is recommended that the surgeon be consulted to determine the critical foci within the margins that require microscopic evaluation. The transection margin of a partial hepatectomy may be large, rendering it impractical for complete examination. In this setting, grossly positive margins should be microscopically confirmed and documented. If the margins are grossly free of tumor, judicious sampling of the cut surface in the region closest to the nearest identified tumor nodule is indicated. In selected cases, adequate random sampling of the cut surface may be sufficient. The histologic examination of the bile ducts at the cut margin is recommended to evaluate the lining epithelium for in situ carcinoma or dysplasia. If the neoplasm is found near the surgical margin, the distance from the margin should be reported. For multiple tumors, the distance from the nearest tumor should be reported.

G. Pathologic Stage Classification

According to AJCC/UICC convention, the designation “T” refers to a primary tumor that has not been previously treated. The symbol “p” refers to the pathologic classification of the TNM, as opposed to the clinical classification, and is based on gross and microscopic examination. pT entails a resection of the primary tumor or biopsy adequate to evaluate the highest pT category, pN entails removal of nodes adequate to validate lymph node metastasis, and pM implies microscopic examination of distant lesions. Clinical classification (cTNM) is usually carried out by the referring physician before treatment during initial evaluation of the patient or when pathologic classification is not possible.

Pathologic staging is usually performed after surgical resection of the primary tumor. Pathologic staging depends on pathologic documentation of the anatomic extent of disease, whether or not the primary tumor has been completely removed. If a biopsied tumor is not resected for any reason (eg, when technically infeasible) and if the highest T and N categories or the M1 category of the tumor can be confirmed microscopically, the criteria for pathologic classification and staging have been satisfied without total removal of the primary cancer.

TNM Descriptors

For identification of special cases of TNM or pTNM classifications, the “m” suffix and “y,” “r,” and “a” prefixes are used. Although they do not affect the stage grouping, they indicate cases needing separate analysis.

The “m” suffix indicates the presence of multiple primary tumors in a single site and is recorded in parentheses: pT(m)NM.

The “y” prefix indicates those cases in which classification is performed during or after initial multimodality therapy (ie, neoadjuvant chemotherapy, radiation therapy, or both chemotherapy and radiation therapy). The cTNM or pTNM category is identified by a “y” prefix. The ycTNM or ypTNM categorizes the extent of tumor actually present at the time of that examination. The “y” categorization is not an estimate of tumor before multimodality therapy (ie, before initiation of neoadjuvant therapy).

The “r” prefix indicates a recurrent tumor when staged after a documented disease-free interval and is identified by the “r” prefix: rTNM.

The “a” prefix designates the stage determined at autopsy: aTNM.

T Category Considerations

Tis includes high-grade biliary intraepithelial neoplasia (BillN-3), intraductal papillary neoplasm with high-grade dysplasia, and mucinous cystic neoplasm with high-grade dysplasia. For intraepithelial lesions, a 3-tier biliary intraepithelial neoplasia classification has been proposed.¹⁶

The T categories are based on size, vascular invasion and extrahepatic spread. For invasive carcinoma associated with intraductal papillary neoplasms and mucinous cystic neoplasms, only the size of the invasive component should be used to determine the T category. The synoptic report is not required for intraductal papillary neoplasms and mucinous cystic neoplasms in the absence of an invasive component. For invasive carcinoma associated with intraductal papillary neoplasms and mucinous cystic neoplasms, only the size of the invasive component should be used to determine the T category. The invasive portion in these cases can be

multifocal. The size of the largest focus as well as cumulative size of all invasive carcinoma foci should be included in the report. Till further data becomes available, the T category should be determined based on size of the largest invasive focus. Vascular invasion includes either gross or microscopic involvement of vessels. Major vascular invasion is defined as invasion of the branches of the main portal vein or hepatic artery (first and second order branches) or as invasion of 1 or more of the 3 hepatic veins (right, middle or left).

Direct invasion of visceral peritoneum is considered as T3, while adjacent organs, including colon, duodenum, stomach, common bile duct, portal lymph nodes, abdominal wall, and diaphragm, is considered as T4 disease. Due to inconsistent criteria for defining tumors with periductal growth pattern and its unclear association with outcome, this growth pattern is no longer a part of the T classification.

Stage Groupings

Stage IA	T1a	N0	M0
Stage IB	T1b	N0	M0
Stage II	T2	N0	M0
Stage IIIA	T3	N0	M0
Stage IIIB	T4	N0	M0
	Any T	N1	M0
Stage IV	Any T	Any N	M1

Additional Descriptors

Lymphovascular Invasion

Lymphovascular invasion (LVI) indicates whether microscopic lymphovascular invasion is identified in the pathology report. LVI includes lymphatic invasion, vascular invasion, or lymphovascular invasion.

H. Lymph Nodes

Lymph node metastases have consistently been identified as an important predictor of outcome for intrahepatic cholangiocarcinoma.^{1,2,17}

The lymph node involvement pattern for intrahepatic cholangiocarcinomas varies with location in the liver (Figure 3). For carcinomas arising in the right lobe of the liver (segments 5-8), the regional lymph nodes include the hilar (common bile duct, hepatic artery, portal vein, and cystic duct), periduodenal, and peripancreatic lymph nodes. For tumors arising in the left lobe, the regional lymph nodes are the hilar, inferior phrenic and gastrohepatic lymph nodes. Nodal involvement of the celiac, periaortic, or pericaval lymph nodes is considered to be distant metastasis (pM1).¹

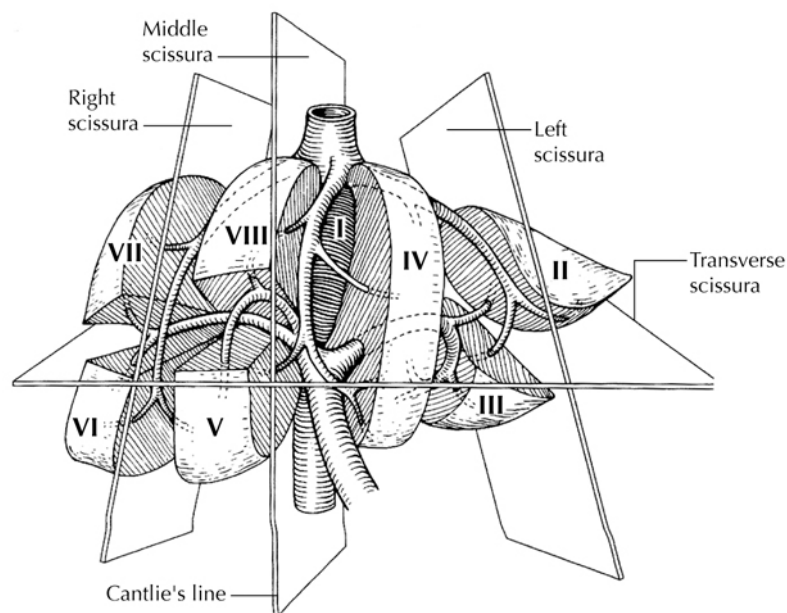


Figure 3. Segmental anatomy of the liver. From Greene et al.²² Used with permission of the American Joint Committee on Cancer (AJCC), Chicago, Illinois. The original source for this material is the *AJCC Cancer Staging Atlas* (2006) published by Springer Science and Business Media LLC, www.springerlink.com.

I. Additional Pathologic Findings

The extent of fibrosis should be reported as cirrhosis or advanced fibrosis have an adverse effect on outcome. The scoring system described by Ishak¹⁸ is recommended by the *AJCC Cancer Staging Manual*, 8th edition,¹ but other commonly used schemes (Batts-Ludwig, Metavir) can be used. The name of the staging scheme and its scale should be included.

The presence of underlying disease, such as primary sclerosing cholangitis,¹⁹ should be included in the pathology report. Biliary parasites and recurrent pyogenic cholangitis may be present along with cholangiocarcinoma in Asian countries. Hepatitis C infection, nonalcoholic fatty liver disease, obesity, and smoking are also risk factors for cholangiocarcinoma.^{20,21}

References

1. Amin MB, Edge SB, Greene FL, et al, eds. *AJCC Cancer Staging Manual*. 8th ed. New York, NY: Springer; 2017.
2. Ohtsuka M, Ito H, Kimura F, et al. Results of surgical treatment for intrahepatic cholangiocarcinoma and clinicopathological factors influencing survival. *Br J Surg*. 2002;89(12):1525-1531.
3. Sano T, Shimada K, Sakamoto Y, Ojima H, Esaki M, Kosuge T. Prognosis of perihilar carcinoma: hilar bile duct cancer versus intrahepatic cholangiocarcinoma involving the hepatic hilus. *Ann Surg Oncol*. 2008;15(2):590-599.
4. Bosman FT, Carneiro F, Hruban RH, Theise ND, eds. *WHO Classification of Tumours of the Digestive System*. Geneva, Switzerland: WHO Press; 2010.
5. Nguyen T, Phillips D, Jain D, et al. Comparison of 5 Immunohistochemical Markers of Hepatocellular Differentiation for the Diagnosis of Hepatocellular Carcinoma. *Arch Pathol Lab Med*. 2015;139(8):1028-1034.
6. Krings G, Ramachandran R, Jain D, et al. Immunohistochemical pitfalls and the importance of glypican 3 and arginase in the diagnosis of scirrhous hepatocellular carcinoma. *Mod Pathol*. 2013;26(6):782-791.
7. Yano Y, Yamamoto J, Kosuge T, et al. Combined hepatocellular and cholangiocarcinoma: a clinicopathologic study of 26 resected cases. *Jpn J Clin Oncol*. 2003;33:283-287.
8. Tang D, Nagano H, Nakamura M, et al. Clinical and pathological features of Allen's type C classification of resected combined hepatocellular and cholangiocarcinoma: a comparative study with hepatocellular carcinoma and cholangiocellular carcinoma. *J Gastrointest Surg*. 2006;10:987-998.

9. Cazals-Hatem D, Rebouissou S, Bioulac-Sage P, et al. Clinical and molecular analysis of combined hepatocellular-cholangiocarcinomas. *J Hepatol.* 2004;41(2):292-298.
10. Wu CH, Yong CC, Liew EH, et al. Combined hepatocellular carcinoma and cholangiocarcinoma: diagnosis and prognosis after resection or transplantation. *Transplant Proc.* 2016;48(4):1100-1104.
11. Sapisochin G, Fidelman N, Roberts JP, Yao FY. Mixed hepatocellular cholangiocarcinoma and intrahepatic cholangiocarcinoma in patients undergoing transplantation for hepatocellular carcinoma. *Liver Transpl.* 2011;17(8):934-942.
12. Hirohashi K, Uenishi T, Kubo S, et al. Macroscopic types of intrahepatic cholangiocarcinoma: clinicopathologic features and surgical outcomes. *Hepatogastroenterology.* 2002;49(44):326-329.
13. Shimada K, Sano T, Sakamoto Y, Esaki M, Kosuge T, Ojima H. Surgical outcomes of the mass-forming plus periductal infiltrating types of intrahepatic cholangiocarcinoma: a comparative study with the typical mass-forming type of intrahepatic cholangiocarcinoma. *World J Surg.* 2007;31(10):2016-2022.
14. Imai K, Yamamoto M, Ariizumi S. Surgery for periductal infiltrating type intrahepatic cholangiocarcinoma without hilar invasion provides a better outcome than for mass-forming type intrahepatic cholangiocarcinoma without hilar invasion. *Hepatogastroenterology.* 2010;57(104):1333-1336.
15. Uno M, Shimada K, Yamamoto Y, et al. Periductal infiltrating type of intrahepatic cholangiocarcinoma: a rare macroscopic type without any apparent mass. *Surg Today.* 2012;42(12):1189-1194.
16. Zen Y, Adsay NV, Bardadin K, et al. Biliary intraepithelial neoplasia: an international interobserver agreement study and proposal for diagnostic criteria. *Mod Pathol.* 2007;20(6):701-709.
17. Mavros MN, Economopoulos KP, Alexiou VG and Pawlik TM (2014). Treatment and prognosis for patients with intrahepatic cholangiocarcinoma: systematic review and meta-analysis. *JAMA Surg.* 149(6):565-574.
18. Ishak K, Baptista A, Bianchi L, et al. Histologic grading and staging of chronic hepatitis. *J Hepatol.* 1995;22:696-699.
19. Shaib Y, El-Serag HB. The epidemiology of cholangiocarcinoma. *Semin Liver Dis.* 2004;24(2):115-125.
20. Welzel TM, Graubard BI, El-Serag HB, et al. Risk factors for intrahepatic and extrahepatic cholangiocarcinoma in the United States: a population-based case-control study. *Clin Gastroenterol Hepatol.* 2007;5(10):1221-1228.
21. Ben-Menachem T. Risk factors for cholangiocarcinoma [comment]. *Eur J Gastroenterol Hepatol.* 2007;19(8):615-617.
22. Greene FL, Compton, CC, Fritz AG, et al, eds. *AJCC Cancer Staging Atlas.* New York, NY: Springer; 2006.