

## Protocol for the Examination of Specimens From Patients With Neuroendocrine Tumors (Carcinoid Tumors) of the Colon and Rectum

Version: ColonRectumNET 4.0.0.1

Protocol Posting Date: June 2017

Includes pTNM requirements from the 8<sup>th</sup> Edition, AJCC Staging Manual

**For accreditation purposes, this protocol should be used for the following procedures AND tumor types:**

Procedure	Description
Resection	Includes specimens designated as low anterior resection and abdominoperineal resection, total, partial, or segmental resection
Tumor Type	Description
Well-differentiated neuroendocrine tumor	

**This protocol is NOT required for accreditation purposes for the following:**

Procedure
Biopsy
Excision biopsy (transanal disk excision or polypectomy)
Primary resection specimen with no residual cancer (eg, following neoadjuvant therapy)
Recurrent tumor
Cytologic specimens

**The following tumor types should NOT be reported using this protocol:**

Tumor Type
Poorly-differentiated neuroendocrine carcinoma including small cell and large cell neuroendocrine carcinoma (consider the Colon and Rectum Carcinoma protocol)
Other epithelial carcinoma of the colon and rectum including mixed adenoneuroendocrine carcinoma (consider the Colon and Rectum Carcinoma protocol)
Gastrointestinal stromal tumor (consider the GIST protocol)
Non-GIST sarcoma (consider the Soft Tissue protocol)

### Authors

Chanjuan Shi, MD, PhD\*; Volkan Adsay, MD; Emily K. Bergsland, MD; Jordan Berlin, MD; Philip A. Branton, MD; Patrick L. Fitzgibbons, MD; Wendy L. Frankel, MD; Sanjay Kakar, MD; Veronica Klepeis, MD, PhD; David S. Klimstra, MD; Joseph T. Lewis, MD; Laura H. Tang, MD; Eugene A. Woltering, MD; Mary K. Washington, MD, PhD

With guidance from the CAP Cancer and CAP Pathology Electronic Reporting Committees.

\* Denotes primary author. All other contributing authors are listed alphabetically.

### Accreditation Requirements

This protocol can be utilized for a variety of procedures and tumor types for clinical care purposes. For accreditation purposes, only the definitive primary cancer resection specimen is required to have the core and conditional data elements reported in a synoptic format.

- Core data elements are required in reports to adequately describe appropriate malignancies. For accreditation purposes, essential data elements must be reported in all instances, even if the response is “not applicable” or “cannot be determined.”
- Conditional data elements are only required to be reported if applicable as delineated in the protocol. For instance, the total number of lymph nodes examined must be reported, but only if nodes are present in the specimen.
- Optional data elements are identified with “+” and although not required for CAP accreditation purposes, may be considered for reporting as determined by local practice standards.

The use of this protocol is not required for recurrent tumors or for metastatic tumors that are resected at a different time than the primary tumor. Use of this protocol is also not required for pathology reviews performed at a second institution (ie, secondary consultation, second opinion, or review of outside case at second institution).

### Synoptic Reporting

All core and conditionally required data elements outlined on the surgical case summary from this cancer protocol must be displayed in synoptic report format. Synoptic format is defined as:

- Data element: followed by its answer (response), outline format without the paired "Data element: Response" format is NOT considered synoptic.
- The data element should be represented in the report as it is listed in the case summary. The response for any data element may be modified from those listed in the case summary, including “Cannot be determined” if appropriate.
- Each diagnostic parameter pair (Data element: Response) is listed on a separate line or in a tabular format to achieve visual separation. The following exceptions are allowed to be listed on one line:
  - Anatomic site or specimen, laterality, and procedure
  - Pathologic Stage Classification (pTNM) elements
  - Negative margins, as long as all negative margins are specifically enumerated where applicable
- The synoptic portion of the report can appear in the diagnosis section of the pathology report, at the end of the report or in a separate section, but all Data element: Responses must be listed together in one location

Organizations and pathologists may choose to list the required elements in any order, use additional methods in order to enhance or achieve visual separation, or add optional items within the synoptic report. The report may have required elements in a summary format elsewhere in the report IN ADDITION TO but not as replacement for the synoptic report i.e. all required elements must be in the synoptic portion of the report in the format defined above.

### CAP Laboratory Accreditation Program Protocol Required Use Date: March 2018\*

\* Beginning January 1, 2018, the 8th edition AJCC Staging Manual should be used for reporting pTNM.

## CAP Colon and Rectum NET Protocol Summary of Changes

---

### Version 4.0.0.1

Corrected Notes for area on table to 2mm<sup>2</sup>

### Version 4.0.0.0

#### The following data elements were modified:

Pathologic Stage Classification (pTNM, AJCC 8th Edition)  
Histologic Type and Grade  
Mitotic Rate  
Microscopic Tumor Extension  
Margins

#### The following data elements have been deleted:

Specimen Integrity  
Specimen Size

## Surgical Pathology Cancer Case Summary

---

Protocol posting date: June 2017

### COLON AND RECTUM:

**Note: This case summary is recommended for reporting local excision and polypectomy specimens, but is not required for accreditation purposes.**

**Select a single response unless otherwise indicated.**

#### Procedure (Note A)

- Right hemicolectomy
- Transverse colectomy
- Left hemicolectomy
- Sigmoidectomy
- Low anterior resection
- Total abdominal colectomy
- Abdominoperineal resection
- Transanal disk excision (local excision)
- Polypectomy
- Other (specify): \_\_\_\_\_
- Not specified

#### Tumor Site (select all that apply) (Note B)

- Cecum
- Right (ascending) colon
- Hepatic flexure
- Transverse colon
- Splenic flexure
- Left (descending) colon
- Sigmoid colon
- Rectosigmoid junction
- Rectum
- Ileocecal valve
- Colon, not otherwise specified
- Cannot be determined (explain): \_\_\_\_\_

#### Tumor Size (Note C)

- Greatest dimension (centimeters): \_\_\_ cm (specify size of largest tumor if multiple tumors are present)
- + Additional dimensions (centimeters): \_\_\_ x \_\_\_ cm
- Cannot be determined (explain): \_\_\_\_\_

#### Tumor Focality

- Unifocal
- Multifocal (specify number of tumors): \_\_\_\_\_
- Cannot be determined

+ Data elements preceded by this symbol are not required for accreditation purposes. These optional elements may be clinically important but are not yet validated or regularly used in patient management.

**Histologic Type and Grade (Notes D and E)**

- G1: Well-differentiated neuroendocrine tumor
- G2: Well-differentiated neuroendocrine tumor
- G3: Well-differentiated neuroendocrine tumor
- Other (specify): \_\_\_\_\_
- GX: Well-differentiated neuroendocrine tumor, grade cannot be assessed
- Not applicable

*Note: For poorly differentiated neuroendocrine carcinomas, the CAP protocol for carcinoma of the colon and rectum should be used.<sup>1</sup>*

Mitotic rate and/or Ki67 labeling index is required to determine histologic grade.

**Mitotic Rate (Note E)<sup>#</sup>**

- <2 mitoses/2mm<sup>2</sup>
- 2-20 mitoses/2mm<sup>2</sup>  
 +Specify mitoses per 2mm<sup>2</sup>: \_\_\_\_\_
- >20 mitoses per 2mm<sup>2</sup>  
 +Specify mitoses per 2mm<sup>2</sup>: \_\_\_\_\_
- Cannot be determined (explain): \_\_\_\_\_
- Not applicable

*# Mitotic rate should be reported as number of mitoses per 2 mm<sup>2</sup>, by evaluating at least 10 mm<sup>2</sup> in the most mitotically active part of the tumor (eg, if using a microscope with a field diameter of 0.55 mm, count 42 high power fields [10 mm<sup>2</sup>] and divide the resulting number of mitoses by 5 to determine the number of mitoses per 2 mm<sup>2</sup> needed to assign tumor grade).*

**Ki-67 Labeling Index (Note E)**

- <3%
- 3% to 20%  
 + Specify Ki-67 percentage: \_\_\_\_\_%
- >20%  
 + Specify Ki-67 percentage: \_\_\_\_\_%
- Cannot be determined (explain): \_\_\_\_\_
- Not applicable

**Tumor Extension**

- No evidence of primary tumor
- Tumor invades the lamina propria
- Tumor invades the submucosa
- Tumor invades the muscularis propria
- Tumor invades through the muscularis propria into subserosal tissue without penetration of overlying serosa
- Tumor invades the visceral peritoneum (serosa)
- Tumor invades other organs or adjacent structures (specify): \_\_\_\_\_
- Cannot be assessed

**Margins (Note F)**

*Note: Use this section only if all margins are uninvolved and all margins can be assessed.*

- All margins are uninvolved by tumor  
 Margins examined: \_\_\_\_\_  
*Note: Margins may include proximal, distal, radial or mesenteric, deep, mucosal, and others.*  
 + Distance of tumor from closest margin (millimeters or centimeters): \_\_\_\_\_ mm or \_\_\_\_\_ cm  
 + Specify closest margin: \_\_\_\_\_

Individual margin reporting required if any margins are involved or margin involvement cannot be assessed

+ Data elements preceded by this symbol are not required for accreditation purposes. These optional elements may be clinically important but are not yet validated or regularly used in patient management.

For colectomy and rectal resection specimens onlyProximal Margin

- Cannot be assessed  
 Uninvolved by tumor  
 Involved by tumor

Distal Margin

- Cannot be assessed  
 Uninvolved by tumor  
 Involved by tumor

Radial or Mesenteric Margin

- Cannot be assessed  
 Uninvolved by tumor  
 Involved by tumor

Other Margin(s) (required only if applicable)

- Specify margin(s): \_\_\_\_\_  
 Cannot be assessed  
 Uninvolved by tumor  
 Involved by tumor

For transanal disk excision or polypectomy specimens onlyDeep Margin

- Cannot be assessed  
 Uninvolved by tumor  
 Involved by tumor

Mucosal Margin

- Cannot be assessed  
 Uninvolved by tumor  
 Involved by tumor

Other Margin(s) (required only if applicable)

- Specify margin(s): \_\_\_\_\_  
 Cannot be assessed  
 Uninvolved by tumor  
 Involved by tumor

**Lymphovascular Invasion**

- Not identified  
 Present  
 Cannot be determined

**+ Perineural Invasion**

- +  Not identified  
 +  Present  
 +  Cannot be determined

**Regional Lymph Nodes**

- No lymph nodes submitted or found

Lymph Node Examination (required only if lymph nodes are present in the specimen)

Number of Lymph Nodes Involved: \_\_\_\_\_  
 \_\_\_ Number cannot be determined (explain): \_\_\_\_\_

Number of Lymph Nodes Examined: \_\_\_\_\_  
 \_\_\_ Number cannot be determined (explain): \_\_\_\_\_

**Pathologic Stage Classification (pTNM, AJCC 8<sup>th</sup> Edition) (Note G)**

*Note: Reporting of pT, pN, and (when applicable) pM categories is based on information available to the pathologist at the time the report is issued. Only the applicable T, N, or M category is required for reporting; their definitions need not be included in the report. The categories (with modifiers when applicable) can be listed on 1 line or more than 1 line.*

TNM Descriptors (required only if applicable) (select all that apply)

\_\_\_ m (multiple primary tumors)  
 \_\_\_ r (recurrent)  
 \_\_\_ y (posttreatment)

Primary Tumor (pT)<sup>#</sup>

\_\_\_ pTX: Primary tumor cannot be assessed  
 \_\_\_ pT0: No evidence of primary tumor  
 \_\_\_ pT1: Tumor invades the lamina propria or submucosa and is ≤2 cm  
 \_\_\_ pT1a: Tumor <1 cm in greatest dimension  
 \_\_\_ pT1b: Tumor 1-2 cm in greatest dimension  
 \_\_\_ pT2: Tumor invades the muscularis propria or is >2 cm with invasion of the lamina propria or submucosa  
 \_\_\_ pT3: Tumor invades through the muscularis propria into subserosal tissue without penetration of overlying serosa  
 \_\_\_ pT4: Tumor invades visceral peritoneum (serosa) or other organs or other adjacent structures

<sup>#</sup>*Note: For any T, add "(m)" for multiple tumors [TX(#) or TX(m), where X = 1–4 and # = number of primary tumors identified<sup>##</sup>]; for multiple tumors with different T, use the highest.*

<sup>##</sup>*Example: If there are two primary tumors, only one of which invades through the muscularis propria into the subserosal tissue without penetration of the overlying serosa, we define the primary tumor as either T3(2) or T3(m).*

Regional Lymph Nodes (pN)

\_\_\_ pNX: Regional lymph nodes cannot be assessed  
 \_\_\_ pN0: No regional lymph node metastasis has occurred  
 \_\_\_ pN1: Regional lymph node metastasis

Distant Metastasis (pM) (required only if confirmed pathologically in this case)

\_\_\_ pM1: Distant metastasis  
 \_\_\_ pM1a: Metastasis confined to liver  
 \_\_\_ pM1b: Metastasis in at least one extrahepatic site (eg, lung, ovary, nonregional lymph node, peritoneum, bone)  
     Specify site(s), if known: \_\_\_\_\_  
 \_\_\_ pM1c: Both hepatic and extrahepatic metastases  
     Specify site(s), if known: \_\_\_\_\_

**+ Additional Pathologic Findings (select all that apply) (Note H)**

+ \_\_\_ None identified  
 + \_\_\_ Tumor necrosis  
 + \_\_\_ Other (specify): \_\_\_\_\_

**+ Comment(s)**

+ Data elements preceded by this symbol are not required for accreditation purposes. These optional elements may be clinically important but are not yet validated or regularly used in patient management.

## Explanatory Notes

### A. Application and Tumor Location

This protocol applies to well-differentiated neuroendocrine tumors (carcinoid tumors) of the colon and rectum. Poorly differentiated neuroendocrine carcinomas (including small cell carcinomas and large cell neuroendocrine carcinomas) and tumors with mixed glandular/neuroendocrine differentiation are not included<sup>1</sup>.

Because of site-specific similarities in histology, immunohistochemistry, and histochemistry, neuroendocrine tumors of the digestive tract have traditionally been subdivided into those of foregut, midgut, and hindgut origin (Table 1). In general, the distribution pattern along the gastrointestinal (GI) tract parallels that of the progenitor cell type, and the anatomic site of origin of GI neuroendocrine tumors is an important predictor of clinical behavior.<sup>2</sup>

**Table 1. Site of Origin of Gastrointestinal Neuroendocrine Tumors**

	Foregut Tumors	Midgut Tumors	Hindgut Tumors
<i>Site</i>	<i>Stomach, Proximal Duodenum</i>	<i>Jejunum, Ileum, Appendix, Proximal Colon</i>	<i>Distal Colon, Rectum</i>
Immunohistochemistry Chromogranin A Synaptophysin Serotonin	86%-100% + 50% + 33% + <sup>17</sup>	82%-92% + 95%-100% + 86% + <sup>17</sup>	40%-58% + 94%-100% + 45%-83% + <sup>3,5,6,17</sup>
Other Immunohistochemical Markers	Rarely, + for pancreatic polypeptide, histamine, gastrin, vasoactive intestinal peptide (VIP), or adrenocorticotrophic hormone (ACTH)	Prostatic acid phosphatase + in 20%-40% <sup>9,17</sup>	Prostatic acid phosphatase + in 20%-82% <sup>9</sup>
Carcinoid syndrome	Rare	5%-39% <sup>6,7</sup>	Rare

### B. Site-Specific Features

Rectal neuroendocrine tumors are not uncommon and constitute approximately one-quarter of GI neuroendocrine tumors.<sup>3</sup> They are usually small, solitary, and clinically silent, most commonly occurring 4 cm to 13 cm from the anal verge. Mitotically inactive rectal neuroendocrine tumors or those smaller than 2.0 cm are almost always clinically indolent.<sup>4</sup> Metastases and carcinoid syndrome are very rare. Colonic neuroendocrine tumors outside the ileocecal region and rectum are extremely rare; most are large, bulky, highly invasive tumors that are metastatic at presentation. Two-thirds arise within the cecum or right colon. Many well-differentiated neuroendocrine tumors involving the ileocecal valve represent tumors arising in the terminal ileum, rather than in the large bowel.

### C. Tumor Size

For neuroendocrine tumors in any part of the gastrointestinal tract, size greater than 2.0 cm is associated with a higher risk of lymph node metastasis. Rectal carcinoids smaller than 1.0 cm are almost always clinically indolent, and local excision is generally considered sufficient for tumors 1.0 cm or smaller, as well as many tumors between 1.0 cm and 2.0 cm. More extensive procedures (eg, right hemicolectomy and abdominoperineal resection) are usually reserved for patients with rectal tumors larger than 2.0 cm, rectal tumors with regional metastasis, and most colonic neuroendocrine tumors.

### D. Histologic Type

The World Health Organization (WHO) classifies neuroendocrine neoplasms as well-differentiated neuroendocrine tumors (either the primary tumor or metastasis) and poorly differentiated neuroendocrine carcinomas.<sup>5-8</sup> Historically, well-differentiated neuroendocrine tumors have been referred to as “carcinoid” tumors, a term which may cause confusion because clinically a carcinoid tumor is a serotonin-producing tumor associated with functional manifestations of carcinoid syndrome. The use of the term “carcinoid” for neuroendocrine tumor reporting is therefore discouraged for these reasons.

Classification of neuroendocrine tumors is based upon size, functionality, site, and invasion. Functioning tumors are those associated with clinical manifestations of hormone production or secretion of measurable amounts of active hormone; immunohistochemical demonstration of hormone production is not equivalent to clinically apparent functionality.

Although specific histologic patterns in well-differentiated neuroendocrine tumors, such as trabecular, insular, and glandular, roughly correlate with tumor location,<sup>4</sup> these patterns have not been clearly shown independently to predict response to therapy or risk of nodal metastasis and are rarely reported in clinical practice. Immunohistochemistry and other ancillary techniques are generally not required to diagnose well-differentiated neuroendocrine tumors. Specific markers that may be used to establish neuroendocrine differentiation include chromogranin A, synaptophysin, and CD56.<sup>7</sup> Because of their relative sensitivity and specificity, chromogranin A and synaptophysin are recommended. It should be noted that hindgut neuroendocrine tumors often do not express appreciable amounts of chromogranin A. Rectal neuroendocrine tumors express prostatic acid phosphatase, a potential diagnostic pitfall for tumors arising in male patients.<sup>9</sup>

### E. Histologic Grade

Cytologic atypia in well-differentiated neuroendocrine tumors has no impact on clinical behavior of these tumors. The WHO classification<sup>6</sup> and others<sup>10</sup> use mitotic rate and/or Ki-67 index as one of the criteria for potential for aggressive behavior. Mitotic rate should be reported as number of mitoses per 2 mm<sup>2</sup>, by evaluating at least 10 mm<sup>2</sup> in the most mitotically active part of the tumor. Only clearly identifiable mitotic figures should be counted; hyperchromatic, karyorrhectic, or apoptotic nuclei are excluded. Because of variations in field size, the number of high-power fields (HPF) (at 40X magnification) for 10 mm<sup>2</sup> (thereby 2 mm<sup>2</sup>) must be determined for each microscope (Table 2). For example, if using a microscope with a field diameter of 0.55 mm, count 42 HPF and divide the resulting number of mitoses by 5 to determine the number of mitoses per 2 mm<sup>2</sup> needed to assign tumor grade.

**Table 2. Number of HPF Required for 10 mm<sup>2</sup> Using Microscopes With Different Field Diameter**

Field Diameter (mm)	Area (mm <sup>2</sup> )	Number of HPF for 10 mm <sup>2</sup>
0.40	0.125	80
0.41	0.132	75
0.42	0.139	70
0.43	0.145	69
0.44	0.152	65
0.45	0.159	63
0.46	0.166	60
0.47	0.173	58
0.48	0.181	55
0.49	0.189	53
0.50	0.196	50
0.51	0.204	49
0.52	0.212	47
0.53	0.221	45
0.54	0.229	44
0.55	0.238	42
0.56	0.246	41
0.57	0.255	39
0.58	0.264	38



0.59	0.273	37
0.60	0.283	35
0.61	0.292	34
0.62	0.302	33
0.63	0.312	32
0.64	0.322	31
0.65	0.332	30
0.66	0.342	29
0.67	0.353	28
0.68	0.363	28
0.69	0.374	28

Ki-67 index is reported as percent positive tumor cells in area of highest nuclear labeling (“hot spot”), although the precise method of assessment has not been standardized. A number of methods have used to assess Ki-67 index, including automatic counting and “eyeballing”.<sup>11,12</sup> Automated counting is not widely available and requires careful modification of the software to circumvent the inaccuracies.<sup>11</sup> Eye-balling can be used for most tumors; however, for tumors with Ki-67 index close to grade cut-offs, it is recommended to perform the manual count on the print of camera-captured image of the hot spot. It has been recommended that a minimum of 500 tumor cells be counted to determine the Ki-67 index and a notation is made if less cells are available. Grade assigned based on Ki-67 index is typically higher than that based on mitotic count, and the case is assigned to the higher of the 2 if both methods are performed.<sup>6</sup>

It is important to note that there are a small group of well-differentiated neuroendocrine tumors with a Ki-67 index >20% and a mitotic rate usually <20 per 10 HPF. In WHO-2010, these tumors were considered as G3 poorly differentiated neuroendocrine carcinomas. However, they have typical morphology of well-differentiated tumors. Previous studies (most on pancreatic neuroendocrine tumors) have demonstrated that these tumors have a worse prognosis than grade 2 (Ki-67=3-20 % and mitosis <20/10 HPF) neuroendocrine tumors, but they are not as aggressive as poorly differentiated neuroendocrine carcinomas.<sup>13</sup> In addition, these tumors do not have the genetic abnormalities seen in poorly differentiated neuroendocrine carcinomas.<sup>14</sup> Furthermore, unlike poorly differentiated neuroendocrine carcinomas, they are less responsive to platinum-based chemotherapy.<sup>15</sup> In WHO-2017 blue book of endocrine tumors and AJCC 8<sup>th</sup> edition, those with typical morphology of well-differentiated tumors are classified as “well differentiated neuroendocrine tumor” but as grade 3. Here, the updated classification for “endocrine” tumors is adapted, and following grading scheme is recommended to grade well-differentiated gastroenteropancreatic neuroendocrine tumors (Table 3).

**Table 3**

**Recommended Grading System for Well-Differentiated Gastroenteropancreatic Neuroendocrine Tumors.**

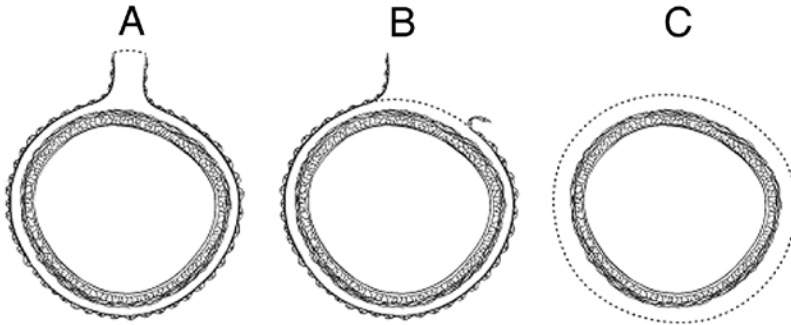
Grade	Mitotic Rate (per 2mm <sup>2</sup> )	Ki-67 index (%)
Well-differentiated neuroendocrine tumor, G1	<2	<3
Well-differentiated neuroendocrine tumor, G2	2-20	3-20
Well-differentiated neuroendocrine tumor, G3	>20	>20

**F. Circumferential (Radial or Mesenteric) Margin**

In addition to addressing the proximal and distal margins, assessment of the circumferential (radial) margin is necessary for any segment of gastrointestinal tract either unencased (Figure, C) or incompletely encased by peritoneum (Figure, B). The circumferential margin represents the adventitial soft-tissue margin closest to the deepest penetration of tumor and is created surgically by blunt or sharp dissection of the retroperitoneal or subperitoneal aspect, respectively. The distance between the tumor and circumferential (radial) margin should be reported, if applicable. The circumferential (radial) margin is considered positive if the tumor is present at the

nonperitonealized surface. This assessment includes tumor within a lymph node as well as direct tumor extension, but if circumferential (radial) margin positivity is based solely on intranodal tumor, this should be so stated.

The mesenteric resection margin is the only relevant circumferential margin in segments completely encased by peritoneum (eg, transverse colon) (Figure, A). Involvement of this margin should be reported even if tumor does not penetrate the serosal surface.



A, Mesenteric margin in viscus completely encased by peritoneum (dotted line). B, Circumferential (radial) margin (dotted line) in viscus incompletely encased by peritoneum. C, Circumferential (radial) margin (dotted line) in viscus completely unencased by peritoneum.

### G. Pathologic Stage Classification

The TNM staging system for neuroendocrine tumors of the colon and rectum of the American Joint Committee on Cancer (AJCC) and the International Union Against Cancer (UICC) is recommended.<sup>13</sup>

By AJCC/UICC convention, the designation “T” refers to a primary tumor that has not been previously treated. The symbol “p” refers to the pathologic classification of the TNM, as opposed to the clinical classification, and is based on gross and microscopic examination. pT entails a resection of the primary tumor or biopsy adequate to evaluate the highest pT category, pN entails removal of nodes adequate to validate lymph node metastasis, and pM implies microscopic examination of distant lesions. Clinical classification (cTNM) is usually carried out by the referring physician before treatment, during initial evaluation of the patient or when pathologic classification is not possible.

Pathologic staging is usually performed after surgical resection of the primary tumor. Pathologic staging depends on pathologic documentation of the anatomic extent of disease, whether or not the primary tumor has been completely removed. If a biopsied tumor is not resected for any reason (eg, when technically unfeasible) and if the highest T and N categories or the M1 category of the tumor can be confirmed microscopically, the criteria for pathologic classification and staging have been satisfied without total removal of the primary cancer.

### TNM Descriptors

For identification of special cases of TNM or pTNM classifications, the “m” suffix and “y,” “r,” and “a” prefixes are used. Although they do not affect the stage grouping, they indicate cases needing separate analysis.

The “m” suffix indicates the presence of multiple primary tumors in a single site and is recorded in parentheses: pT(m)NM.

The “y” prefix indicates those cases in which classification is performed during or following initial multimodality therapy (ie, neoadjuvant chemotherapy, radiation therapy, or both chemotherapy and radiation therapy). The cTNM or pTNM category is identified by a “y” prefix. The ycTNM or ypTNM categorizes the extent of tumor actually present at the time of that examination. The “y” categorization is not an estimate of tumor prior to multimodality therapy (ie, before initiation of neoadjuvant therapy).

The “r” prefix indicates a recurrent tumor when staged after a documented disease-free interval and is identified by the “r” prefix: rTNM.

The “a” prefix designates the stage determined at autopsy: aTNM.

### N Category Considerations

The regional lymph nodes of the colon and rectum are as follows:

Cecum: Pericolic, anterior cecal, posterior cecal, ileocolic, right colic

Ascending colon: Pericolic, ileocolic, right colic, middle colic

Hepatic flexure: Pericolic, middle colic, right colic

Transverse colon: Pericolic, middle colic

Splenic flexure: Pericolic, middle colic, left colic, inferior mesenteric

Descending colon: Pericolic, left colic, inferior mesenteric, sigmoid

Sigmoid colon: Pericolic, inferior mesenteric, superior rectal (hemorrhoidal), sigmoidal, sigmoid mesenteric

Rectosigmoid: Pericolic, perirectal, left colic, sigmoid mesenteric, sigmoidal, inferior mesenteric, superior rectal (hemorrhoidal), middle rectal (hemorrhoidal)

Rectum: Perirectal, sigmoid mesenteric, inferior mesenteric, lateral sacral, presacral, internal iliac, sacral promontory (Gerota’s), internal iliac, superior rectal (hemorrhoidal), middle rectal (hemorrhoidal), inferior rectal (hemorrhoidal)

### H. Additional Pathologic Findings

Coagulative tumor necrosis, usually punctate, may indicate more aggressive behavior<sup>17</sup> and should be reported.

### References

- Kakar S, Shi C, Berho ME, et al. Protocol for the Examination of Specimens From Patients With Primary Carcinoma of the Colon and Rectum. 2017. Available at [www.cap.org/cancerprotocols](http://www.cap.org/cancerprotocols).
- Rorstad O. Prognostic indicators for carcinoid neuroendocrine tumors of the gastrointestinal tract. *J Surg Oncol*. 2005;89(3):151-160.
- Modlin IM, Lye KD, Kidd M. A 5-decade analysis of 13,715 carcinoid tumors. *Cancer*. 2003;97(4):934-959.
- Soga J. Carcinoids of the colon and ileocecal region: a statistical evaluation of 363 cases collected from the literature. *J Exp Clin Cancer Res*. 1998;17(2):139-148.
- Graeme-Cook F. Neuroendocrine tumors of the GI tract and appendix. In: Odze RD, Goldblum JR, Crawford JM, eds. *Surgical Pathology of the GI Tract, Liver, Biliary Tract, and Pancreas*. Philadelphia, PA: Saunders; 2004:483-504.
- Bosman FT, Carneiro F, Hruban RH, Theise ND, eds. *WHO Classification of Tumours of the Digestive System*. Geneva, Switzerland: WHO Press; 2010.
- Williams GT. Endocrine tumours of the gastrointestinal tract: selected topics. *Histopathology*. 2007;50(1):30-41.
- Kloppel G, Perren A, Heitz PU. The gastroenteropancreatic neuroendocrine cell system and its tumors: the WHO classification. *Ann N Y Acad Sci*. 2004;1014:13-27.
- Sobin LH, Hjermsstad BM, Sesterhenn IA, Helwig EB. Prostatic acid phosphatases activity in carcinoid tumors. *Cancer*. 1986;58(1):136-138.
- Rindi G, Kloppel G, Couvelard A, et al. TNM staging of midgut and hindgut (neuro) endocrine tumors: a consensus proposal including a grading system. *Virchows Arch*. 2007;451(4):757-762.
- Tang LH, Gonen M, Hedvat C, Modlin I, Klimstra DS. Objective quantification of the Ki67 proliferative index in neuroendocrine tumors of gastroenteropancreatic system: a comparison of digital image analysis with manual methods. *Am J Surg Pathol*. 2012;36(12):1761-1770.
- Reid MD, Bagci P, Ohike N, et al. Calculation of the Ki67 index in pancreatic neuroendocrine tumors: a comparative analysis of four counting methodologies. *Mod Pathol*. 2016;29(1):93.
- Shi C, Klimstra DS. Pancreatic neuroendocrine tumors: pathologic and molecular characteristics. *Semin Diagn Pathol*. 2014;31(6):498-511.
- Yachida S, Vakiani E, White CM, et al. Small cell and large cell neuroendocrine carcinomas of the pancreas are genetically similar and distinct from well-differentiated pancreatic neuroendocrine tumors. *Am J Surg Pathol*. 2012;36(2):173-84.
- Sorbye H, Strosberg J, Baudin E, Klimstra DS, Yao JC. Gastroenteropancreatic high-grade neuroendocrine carcinoma. *Cancer*. 2014;120(18):2814-2823.

16. Amin MB, Edge SB, Greene FL, et al, eds. *AJCC Cancer Staging Manual*. 8th ed. New York, NY: Springer; 2017.
17. Rindi G, Kloppel G, Alhman H, et al; and all other Frascati Consensus Conference participants; European Neuroendocrine Tumor Society (ENETS). TNM staging of foregut (neuro)endocrine tumors: a consensus proposal including a grading system. *Virchows Arch*. 2006;449(4):395-401.