

Protocol for the Examination of Specimens From Patients With Ductal Carcinoma In Situ (DCIS) of the Breast

Protocol applies to DCIS without invasive carcinoma or microinvasion.

Based on AJCC/UICC TNM, 7th edition

Protocol web posting date: December 2013

Procedures

- Complete Excision (Less Than Total Mastectomy, Including Specimens Designated Biopsy, Lumpectomy, Quadrantectomy, and Partial Mastectomy; With or Without Axillary Contents)
- Mastectomy (Total, With or Without Axillary Contents; Modified Radical; Radical)

Authors

Susan C. Lester, MD, PhD, FCAP*

Department of Pathology, Brigham and Women's Hospital, Boston, Massachusetts

Shikha Bose, MD, FCAP

Department of Pathology and Laboratory Medicine, Cedars-Sinai Medical Center, Los Angeles, California

Yunn-Yi Chen, MD, PhD, FCAP

Department of Pathology, UCSF Medical Center, San Francisco, California

James L. Connolly, MD, FCAP

Department of Pathology, Beth Israel Deaconess Medical Center, Boston, Massachusetts

Monica de Baca, MD, FCAP

Physicians Laboratory, Sioux Falls, South Dakota

Patrick L. Fitzgibbons, MD, FCAP

Department of Pathology, St. Jude Medical Center, Fullerton, California

Daniel F. Hayes, MD, Department of Medical Oncology, University of Michigan Medical

Center, Ann Arbor, Michigan

Celina Kleer, MD, FCAP

Department of Pathology, University of Michigan Medical Center, Ann Arbor, Michigan

Frances P. O'Malley, MD, FCAP

Department of Pathology and Laboratory Medicine, Mount Sinai Hospital, Toronto, University of Toronto, Ontario, Canada

David L. Page, MD, FCAP

Department of Pathology, Vanderbilt University Medical Center, Nashville, Tennessee

Barbara L. Smith, MD, PhD

Department of Surgical Oncology, Massachusetts General Hospital, Boston, Massachusetts

Donald L. Weaver, MD, FCAP

Department of Pathology, College of Medicine and Vermont Cancer Center, University of Vermont, Burlington, Vermont

Eric Winer, MD

Department of Medical Oncology, Dana-Farber Cancer Institute, Boston, Massachusetts

Jean F. Simpson, MD, FCAP†

Department of Pathology, Vanderbilt University Medical Center, Nashville, Tennessee

For the Members of the Cancer Committee, College of American Pathologists

* Denotes primary author. † Denotes senior author. All other contributing authors are listed alphabetically.

© 2013 College of American Pathologists (CAP). All rights reserved.

The College does not permit reproduction of any substantial portion of these protocols without its written authorization. The College hereby authorizes use of these protocols by physicians and other health care providers in reporting on surgical specimens, in teaching, and in carrying out medical research for nonprofit purposes. This authorization does not extend to reproduction or other use of any substantial portion of these protocols for commercial purposes without the written consent of the College.

The CAP also authorizes physicians and other health care practitioners to make modified versions of the Protocols solely for their individual use in reporting on surgical specimens for individual patients, teaching, and carrying out medical research for non-profit purposes.

The CAP further authorizes the following uses by physicians and other health care practitioners, in reporting on surgical specimens for individual patients, in teaching, and in carrying out medical research for non-profit purposes: (1) **Dictation** from the original or modified protocols for the purposes of creating a text-based patient record on paper, or in a word processing document; (2) **Copying** from the original or modified protocols into a text-based patient record on paper, or in a word processing document; (3) The use of a **computerized system** for items (1) and (2), provided that the Protocol data is stored intact as a single text-based document, and is not stored as multiple discrete data fields.

Other than uses (1), (2), and (3) above, the CAP does not authorize any use of the Protocols in electronic medical records systems, pathology informatics systems, cancer registry computer systems, computerized databases, mappings between coding works, or any computerized system without a written license from the CAP.

Any public dissemination of the original or modified Protocols is prohibited without a written license from the CAP.

The College of American Pathologists offers these protocols to assist pathologists in providing clinically useful and relevant information when reporting results of surgical specimen examinations of surgical specimens. The College regards the reporting elements in the "Surgical Pathology Cancer Case Summary" portion of the protocols as essential elements of the pathology report. However, the manner in which these elements are reported is at the discretion of each specific pathologist, taking into account clinician preferences, institutional policies, and individual practice.

The College developed these protocols as an educational tool to assist pathologists in the useful reporting of relevant information. It did not issue the protocols for use in litigation, reimbursement, or other contexts. Nevertheless, the College recognizes that the protocols might be used by hospitals, attorneys, payers, and others. Indeed, effective January 1, 2004, the Commission on Cancer of the American College of Surgeons mandated the use of the required data elements of the protocols as part of its Cancer Program Standards for Approved Cancer Programs. Therefore, it becomes even more important for pathologists to familiarize themselves with these documents. At the same time, the College cautions that use of the protocols other than for their intended educational purpose may involve additional considerations that are beyond the scope of this document.

The inclusion of a product name or service in a CAP publication should not be construed as an endorsement of such product or service, nor is failure to include the name of a product or service to be construed as disapproval.

CAP DCIS Protocol Revision History

Version Code

The definition of the version code can be found at www.cap.org/cancerprotocols.

Version: DCIS 3.2.0.0

Summary of Changes

The following change has been made since the June 2012 release.

Complete Excision and Mastectomy

Procedure: "Radioactive seed localization" was added.

Size (Extent) of DCIS: Measurements were changed from centimeters (cm) to millimeters (mm).

Lymph Nodes (required only if lymph nodes are present in the specimen): A subheading and note were added, measurements were changed from centimeters (cm) to millimeters (mm), and the reporting of size of largest metastatic deposit was changed from required to optional, as follows.

Lymph Node Involvement (required only if 1 or more lymph nodes have tumor cells identified)

Number of lymph nodes with macrometastases (>2 mm): ____

Number of lymph nodes with micrometastases (>0.2 mm to 2 mm and/or >200 cells): ____

Number of lymph nodes with isolated tumor cells (≤0.2 mm and ≤200 cells)#: ____

+ Size of largest metastatic deposit: ____

Reporting the number of lymph nodes with isolated tumor cells is applicable only in the absence of macrometastasis or micrometastasis in other lymph nodes.

Regional Lymph Nodes (pN): The following note was added to pN1, pN2a, and pN3a:

Nodes containing only ITCs are excluded from the total positive node count for purposes of N classification but should be included in the total number of nodes evaluated.

Ancillary Studies: Reporting on ancillary studies was deleted and the following note was added:

Note: For estrogen receptor (ER) and progesterone receptor (PgR) reporting, the CAP Breast Biomarker Template should be used. Pending biomarker studies should be listed in the Comments section of this report.

Explanatory Notes

K. Pathologic Staging

Pathologic T: The following sentence was added:

On rare occasions, the tumor size is obtained from a previous core needle biopsy specimen, as the tumor in the core may be larger than the tumor in the excision specimen.

M. Hormone Receptors: This note was deleted and the remaining notes relabeled as appropriate.

References: References #38 through #47 were deleted.

Measurements were changed from centimeters (cm) to millimeters (mm) throughout.

Surgical Pathology Cancer Case Summary

Protocol web posting date: December 2013

DCIS OF THE BREAST: Complete Excision (Less Than Total Mastectomy, Including Specimens Designated Biopsy, Lumpectomy, Quadrantectomy, and Partial Mastectomy; With or Without Axillary Contents) and Mastectomy (Total, With or Without Axillary Contents; Modified Radical; Radical)

Select a single response unless otherwise indicated.

Specimen Identification

The following 4 elements identifying the specimen may be listed separately or on 1 line:

Procedure (Note A)

- Excision without wire-guided localization
- Excision with wire-guided localization
- Total mastectomy (including nipple and skin)
- Radioactive seed localization
- Other (specify): _____
- Not specified

Lymph Node Sampling (select all that apply) (required only if lymph nodes are present in the specimen) (Note B)

- Sentinel lymph node(s)
- Axillary dissection (partial or complete dissection)
- Lymph nodes present within the breast specimen (ie, intramammary lymph nodes)
- Other lymph nodes (eg, supraclavicular or location not identified)
Specify location, if provided: _____

Specimen Laterality

- Right
- Left
- Not specified

+ Tumor Site (select all that apply)

- + Upper outer quadrant
- + Lower outer quadrant
- + Upper inner quadrant
- + Lower inner quadrant
- + Central
- + Nipple
- + Position: ___ o'clock
- + Other (specify): _____
- + Not specified

+ Data elements preceded by this symbol are not required. However, these elements may be clinically important but are not yet validated or regularly used in patient management.

Size (Extent) of DCIS (Note C and Figure)

Estimated size (extent) of DCIS (greatest dimension using gross and microscopic evaluation):

at least ___ mm

+ Additional dimensions ___ x ___ mm

+ Number of blocks with DCIS: ___

+ Number of blocks examined: ___

*Note: The size (extent) of DCIS is an estimation of the volume of breast tissue occupied by DCIS.***Histologic Type (Note D)**

___ Ductal carcinoma in situ. Classified as Tis (DCIS) or Tis (Paget)

+ Architectural Patterns (select all that apply) (Note E)

+ ___ Comedo

+ ___ Paget disease (DCIS involving nipple skin)

+ ___ Cribriform

+ ___ Micropapillary

+ ___ Papillary

+ ___ Solid

+ ___ Other (specify: _____)

Nuclear Grade (Note F)

___ Grade I (low)

___ Grade II (intermediate)

___ Grade III (high)

Necrosis (Note G)

___ Not identified

___ Present, focal (small foci or single cell necrosis)

___ Present, central (expansive "comedo" necrosis)

Margins (select all that apply) (Note H)

___ Margins cannot be assessed

___ Margin(s) uninvolved by DCIS

Distance from closest margin: ___ mm

+ Specify closest margin: _____

+ Specify margins:

+ Distance from superior margin: ___ mm

+ Distance from inferior margin: ___ mm

+ Distance from medial margin: ___ mm

+ Distance from lateral margin: ___ mm

+ Distance from anterior margin: ___ mm

+ Distance from posterior margin: ___ mm

+ Distance from other specified margin: ___ mm

+ Designation of margin: _____

___ Margin(s) positive for DCIS

+ Specify margin(s): _____

- + For positive margins, specify extent (focal, minimal/moderate, or extensive):
 - + Anterior: _____
 - + Posterior: _____
 - + Superior: _____
 - + Inferior: _____
 - + Medial: _____
 - + Lateral: _____
 - + Other (specify margin: _____)

Note: Margin status is listed as "positive" if there is ink on carcinoma (ie, the distance is 0 mm). If the margin is not positive, then a distance from the margin may be listed. Distances can be specific measurements or expressed as greater than or less than a measurement.

+ Treatment Effect: Response to Presurgical (Neoadjuvant) Therapy (Note I)

- + ___ No known presurgical therapy
- + ___ No definite response to presurgical therapy
- + ___ Probable or definite response to presurgical therapy

Lymph Nodes (required only if lymph nodes are present in the specimen) (Note J)

Total number of nodes examined (sentinel and nonsentinel): _____
 Number of sentinel nodes examined: _____

Lymph Node Involvement (required only if 1 or more lymph nodes have tumor cells identified)

- Number of lymph nodes with macrometastases (>2 mm): _____
- Number of lymph nodes with micrometastases (>0.2 mm to 2 mm and/or >200 cells): _____
- Number of lymph nodes with isolated tumor cells (≤0.2 mm and ≤200 cells)#: _____
- + Size of largest metastatic deposit: _____

Reporting the number of lymph nodes with isolated tumor cells is applicable only in the absence of macrometastasis or micrometastasis in other lymph nodes.

Note: The sentinel node is usually the first involved lymph node. In the unusual situation in which a sentinel node is not involved by metastatic carcinoma, but a nonsentinel node is involved, this information should be included in a note.

- + Extranodal extension:
 - + ___ Present
 - + ___ Not identified
 - + ___ Indeterminate

+ Method of Evaluation of Sentinel Lymph Nodes (select all that apply)

- + ___ Hematoxylin and eosin (H&E), 1 level
- + ___ H&E, multiple levels
- + ___ Immunohistochemistry
- + ___ Sentinel lymph node biopsy not performed
- + ___ Other (specify): _____

Pathologic Staging (pTNM) (Note K)

TNM Descriptors (required only if applicable) (select all that apply)

- ___ r (recurrent)
- ___ y (posttreatment)

+ Data elements preceded by this symbol are not required. However, these elements may be clinically important but are not yet validated or regularly used in patient management.

Primary Tumor (pT)

- ___ pTis (DCIS): Ductal carcinoma in situ
 ___ pTis (Paget): Paget disease of the nipple *not* associated with invasive carcinoma and/or carcinoma in situ (DCIS and/or LCIS) in the underlying breast parenchyma.

Note: If there has been a prior core needle biopsy, the pathologic findings from the core, if available, should be incorporated in the T classification. If invasive carcinoma or microinvasion were present on the core, the protocol for invasive carcinomas of the breast¹ should be used and should incorporate this information.

Regional Lymph Nodes (pN) (choose a category if lymph nodes received with the specimen; immunohistochemistry and/or molecular studies are not required)

Note: If internal mammary lymph nodes, infraclavicular nodes, or supraclavicular lymph nodes are included in the specimen, consult the AJCC Staging Manual for additional lymph node categories.

Modifier (required only if applicable)

- ___ (sn): Only sentinel node(s) evaluated. If 6 or more nodes (sentinel or nonsentinel) are removed, this modifier should not be used.

Category (pN)

- ___ Not applicable
 ___ pNX: Regional lymph nodes cannot be assessed
 ___ pN0: No regional lymph node metastasis identified histologically

Note: Isolated tumor cell clusters (ITC) are defined as small clusters of cells not greater than 0.2 mm or single tumor cells, or a cluster of fewer than 200 cells in a single histologic cross-section.[#] ITCs may be detected by routine histology or by immunohistochemical (IHC) methods. Nodes containing only ITCs are excluded from the total positive node count for purposes of N classification but should be included in the total number of nodes evaluated.

- ___ pN0 (i-): No regional lymph node metastases histologically, negative IHC
 ___ pN0 (i+): Malignant cells in regional lymph node(s) no greater than 0.2 mm and no more than 200 cells (detected by H&E or IHC including ITC)
 ___ pN0 (mol-): No regional lymph node metastases histologically, negative molecular findings (reverse transcriptase polymerase chain reaction [RT-PCR])
 ___ pN0 (mol+): Positive molecular findings (RT-PCR), but no regional lymph node metastases detected by histology or IHC
 ___ pN1mi: Micrometastases (greater than 0.2 mm and/or more than 200 cells, but none greater than 2.0 mm).
 ___ pN1a: Metastases in 1 to 3 axillary lymph nodes, at least 1 metastasis greater than 2.0 mm^{##}
 ___ pN2a: Metastases in 4 to 9 axillary lymph nodes (at least 1 tumor deposit greater than 2.0 mm)^{##}
 ___ pN3a: Metastases in 10 or more axillary lymph nodes (at least 1 tumor deposit greater than 2.0 mm)^{##}

Approximately 1000 tumor cells are contained in a 3-dimensional 0.2-mm cluster. Thus, if more than 200 individual tumor cells are identified as single dispersed tumor cells or as a nearly confluent elliptical or spherical focus in a single histologic section of a lymph node, there is a high probability that more than 1000 cells are present in the lymph node. In these situations, the node should be classified as containing a micrometastasis (pN1mi). Cells in different lymph node cross-sections or longitudinal sections or levels of the block are not added together; the 200 cells must be in a single node profile even if the node has been thinly sectioned into multiple slices. It is recognized that there is substantial overlap between the upper limit of the ITC and the lower limit of the micrometastasis categories due to inherent limitations in pathologic nodal evaluation and detection of minimal tumor burden in lymph nodes. Thus, the threshold of 200 cells in a single cross-section is a guideline to help pathologists distinguish between these 2 categories. The pathologist should use judgment regarding whether it is likely that the cluster of cells represents a true micrometastasis or is simply a small group of isolated tumor cells.

⁺ Data elements preceded by this symbol are not required. However, these elements may be clinically important but are not yet validated or regularly used in patient management.

Nodes containing only ITCs are excluded from the total positive node count for purposes of N classification but should be included in the total number of nodes evaluated.

Distant Metastasis (pM) (required only if present)

Not applicable

pM1: Distant detectable metastasis as histologically proven larger than 0.2 mm

Note: The MX designation has been eliminated from the AJCC/UICC TNM system. Definitions have been modified to exclude clinical information.

The presence of distant metastases in a case of DCIS would be very unusual. Additional sampling to identify invasive carcinoma in the breast or additional history to document a prior or synchronous invasive carcinoma is advised in the evaluation of such cases.

+ Additional Pathologic Findings (Note L)

+ Specify: _____

+ Ancillary Studies

Note: For estrogen receptor (ER) and progesterone receptor (PgR) reporting, the CAP Breast Biomarker Template should be used. Pending biomarker studies should be listed in the Comments section of this report.

+ Microcalcifications (select all that apply) (Note M)

+ Not identified

+ Present in DCIS

+ Present in nonneoplastic tissue

+ Present in both DCIS and nonneoplastic tissue

+ Clinical History (select all that apply) (Note N)

+ The current clinical/radiologic breast findings for which this surgery is performed include:

+ Palpable mass

+ Radiologic finding

+ Mass or architectural distortion

+ Calcifications

+ Other (specify): _____

+ Nipple discharge

+ Other (specify): _____

+ Prior history of breast cancer

+ Specify site, diagnosis, and prior treatment: _____

+ Prior neoadjuvant treatment for this diagnosis of DCIS

+ Specify type: _____

+ Comment(s)

Explanatory Notes

A. Breast Specimens and Breast Procedures

Breast Specimens

The following types of breast specimens and procedures may be reported with the case summary:

Excisions. Removal of breast tissue without the intent of removing the entire breast. The nipple is only rarely removed with excisions. Excisions include specimens designated biopsies, partial mastectomies, lumpectomies, and quadrantectomies.

- Wire-guided localization excisions: If a nonpalpable lesion is detected by mammography, ultrasound, or magnetic resonance imaging (MRI), a wire is placed to identify the location of the lesion for the surgeon. Mammography or ultrasound should be used to document the presence of the targeted lesion in the excised tissue. The specimen radiograph (if performed) and the results of the radiologic evaluation should be available to the pathologist. Because MRI utilizes vascular uptake, it is not possible to image the specimen by using this technique to document the presence and location of the lesion.
- Excisions without wire localization: These excisions are generally performed for palpable masses or to excise major ducts behind the nipple to evaluate nipple discharge.

Total Mastectomy. Removal of all breast tissue, including the nipple and areola.

- Simple mastectomy: This procedure consists of a total mastectomy without removal of axillary lymph nodes.
- Skin-sparing mastectomy: This is a total mastectomy with removal of the nipple and only a narrow surrounding rim of skin.
- Modified radical mastectomy: This procedure consists of a total mastectomy and an axillary dissection. In the case summary, the breast and lymph node specimens are documented separately.
- Radical mastectomy: This procedure consists of a total mastectomy, axillary contents, and removal of the pectoralis muscles and currently is performed only rarely. This type of specimen and procedure can be indicated on the case summary as "Other."

The following types of specimens should not be reported using this protocol:

- Very small incisional biopsies (including core needle biopsies).
- Excisions containing only DCIS after a core needle biopsy or other specimen showing invasive carcinoma or DCIS with microinvasion (invasion measuring ≤ 1 mm). This type of case should be reported by using the protocol for invasive carcinoma of the breast,¹ and the report should incorporate information from the prior needle biopsy.

Specimen Sampling

Specimen sampling for specimens with DCIS has the following goals²⁻⁶:

- The clinical or radiologic lesion for which the surgery was performed must be examined microscopically. If the lesion is a nonpalpable imaging finding, the specimen radiograph and/or additional radiologic studies may be necessary to identify the lesion. When practical, the entire specimen should be submitted in a sequential fashion for histologic examination. If this is not possible, at least the entire region of the targeted lesion should be examined microscopically. If DCIS, lobular carcinoma in situ (LCIS), or atypical hyperplasia is identified, all fibrous tissue should be examined.²
- All other gross lesions noted in the specimen must be sampled.

- The margins must be evaluated for involvement by DCIS. If the specimen is received sectioned or fragmented, this should be noted, as this will limit the ability to evaluate the size of the lesion and the status of margins. If the specimen is an incisional biopsy, margins need not be evaluated.

For specimens with a known diagnosis of DCIS (eg, by prior core needle biopsy) it is highly recommended that the entire specimen is examined using serial sequential sampling to exclude the possibility of invasion, to completely evaluate the margins, and to aid in determining extent.⁷⁻⁹ If an entire excisional specimen or grossly evident lesion is not examined microscopically, it is helpful to note the approximate percentage of the specimen or lesion that has been examined.

Carcinomas present in excisions removed for lesions seen best by MRI studies are generally not grossly evident and not seen on specimen radiography.

Recording the specimen size is important, as the volume of tissue excised has been associated with the likelihood of recurrence.¹⁰

Tissue may be taken for research studies or assays that do not involve the histologic examination of the tissue (eg, reverse transcriptase polymerase chain reaction [RT-PCR]) only when taken in such a way to be able to evaluate the tissue for small areas of invasion. For example, a thin slice of tissue taken for research studies should be matched with an adjacent slice of tissue that will be examined microscopically.

B. Lymph Node Sampling

Patients with DCIS may have lymph nodes sampled in the following situations:

- Extensive DCIS: Patients with extensive DCIS are more likely to have areas of invasion and it may be difficult or impractical to examine all involved areas of the breast microscopically.¹¹⁻¹³ A lymph node with a macrometastasis would indicate an occult area of invasion.
- Pathologic findings on a prior needle biopsy or excision raising concern for invasion or microinvasion (invasion measuring ≤ 1 mm in size): If invasion has been documented, the protocol for invasive carcinoma of the breast¹ should be used.
- Imaging findings (eg, an irregular mass) or clinical findings (eg, a large palpable mass) that increase the likelihood that stromal invasion is present.¹²
- Planned mastectomy: The additional sampling of low lymph nodes or a sentinel lymph node does not result in increased morbidity. If the node or nodes are negative, and invasive cancer is found, another surgical procedure for node sampling can be avoided.

Most tumor cells in lymph nodes of patients with DCIS would be classified as isolated tumor cells.^{14,15} Artifactual displacement of epithelium within a lymph node can occur following a core needle biopsy; this finding should not be considered isolated tumor cells or a micrometastasis.^{16,17} If a larger nodal metastasis is found and the breast tissue has not been entirely submitted for microscopic examination, additional sampling should be considered to attempt to identify invasive carcinoma.^{11,13}

Grossly uninvolved nodes should be submitted in their entirety for histologic examination, whereas a representative section of a grossly positive node may be submitted. Small nodes (eg, 2 to 3 mm) may be submitted intact, but larger nodes should be thinly sectioned. An accurate assessment of the number of positive lymph nodes is a critical prognostic indicator.

Sentinel lymph nodes are identified as such by the surgeon, generally by uptake of radiotracer or dye.

C. Size (Extent) of DCIS

Although not required for pT classification or stage assignment, the size (extent) of DCIS is an important factor in patient management.^{5,18} Extent (as determined by a number of different methods) is correlated with the likelihood of residual disease after re-excision,¹⁹⁻²² close or positive margins,^{19,22} local recurrence,²³⁻²⁵ and the possibility of missed areas of invasion.^{12,13} Extent is not as important for predicting local recurrence when wide margins are obtained.^{23,24,26}

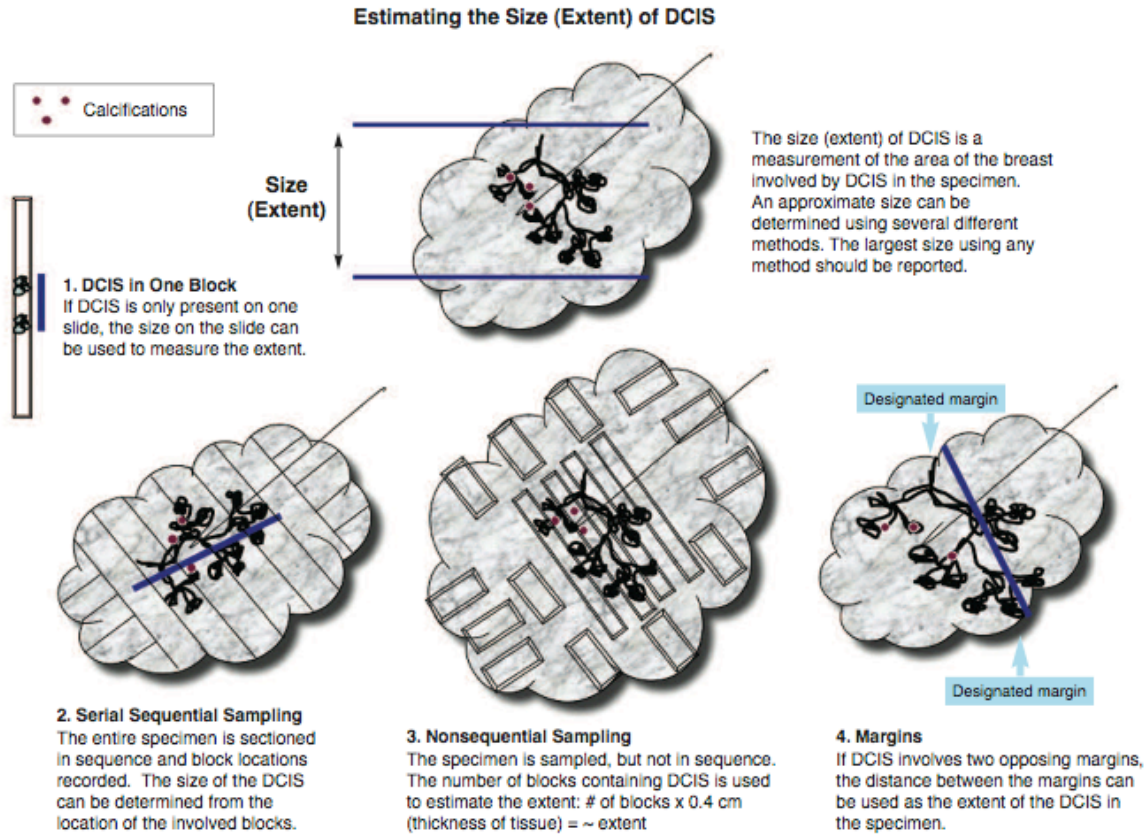
Extent is an estimation of the volume of breast tissue involved by DCIS. Mammographic assessment of DCIS, usually based on distribution of calcifications, frequently underestimates, and sometimes overestimates, the extent of DCIS. Precise measurement of extent is generally difficult or impossible for the following reasons²⁷:

- DCIS involves the ductal system in a complex 3-dimensional branching pattern that is usually only apparent by microscopic examination. When gross findings are present (eg, areas of tissue thickening and/or punctate necrosis), they often do not correspond to the entire area of involvement.
- The ductal system and surrounding tissue is highly compressible. Specimens may be distorted during surgery or specimen processing or compressed during specimen radiography.^{28,29}
- Diagnostic gaps in ductal involvement may be present (particularly for low-grade DCIS).
- DCIS is often not removed in 1 excision and may be present in multiple specimens from 1 surgical procedure or in multiple specimens from multiple procedures. This is more likely in cases of large areas of involvement.

The mean or median extent of DCIS is 14 to 27 mm^{8,9,19,22} but ranges from 1 mm to extensive involvement of all 4 quadrants of the breast. Although a precise measurement is often not possible, an estimate of the extent of DCIS is clinically important (Table 1).

Table 1. Extent of Ductal Carcinoma In Situ (DCIS) and Clinical Significance

Size	Extent
Up to 20 mm	Breast conservation with wide negative margins can be achieved in most women. Microscopic examination of the entire area involved by DCIS is recommended and should be possible in most cases. This will require complete microscopic examination of smaller biopsies, or sampling of large excisions or mastectomies to include all areas likely to contain DCIS (eg, tissue with radiologic calcifications or grossly abnormal tissue).
>20-40 mm	Wide negative margins may be difficult to achieve in some women with breast-conserving surgery. Microscopic examination of the entire area involved by DCIS is recommended but may be difficult to achieve in some cases. This will require complete microscopic examination of smaller biopsies or sampling of large excisions or mastectomies to include all areas likely to contain DCIS (eg, tissue with radiologic calcifications or grossly abnormal tissue).
>40 mm	Breast conservation with wide negative margins may be impossible to achieve in some women. Microscopic examination of the entire area involved by DCIS is recommended but may be impractical in some cases. This will require complete microscopic examination of smaller biopsies or selective sampling of large excisions or mastectomies to include areas likely to contain DCIS (eg, tissue with radiologic calcifications or grossly abnormal tissue). There is a possibility of undetected areas of invasion if the area involved by DCIS is not completely examined. Lymph node sampling may be recommended.



There are multiple methods for estimating the extent of DCIS (see Figure):

- **DCIS in 1 block:** The area involved by DCIS can be measured from a single slide, if DCIS is present in only 1 block. If separate foci are present, the largest distance between foci should be reported. This method will underestimate the extent of DCIS when multiple blocks are involved and should not be used in such cases.⁸
- **Serial sequential sampling:** The entire specimen is blocked out in such a way that the location of each block can be determined. The extent of the DCIS can be calculated by using a diagram of the specimen, the thickness of the slices, and the location of the involved blocks.⁷⁻⁹ This method is recommended for all excisions likely to harbor DCIS or with previously diagnosed DCIS (eg, by diagnosis on a prior core needle biopsy).
- **Nonsequential sampling:** The number of blocks involved by DCIS is correlated with the extent of DCIS up to 40 mm.⁸ Multiplying the number of blocks involved by DCIS by the approximate width of a tissue section gives an estimate of the extent. In 2 studies, multiplying by 3 mm underestimated the extent of DCIS, and multiplying by 5 mm may overestimate the extent.^{8,9} Therefore, multiplying by 4 mm is recommended unless there is additional information that a different number would yield a more accurate result. This method may underestimate

extent if not all areas of DCIS are sampled. Therefore, it is recommended that all tissue likely to be involved by DCIS be sampled (eg, all grossly abnormal tissue and all tissue with radiologically suspicious calcifications). When feasible, the entire specimen should be examined microscopically.

This method may result in a larger estimation of extent than the serial sequential sampling method when DCIS is present in a large volume of tissue in 3 dimensions rather than in a predominantly linear distribution. The best estimate for correlation with outcomes (eg, residual disease or recurrence) will require further studies.

This method can be applied to any specimen and will give a better estimation of extent than measuring extent on a single slide when multiple blocks contain DCIS.

- **Margins:** If DCIS involves or is close to 2 opposing margins, the distance between the margins can be used as the extent of the DCIS within the specimen.
- **Gross lesions:** In some cases of high-grade DCIS, there may be a gross lesion that can be measured. Confirmation of the gross size must be confirmed by microscopic evaluation.

The largest estimate obtained using any of these methods should be used to report the estimated size (extent) of the DCIS.

D. Histologic Type

This protocol applies only to cases of DCIS. The protocol for invasive carcinoma of the breast¹ applies if invasion or microinvasion (less than or equal to 1 mm) is present. This protocol should not be used for classic/typical LCIS (eg, extent and margins are not generally reported) but can be used for rare difficult to classify cases of carcinoma in situ with features of both DCIS and LCIS (eg, architectural patterns of both DCIS and LCIS or cytologic features of LCIS (without expression of e-cadherin), but with high-grade nuclei and/or necrosis). In some cases, clinicians may choose to treat such cases as DCIS.

When DCIS involves nipple skin only, without underlying invasive carcinoma or DCIS, the classification is DCIS (ie, Tis [Paget]). The majority of these cases are strongly positive for HER2.

E. Architectural Pattern

The architectural pattern has been reported traditionally for DCIS.³⁻⁵ However, nuclear grade and the presence of necrosis are more predictive of clinical outcome.

F. Nuclear Grade

The nuclear grade of DCIS is determined using 6 morphologic features (Table 2).^{4,30}

Table 2. Nuclear Grade of Ductal Carcinoma In Situ

Feature	Grade I (Low)	Grade II (Intermediate)	Grade III (High)
Pleomorphism	Monotonous (monomorphic)	Intermediate	Markedly pleomorphic
Size	1.5X to 2X the size of a normal RBC or a normal duct epithelial cell nucleus	Intermediate	>2X the size of a normal RBC or a normal duct epithelial cell nucleus
Chromatin	Usually diffuse, finely dispersed chromatin	Intermediate	Usually vesicular with irregular chromatin distribution
Nucleoli	Only occasional		Prominent, often multiple
Mitoses	Only occasional	Intermediate	May be frequent
Orientation	Polarized toward luminal spaces	Intermediate	Usually not polarized toward the luminal space

Definition: RBC, red blood cell.

G. Necrosis⁴

The presence of necrosis is correlated with the finding of mammographic calcifications (ie, most areas of necrosis will calcify). DCIS that presents as mammographic calcifications often recurs as calcifications. Necrosis can be classified as follows:

- **Central ("comedo"):** The central portion of an involved ductal space is replaced by an area of expansive necrosis that is easily detected at low magnification. Ghost cells and karyorrhectic debris are generally present. Although central necrosis is generally associated with high-grade nuclei (ie, comedo DCIS), it can also occur with DCIS of low or intermediate nuclear grade. This type of necrosis often correlates with a linear and/or branching pattern of calcifications on mammography.
- **Focal (punctate):** Small foci, indistinct at low magnification, or single cell necrosis.

Necrosis should be distinguished from secretory material, which can also be associated with calcifications, cytoplasmic blebs, and histiocytes, but does not include nuclear debris.

H. Margins

Whenever feasible, the specimen should be oriented in order to identify specific margins.

Margins may be identified by sutures or clips placed on the specimen surface or by other means of communication between surgeon and pathologist and should be documented in the pathology report. Margins can be identified microscopically in several ways, including the use of multiple colored inks, by submitting the margins in specific cassettes, or by the surgeon submitting each margin as a separately excised specimen. Inks should be applied to the surface of the specimen, taking care to avoid penetration into the specimen.

If margins are sampled with perpendicular sections, the pathologist should report the distance from the DCIS to the closest margin, when possible. Due to the growth pattern of DCIS in the ductal system, a negative but close margin does not ensure the absence of DCIS in the adjacent tissue.

A positive margin requires ink on DCIS. If the specimen is oriented, the specific site(s) of involvement (eg, superior margin) should also be reported.

The deep margin may be at muscle fascia. If so, the likelihood of additional breast tissue beyond this margin (and therefore possible involvement by DCIS) is extremely small. A deep muscle fascial margin (eg, on a mastectomy specimen) is unlikely to have clinical significance.

A superficial (generally anterior) margin may be immediately below the skin, and there may not be additional breast tissue beyond this margin. However, some breast tissue can be left in skin flaps, and the likelihood of residual breast tissue is related to the thickness of the flap.³¹

Specimen radiography is important to assess the adequacy of excision. Compression of the specimen should be minimized, as it can severely compromise the ability to assess the distance of the DCIS from the surgical margin.²⁷ Mechanical compression devices should be used with caution and preferably reserved for nonpalpable lesions that require this technique for imaging (eg, microcalcifications).

If DCIS is present at the margin, the extent of margin involvement is associated with the likelihood of residual disease^{19,20}:

- Focal (eg, DCIS at the margin in a <1 mm area in 1 block)
- Minimal/moderate (between focal and extensive)
- Extensive (eg, DCIS at the margin in an area ≥ 15 mm or in 5 or more low-power fields and/or in 8 or more blocks)

I. Neoadjuvant Therapy

Patients may be treated with endocrine therapy, chemotherapy, or HER2-targeted therapy prior to surgical excision, either as part of a protocol or during treatment of a contralateral carcinoma. It has been observed after treatment of women with invasive carcinoma that the invasive carcinoma may respond to a greater extent than the accompanying DCIS. The histologic changes occurring in DCIS after treatment have not been well described and will likely vary with the specific agents used. Comparison to a pretreatment specimen is necessary to attribute histologic changes to the effects of treatment. The significance of histologic changes in DCIS is unknown.

If the patient had invasive carcinoma prior to treatment, but only DCIS after treatment, additional classification systems are available to evaluate residual carcinoma in the breast and lymph nodes.³²

J. Lymph Nodes

Reporting Lymph Nodes

The pathology report should state the total number of lymph nodes examined (including the number of sentinel nodes), the number of nodes with metastases, and the greatest dimension of the largest metastatic focus. If a patient has at least 1 macrometastasis, only nodes with micro and macrometastases are included for the total number of involved nodes for N classification.³³ Nodes with isolated tumor cells are not included in this count.

One section from grossly involved nodes may be examined. All other lymph nodes should be thinly sectioned and entirely submitted for microscopic evaluation. A single H&E section from each lymph node block is considered sufficient for routine evaluation. If additional studies are performed, these should be documented (ie, additional H&E levels or immunohistochemical studies). The presence of extranodal tumor extension should be included in the pathology report because it may be associated with a higher frequency of axillary recurrence.

If lymph node sampling has not been performed, a response to this section is not required, although the "Not applicable" answer selection may be selected. If information about a prior lymph node sampling is unavailable, "X" is used rather than a number in the N designation. A pN classification requires removal of lymph nodes with pathologic examination.

The classification is based on axillary lymph node dissection with or without sentinel lymph node dissection. Classification based solely on sentinel lymph node dissection without subsequent axillary

dissection is designated (sn) for “sentinel node,” eg, pN0(i+)(sn). If 6 or more lymph nodes are examined (including sentinel and nonsentinel lymph nodes), the modifier (sn) is not used.

Isolated tumor cells (ITCs) are defined as single tumor cells or small cell clusters not greater than 0.2 mm and numbering less than 200 cells.^{1,34-36} They may be detected by routine histologic examination or by immunohistochemical (IHC) or molecular methods. ITCs do not usually show evidence of malignant activity (eg, proliferation or stromal reaction), but micrometastases may show these changes.

Almost all tumor cells present in lymph nodes of patients with DCIS are isolated tumor cells or the cells may be artifactually displaced from a previous procedure.^{16,17} Isolated tumor cells detected in cases of DCIS have not been shown to have prognostic importance.^{14,15} If a larger metastasis is found, additional tissue sampling and review of slides are helpful to determine if an area of invasion is present.¹³

K. Pathologic Staging

The tumor-node-metastasis (TNM) staging system maintained collaboratively by the American Joint Committee on Cancer (AJCC) and the International Union Against Cancer (UICC) is recommended.³³⁻³⁷

Pathologic Classification

The pathologic classification of a cancer is based on information acquired before treatment supplemented and modified by the additional evidence acquired during and from surgery, particularly from pathologic examination of resected tissues. The pathologic classification provides additional precise and objective data. Classification of T, N, and M by pathologic means is denoted by use of a lower case “p” prefix (pT, pN, pM).

Pathologic T. Tumor size should be recorded in whole millimeters. If the size is reported in smaller units such as a tenth or hundredth of a millimeter, it should be rounded to the nearest whole millimeter for reporting stage. Rounding is performed as follows: one through four are rounded down, and five through nine are rounded up. For example, a breast tumor reported as 4.2 mm in size should be recorded for staging as a 4-mm tumor, and a 4.7-mm tumor should be recorded as a 5-mm tumor. If the tumor is not resected, but a biopsy of the primary tumor is performed that is adequate to evaluate the highest pT category, the pT classification is assigned. Some disease sites have specific rules to guide assignment of pT category in such cases. On rare occasions, the tumor size is obtained from a previous core needle biopsy specimen, as the tumor in the core may be larger than the tumor in the excision specimen.

Pathologic N. At least one node with presence or absence of cancer documented by pathologic examination is required for pathologic staging N. A tumor nodule with a smooth contour in a regional node area is classified as a positive node. The size of the metastasis, not the size of the node, is used for the criterion for the N category.

Specialized pathologic techniques such as immunohistochemistry or molecular techniques may identify limited metastases in lymph nodes that may not have been identified without the use of the special diagnostic techniques. Single tumor cells or small clusters of cells are classified as *isolated tumor cells* (ITCs). The standard definition for ITC is a cluster of cells not more than 0.2 mm in greatest diameter. Cases with ITC only in lymph nodes are classified as pN0. This rule also generally applies to cases with findings of tumor cells or their components by nonmorphologic techniques such as flow cytometry or DNA analysis.

Pathologic M. The pathologic assignment of the presence of *metastases* (pM1) requires a biopsy positive for cancer at the metastatic site. Pathologic M0 is an undefined concept and the category pM0 may not be used. Pathologic classification of the absence of distant metastases can only be

made at autopsy. It would be extremely rare to have distant metastasis in examples of DCIS, and would surely indicate an unsampled area of invasive carcinoma.

Posttherapy or Postneoadjuvant Therapy Classification (yTNM). Cases where systemic and/or radiation therapy are given before surgery (*neoadjuvant*) or where no surgery is performed may have the extent of disease assessed at the conclusion of the therapy by clinical or pathologic means (if resection performed). This classification is useful to clinicians because the extent of response to therapy may provide important prognostic information to patients and help direct the extent of surgery or subsequent systemic and/or radiation therapy. T and N are classified by using the same categories as for clinical or pathologic staging for the disease type, and the findings are recorded by using the prefix designator y (eg, ycT; ycN; ypT; ypN). The yc prefix is used for the clinical stage after therapy, and the yp prefix is used for the pathologic stage for those cases that have surgical resection after neoadjuvant therapy. The M component should be classified by the M status defined clinically or pathologically prior to therapy.

Retreatment Classification. The retreatment classification (rTNM) is assigned when further treatment is planned for a cancer that recurs after a disease-free interval. The original stage assigned at the time of initial diagnosis and treatment does not change when the cancer recurs or progresses. The use of this staging for retreatment or recurrence is denoted with the r prefix (rTNM). All information available at the time of retreatment should be used in determining the rTNM stage. Biopsy confirmation of recurrent cancer is important if clinically feasible. However, this may not be appropriate for each component, so clinical evidence for the T, N, or M component by clinical, endoscopic, radiologic, or related methods may be used.

Multiple tumors. If there are multiple simultaneous areas of DCIS in the breast, Tis remains the appropriate choice. For simultaneous bilateral examples of DCIS, each DCIS is classified separately as independent tumors in different organs.

Metachronous primaries. Second or subsequent primary examples of DCIS occurring in the same organ or in different organs are staged as a new DCIS with the TNM system. Second DCIS examples are not staged using the y prefix unless the treatment of the second cancer warrants this use.

Residual tumor and surgical margins. The absence or presence of residual tumor after treatment is described by the symbol R. pTNM describe the extent of cancer in general without consideration of treatment. pTNM can be supplemented by the R classification, which deals with the tumor status after treatment. In some cases treated with surgery and/or with neoadjuvant therapy there will be residual tumor at the primary site after treatment because of incomplete resection or local and regional disease that extends beyond the limit or ability of resection. The presence of residual tumor may indicate the effect of therapy, influence further therapy, and be a strong predictor of prognosis. In addition, the presence or absence of disease at the margin of resection may be a predictor of the risk of recurrent cancer. The R category is not incorporated into TNM staging itself. However, the absence or presence of residual tumor and status of the margins may be recorded in the medical record and cancer registry.

The absence or presence of residual tumor at the primary tumor site after treatment is denoted by the symbol R. The R categories for the primary tumor site are as follows:

R0	No residual tumor
R1	Microscopic residual tumor
R2	Macroscopic residual tumor
RX	Presence of residual tumor cannot be assessed

The margin status may be recorded using the following categories:

Negative margins (tumor not present at the surgical margin)

Microscopic positive margin (tumor not identified grossly at the margin, but present microscopically at the margin)

Macroscopic positive margin (tumor identified grossly at the margin)

Margin not assessed

L. Additional Pathologic Findings

In some cases, other pathologic findings are important for the clinical management of patients.

If the biopsy was performed for a benign lesion and the DCIS is an incidental finding, this should be documented. An example would be the finding of DCIS in an excision for a palpable fibroadenoma.

Peritumoral vascular invasion is a very rare finding in association with DCIS alone. Additional sampling should be considered to attempt to identify an area of invasion. If there has been prior surgery or needle biopsy, the possibility of artifactual displacement of epithelial cells into lymphatics should be considered. Lymph node biopsy may be performed in patients with DCIS and lymphovascular invasion.

If there has been a prior core needle biopsy or incisional biopsy, the biopsy site should be sampled and documented in the report. If the intention was to completely re-excite a prior surgical site, the report should document biopsy changes at the margin that could indicate an incomplete excision. This protocol should only be used for re-excisions that reveal the largest extent of DCIS.

M. Microcalcifications

DCIS found in biopsies performed for microcalcifications will almost always be at the site of the calcifications or in close proximity.^{2,3,5} The presence of the targeted calcifications in the specimen should be confirmed by specimen radiography. The pathologist must be satisfied that the specimen has been sampled in such a way that the lesion responsible for the calcifications has been examined microscopically. The relationship of the radiologic calcifications to the DCIS should be indicated.

N. Clinical Information

It is a Joint Commission requirement that clinical information be provided for pathology specimens. Relevant clinical information is often necessary for the accurate evaluation of breast specimens and includes:

Patient Information

Family history of breast or ovarian cancer and/or *BRCA1* or *BRCA2* mutation

Current pregnancy or lactation

Prior breast biopsy or surgery (including implants)

Prior breast cancer diagnosis (type, location in breast, date of diagnosis)

Prior treatment that could affect the breast:

- Radiation

- Chemotherapy

- Hormonal therapy (eg, tamoxifen, aromatase inhibitors, or oral contraceptives)

- Systemic diseases that may affect the breast (eg, collagen vascular disease, sarcoidosis, Wegener granulomatosis)

Specimen Information

Type of lesion sampled:

- Palpable mass

- Nipple discharge

- Nipple lesion (eg, scaling crust)

Imaging finding

- Mammographic or ultrasound mass: shape of mass (irregular, circumscribed, ill defined, cystic or solid)
- Mammographic calcifications
- Mammographic architectural distortion
- Prior core needle biopsy site, with or without a clip, with or without residual radiologic or clinical lesion
- MRI-detected lesion

Type of specimen:

- Excision without wire localization
- Excision with wire localization – for these specimens, the specimen radiograph with an interpretation should be available to the pathologist
- Nipple duct excision
- Total mastectomy
- Lymph node specimen (sentinel node, nonsentinel node, limited axillary dissection, complete axillary dissection)

References

1. Lester SC, Bose S, Chen Y, et al. Protocol for the examination of specimens from patients with invasive carcinoma of the breast. *Arch Pathol Lab Med.* 2009;133(10):1515-1538.
2. Owings DV, Hann L, Schnitt SJ, How thoroughly should needle localization breast biopsies be sampled for microscopic examination? A prospective mammographic/pathologic correlative study. *Am J Surg Pathol.* 1990;14:578-583.
3. Association of Directors of Anatomic and Surgical Pathology. *Recommendations for the Reporting of Breast Carcinoma.* Updated September 2004, Version 1.1. www.adasp.org/Checklists/Checklists.htm. Accessed June 18, 2008.
4. Schwartz GF, Lagios MD, Carter D, et al. Consensus conference on the classification of ductal carcinoma in situ. *Cancer.* 1997;80:1798-1802.
5. Silverstein MJ, Lagios MD, Recht A, et al. Image-detected breast cancer: state of the art diagnosis and treatment. *J Am Coll Surg.* 2005;201:586-597.
6. Lester SC. *Manual of Surgical Pathology.* 2nd ed. New York: Elsevier; 2006.
7. Silverstein MJ, Poller D, Craig P, et al. A prognostic index for ductal carcinoma in situ of the breast. *Cancer.* 1996;77:2267-2274.
8. Grin A, Horne G, Ennis M, O'Malley FP. Measuring extent of DCIS in breast excision specimens: a comparison of four methods. *Arch Pathol Lab Med.* 2009;133:31-37.
9. Dadmanesh F, Fan X, Dastane A, Amin MB, Bose S. Comparative analysis of size estimation by mapping and counting number of blocks with DCIS in breast excision specimens. *Arch Pathol Lab Med.* 2009;133:26-30.
10. Vicini FA, Kestin LL, Goldstein NS, Baglan KL, Pettinga JE, Martinez AA. Relationship between excision volume, margin status, and tumor size with the development of local recurrence in patients with ductal carcinoma-in-situ treated with breast-conserving therapy. *J Surg Oncol.* 2001;76:245-254.
11. Lagios MD, Westdahl PR, Margolin FR, et al. Duct carcinoma in situ: relationship of extent of noninvasive disease to the frequency of occult invasion, multicentricity, lymph node metastasis, and short-term treatment failures. *Cancer.* 1982;50:1309-1314.
12. Maffuz A, Barroso-Bravo S, Najera I, Zarco G, Alvarado-Cabrero I, Roriguez-Cuevas SI. Tumor size as predictor of microinvasion, invasion, and axillary metastasis in ductal carcinoma in situ. *J Exp Clin Cancer Res.* 2006;25:223-227.
13. Moore KH, Sweeney KJ, Wilson ME, et al. Outcomes for women with ductal carcinoma-in-situ and a positive sentinel lymph node: a multi-institutional audit. *Ann Surg Oncol.* 2007;14:2911-2917.
14. Broekhuizen LN, Wijsman JH, Peterse JL, Rutgers EJT. The incidence and significance of micrometastases in lymph nodes of patients with ductal carcinoma in situ and T1a carcinoma of the breast. *Eur J Surg Oncol.* 2006; 32:502-506.
15. Lara JF, Young SM, Velilla RE, Santoro EJ, Templeton SF. The relevance of occult axillary micrometastasis in DCIS: a clinicopathologic study with long-term follow-up. *Cancer.* 2003;98:2105-2113.

16. Carter BA, Jensen RA, Simpson JF, Page DL. Benign transport of breast epithelium into axillary lymph nodes after biopsy. *Am J Clin Pathol*. 2000;113:259-265.
17. Bleiweiss IJ, Nagi CS, Jaffer S. Axillary sentinel lymph nodes can be falsely positive due to iatrogenic displacement and transport of benign epithelial cells in patients with breast carcinoma. *J Clin Oncol*. 2006;24:2013-2018.
18. O'Sullivan MJ, Morrow M. Ductal carcinoma in situ: current management. *Surg Clin North Am*. 2007;87:333-351, viii.
19. Dillon MF, McDermott EW, O'Doherty A, et al. Factors effecting successful breast conservation for ductal carcinoma in situ. *Ann Surg Oncol*. 2007;14:1618-1628.
20. Sigal-Zafrani B, Lewis JS, Clough KB, et al; on behalf of the Institut Curie Breast Study Group. Histologic margin assessment for breast ductal carcinoma in situ: precision and implications. *Mod Pathol*. 2004;17:81-88.
21. Neuschatz AC, DiPetrillo T, Steinhoff M, et al. The value of breast lumpectomy margin assessment as a predictor of residual tumor burden in ductal carcinoma in situ of the breast. *Cancer*. 2002;94:1917-1924.
22. Cheng L, Al-Kaisi NK, Gordon NH, Liu AY, Gebrael F, Shenk RR. Relationship between the size and margin status of ductal carcinoma in situ of the breast and residual disease. *J Natl Cancer Inst*. 1997;89:1356-1360.
23. Di Saverio S, Catena F, Santini D, et al. 259 patients with DCIS of the breast applying USC/Van Nuys prognostic index: a retrospective review with long term follow up. *Breast Cancer Res Treat*. 2008;109:404-416.
24. MacDonald HR, Silverstein MJ, Mabry H, et al. Local control in ductal carcinoma in situ treated by excision alone: incremental benefit of larger margins. *Am J Surg*. 2005;190:521-525.
25. Asjoe FT, Altintas S, Huizing MT, et al. The value of the Van Nuys Prognostic Index in ductal carcinoma in situ of the breast: a retrospective analysis. *Breast J*. 2007;13:359-367.
26. MacDonald HR, Silverstein MJ, Lee LA, et al. Margin width as the sole determinant of local recurrence after breast conservation in patients with ductal carcinoma in situ of the breast. *Am J Surg*. 2006;192:420-422.
27. Saqi A, Osborne MP, Rosenblatt R, Shin SJ, Hoda SA. Quantifying mammary duct carcinoma in situ: a wild-goose chase? *Am J Clin Pathol*. 2000;113(suppl 1):S30-S37.
28. Clingan R, Griffen M, Phillips J, et al. Potential margin distortion in breast tissue by specimen mammography. *Arch Surg*. 2003;138:1371-1374.
29. Graham RA, Homer MJ, Katz J, et al. The pancake phenomenon contributes to the inaccuracy of margin assessment in patients with breast cancer. *Am J Surg*. 2002;184:89-93.
30. Radiation Therapy Oncology Group (RTOG). *Evaluation of Breast Specimens Removed by Needle Localization Technique*. Available at: <http://www.rtog.org/qa/98-04/9804images/9804path1.html>. Accessed June 18, 2008.
31. Torresan RZ, dos Santos CC, Okamura H, Alvarenga M. Evaluation of glandular tissue after skin-sparing mastectomies. *Ann Surg Oncol*. 2005;12:1037-1044.
32. Gralow JR, Burstein HJ, Wood W, et al. Preoperative therapy in invasive breast cancer: pathologic assessment and systemic therapy issues in operable disease. *J Clin Oncol*. 2008;26:814-819.
33. Edge SB, Byrd DR, Carducci MA, Compton CC, eds. *AJCC Cancer Staging Manual*. 7th ed. New York, NY: Springer; 2009.
34. Connolly JL. Changes and problematic areas in interpretation of the AJCC Cancer Staging Manual, 6th Edition, for breast cancer. *Arch Pathol Lab Med*. 2006;130:287-291.
35. Singletary SE, Connolly JL. Breast cancer staging: working with the sixth edition of the AJCC Cancer Staging Manual. *CA Cancer J Clin*. 2006;56:37-47.
36. Singletary SE, Greene FL, Sobin LH. Classification of isolated tumor cells: clarification of the 6th edition of the American Joint Committee on Cancer Staging Manual. *Cancer*. 2003;90:2740-2741.
37. Sobin LH, Wittekind C, eds. *UICC TNM Classification of Malignant Tumours*. 6th ed. New York, NY: Wiley-Liss; 2002:131-141.