

Protocol for the Examination of Specimens From Patients With Primary Tumors of Bone

Version: Bone 4.0.0.0

Protocol Posting Date: June 2017

Includes pTNM requirements from the 8th Edition, AJCC Staging Manual

For accreditation purposes, this protocol should be used for the following procedures and tumor types:

Procedure	Description
Resection	Includes specimens designated intralesional resection, marginal resection, segmental/wide resection, or radical resection
Tumor Type	Description
Primary malignant bone tumors	Includes chondrogenic tumors, osteogenic tumors, fibrogenic tumors, osteoclastic giant cell rich tumors, notochordal tumors, vascular tumors, myogenic tumors, and lipogenic tumors

This protocol is NOT required for accreditation purposes for the following:

Procedure
Biopsy (includes core needle biopsy, curettage, or excisional biopsy)
Primary resection specimen with no residual cancer (eg, following neoadjuvant therapy)
Cytologic specimens

The following tumor types should NOT be reported using this protocol:

Tumor Type
Plasma cell neoplasms (consider the Plasma Cell Neoplasms protocol)
Lymphoma (consider the Hodgkin or non-Hodgkin Lymphoma protocols)
Pediatric Ewing sarcoma (consider the Ewing Sarcoma protocol)
Soft tissue sarcoma (consider the Soft Tissue protocol)

Authors

Javier A. Laurini, MD*; Cristina R. Antonescu, MD; Kumarasen Cooper, MBChB, DPhil; Francis H. Gannon, MD; Jennifer Leigh Hunt, MD; Carrie Y. Inwards, MD; Michael Jeffrey Klein, MD; Jeffrey S. Kneisl, MD; Thomas Krausz, MD; Alexander Lazar, MD, PhD; Anthony G. Montag, MD; Jordan Olson, MD; Terrance D. Peabody, MD; John D. Reith, MD; Andrew E. Rosenberg, MD; Brian P. Rubin, MD, PhD

With guidance from the CAP Cancer and CAP Pathology Electronic Reporting Committees.

* Denotes primary author. All other contributing authors are listed alphabetically.

Accreditation Requirements

This protocol can be utilized for a variety of procedures and tumor types for clinical care purposes. For accreditation purposes, only the definitive primary cancer resection specimen is required to have the core and conditional data elements reported in a synoptic format.

- Core data elements are required in reports to adequately describe appropriate malignancies. For accreditation purposes, essential data elements must be reported in all instances, even if the response is “not applicable” or “cannot be determined.”
- Conditional data elements are only required to be reported if applicable as delineated in the protocol.
- Optional data elements, are identified with “+” and although not required for CAP accreditation purposes, may be considered for reporting as determined by local practice standards

The use of this protocol is not required for recurrent tumors or for metastatic tumors that are resected at a different time than the primary tumor. Use of this protocol is also not required for pathology reviews performed at a second institution (i.e. secondary consultation, second opinion, or review of outside case at second institution).

Synoptic Reporting

All core and conditionally required data elements outlined on the surgical case summary from this cancer protocol must be displayed in synoptic report format. Synoptic format is defined as:

- Data element: followed by its answer (response), outline format without the paired "Data element: Response" format is NOT considered synoptic.
- The data element must be represented in the report as it is listed in the case summary. The response for any data element may be modified from those listed in the case summary, including “Cannot be determined” if appropriate.
- Each diagnostic parameter pair (Data element: Response) is listed on a separate line or in a tabular format to achieve visual separation. The following exceptions are allowed to be listed on one line:
 - Anatomic site or specimen, laterality, and procedure
 - Pathologic Stage Classification (pTNM) elements
 - Negative margins, as long as all negative margins are specifically enumerated where applicable
- The synoptic portion of the report can appear in the diagnosis section of the pathology report, at the end of the report or in a separate section, but all Data element: Responses must be listed together in one location

Organizations and pathologists may choose to list the required elements in any order, use additional methods in order to enhance or achieve visual separation, or add optional items within the synoptic report. The report may have required elements in a summary format elsewhere in the report IN ADDITION TO but not as replacement for the synoptic report i.e. all required elements must be in the synoptic portion of the report in the format defined above.

CAP Laboratory Accreditation Program Protocol Required Use Date: March 2018*

* Beginning January 1, 2018, the 8th edition AJCC Staging Manual should be used for reporting pTNM

CAP Bone Protocol Summary of Changes

Biopsy

The following data elements were modified:

Histologic Grade
Lymphovascular Invasion

The following data elements were deleted:

Tumor Size

Resection

The following data elements were modified:

Histologic Grade
Lymphovascular Invasion
Pathologic Staging, Primary Tumor (pT)
Distant Metastases

Surgical Pathology Cancer Case Summary

Protocol posting date: June 2017

BONE: Biopsy

Note: This case summary is recommended for reporting biopsy specimens, but is not required for accreditation purposes.

Select a single response unless otherwise indicated.

Procedure

- Core needle biopsy
- Curettage
- Excisional biopsy
- Other (specify): _____
- Not specified

Tumor Site (Note A)

- Appendicular skeleton (specify bone, if known): _____
- Spine (specify bone, if known): _____
- Pelvis (specify bone, if known): _____
- Not specified

Tumor Location and Extent (select all that apply) (Note B)

- Epiphysis or apophysis
- Metaphysis
- Diaphysis
- Cortex
- Medullary cavity
- Surface
- Tumor involves joint
- Tumor extension into soft tissue
- Cannot be determined

Histologic Type (World Health Organization [WHO] classification of bone tumors) (Note C)

- Specify: _____
- Cannot be determined

+ Mitotic Rate (Note D)

- + Specify: ___/10 high-power fields (HPF)
(1 HPF x 400 = 0.1734 mm²; X40 objective; most proliferative area)

Necrosis (Note D)

- Not identified
- Present
 - Extent: ___%
- Cannot be determined

Histologic Grade (Note D)

- G1: Well differentiated, low grade
- G2: Moderately differentiated, high grade
- G3: Poorly differentiated, high grade
- GX: Cannot be assessed
- Not applicable

+ Data elements preceded by this symbol are not required for accreditation purposes. These optional elements may be clinically important but are not yet validated or regularly used in patient management.

+ Lymphovascular Invasion (Note E)

- + ___ Not identified
- + ___ Present
- + ___ Cannot be determined

+ Additional Pathologic Findings

+ Specify: _____

Ancillary Studies (required only if applicable)

Immunohistochemistry (specify): _____

___ Not performed

Cytogenetics (specify): _____

___ Not performed

Molecular Pathology (specify): _____

___ Not performed

+ Radiographic Findings (Note F)

+ Specify: _____

+ ___ Not available

+ Comment(s)

Surgical Pathology Cancer Case Summary

Protocol posting date: June 2017

BONE: Resection

Select a single response unless otherwise indicated.

Procedure (Note G)

- Intralesional resection
- Marginal resection
- Segmental/wide resection
- Radical resection
- Other (specify): _____
- Not specified

Tumor Site (Note A)

- Appendicular skeleton (specify bone, if known): _____
- Spine (specify bone, if known): _____
- Pelvis (specify bone, if known): _____
- Not specified

Tumor Location and Extent (select all that apply) (Note B)

- Epiphysis or apophysis
- Metaphysis
- Diaphysis
- Cortical
- Medullary cavity
- Surface
- Tumor involves joint
- Tumor extension into soft tissue
- Cannot be determined

Tumor Size

- Greatest dimension (centimeters): ____ cm
- + Additional dimensions (centimeters): ____ x ____ cm
- Cannot be determined
- Multifocal tumor/discontinuous tumor at primary site (skip metastasis)

Histologic Type (World Health Organization [WHO] classification of bone tumors) (Note C, Note H)

- Specify: _____
- Cannot be determined

+ Mitotic Rate (Note D)

- + Specify: ____ /10 high-power fields (HPF)
(1 HPF x 400 = 0.1734 mm²; X40 objective; most proliferative area)

Necrosis (macroscopic or microscopic) (Note D)

- Not Identified
- Present
Extent: ____%

Histologic Grade (Note D)

- G1: Well differentiated, low grade
- G2: Moderately differentiated, high grade

+ Data elements preceded by this symbol are not required for accreditation purposes. These optional elements may be clinically important but are not yet validated or regularly used in patient management.

- G3: Poorly differentiated, high grade
- GX: Cannot be assessed
- Not applicable

Margins (Note I)

- Cannot be assessed
- Uninvolved by sarcoma
 - Distance of sarcoma from closest margin (centimeters): ___ cm
 - Specify margin (if known): _____
- Involved by sarcoma
 - Specify margin(s) (if known): _____

+ Lymphovascular Invasion (Note E)

- + Not identified
- + Present
- + Cannot be determined

Regional Lymph Nodes (Note K)

- No lymph nodes submitted or found

Lymph Node Examination (required only if lymph nodes are present in the specimen)

- Number of Lymph Nodes Involved: _____
- Number cannot be determined (explain): _____

- Number of Lymph Nodes Examined: _____
- Number cannot be determined (explain): _____

Pathologic Stage Classification (pTNM, AJCC 8th Edition) (Note J)

Note: Reporting of pT, pN, and (when applicable) pM categories is based on information available to the pathologist at the time the report is issued. Only the applicable T, N, or M category is required for reporting; their definitions need not be included in the report. The categories (with modifiers when applicable) can be listed on 1 line or more than 1 line.

TNM Descriptors (required only if applicable) (select all that apply)

- m (multiple)
- r (recurrent)
- y (posttreatment)

Primary Tumor (pT)

Appendicular Skeleton, Trunk, Skull, and Facial Bones

- pTX: Primary tumor cannot be assessed
- pT0: No evidence of primary tumor
- pT1: Tumor \leq 8 cm in greatest dimension
- pT2: Tumor > 8 cm in greatest dimension
- pT3: Discontinuous tumors in the primary bone site

Spine

- pTX: Primary tumor cannot be assessed
- pT0: No evidence of primary tumor
- pT1: Tumor confined to one vertebral segment or two adjacent vertebral segments
- pT2: Tumor confined to three adjacent vertebral segments
- pT3: Tumor confined to four or more adjacent vertebral segments, or any nonadjacent vertebral segments
- pT4: Extension into the spinal canal or great vessels
- pT4a: Extension into the spinal canal

+ Data elements preceded by this symbol are not required for accreditation purposes. These optional elements may be clinically important but are not yet validated or regularly used in patient management.

pT4b: Evidence of gross vascular invasion or tumor thrombus in the great vessels

Pelvis

- pTX: Primary tumor cannot be assessed
- pT0: No evidence of primary tumor
- pT1: Tumor confined to one pelvic segment with no extraosseous extension
- pT1a: Tumor ≤ 8 cm in greatest dimension
- pT1b: Tumor > 8 cm in greatest dimension
- pT2: Tumor confined to one pelvic segment with extraosseous extension or two segments without extraosseous extension
- pT2a: Tumor ≤ 8 cm in greatest dimension
- pT2b: Tumor > 8 cm in greatest dimension
- pT3: Tumor spanning two pelvic segments with extraosseous extension
- pT3a: Tumor ≤ 8 cm in greatest dimension
- pT3b: Tumor > 8 cm in greatest dimension
- pT4: Tumor spanning three pelvic segments or crossing the sacroiliac joint
- pT4a: Tumor involves sacroiliac joint and extends medial to the sacral neuroforamen
- pT4b: Tumor encasement of external iliac vessels or presence of gross tumor thrombus in major pelvic vessels

Regional Lymph Nodes (pN) (Note K)

- pNX: Regional lymph nodes cannot be assessed[#]
- pN0: No regional lymph node metastasis
- pN1: Regional lymph node metastasis

[#] Note: Because of the rarity of lymph node involvement in bone sarcomas, the designation NX may not be appropriate, and cases should be considered N0 unless clinical node involvement clearly is evident.

Distant Metastasis (pM) (required only if confirmed pathologically in this case)

- pM1a: Lung
- pM1b: Metastasis involving distant sites other than lung
Specify site(s), if known: _____

+ Additional Pathologic Findings

+ Specify: _____

Ancillary Studies (required only if applicable)

Immunohistochemistry (specify): _____

Not performed

Cytogenetics (specify): _____

Not performed

Molecular Pathology (specify): _____

Not performed

+ Radiographic Findings (Note F)

+ Specify: _____

+ Not available

+ Preresection Treatment (select all that apply)

- + No known preresection therapy
- + Chemotherapy performed
- + Radiation therapy performed
- + Therapy performed, type not specified
- + Not specified

+ Data elements preceded by this symbol are not required for accreditation purposes. These optional elements may be clinically important but are not yet validated or regularly used in patient management.

Treatment Effect (select all that apply) (Note L)

No known presurgical therapy

Not identified

Present

+ Specify percentage of necrotic tumor (compared with pretreatment biopsy, if available): _____%

Cannot be determined

+ Comment(s)

Explanatory Notes

These recommendations are used for all primary malignant tumors of bone except hematopoietic neoplasms, ie, lymphoma and plasma cell neoplasms.

A. Tumor Site and Processing

Tumor site

Given the strong association between the primary anatomic site and outcome, the 8th edition of the *AJCC Cancer Staging Manual*¹ uses the following site groups for staging purposes:

- Appendicular skeleton, including trunk, skull, and facial bones
- Pelvis
- Spine

This site grouping is reflected by the provision of separate definitions for the primary tumor (T) for each anatomic site.

Fixation

Tissue specimens from bone tumors optimally are received fresh/unfixed because of the importance of ancillary studies, such as cytogenetics, which require fresh tissue.

Tissue Submission for Histologic Evaluation

One section per centimeter of maximum dimension is usually recommended, although fewer sections are needed for very large tumors, especially if they are homogeneous. Tumors known to be high grade from a previous biopsy do not require as many sections as those that were previously diagnosed as low grade, as documentation of a high-grade component will change stage and prognosis in the latter case. Sections should be taken of grossly heterogeneous areas, and there is no need to submit more than 1 section of necrotic tumor (always with a transition to viable tumor), with the exception of chemotherapy effect on osteosarcomas and Ewing sarcoma.² Occasionally, gross pathology can be misleading, and areas that appear to be grossly necrotic may actually be myxoid or edematous. When this happens, additional sections of these areas should be submitted for histologic examination. When estimates of gross necrosis exceed those of histologic necrosis, the greater percentage of necrosis should be recorded on the surgical pathology report. In general, most tumors require 12 sections or fewer, excluding margins. Tumors with greater areas of heterogeneity may need to be sampled more thoroughly.

Fresh tissue for special studies should be submitted at the time the specimen is received. Note that classification of many subtypes of sarcoma is not dependent upon special studies, such as cytogenetics or molecular genetics, but frozen tissue may be needed to enter patients into treatment protocols. Discretion should be used in triaging tissue from sarcomas. Adequate tissue should be submitted for conventional light microscopy before tissue has been taken for cytogenetics, electron microscopy, or molecular analysis.

Molecular Studies

It is important to snap freeze a small portion of tissue whenever possible. This tissue can be used for a variety of molecular assays for tumor-specific molecular translocations (see Table 1) that help in classifying bone tumors.^{3,4} In addition, treatment protocols increasingly require fresh tissue for correlative studies. Approximately 1 cm³ of fresh tissue (less is acceptable for small specimens, including core biopsies) should be cut into small, 0.2-cm fragments, reserving sufficient tissue for histologic examination. This frozen tissue should ideally be stored at minus (-)70°C and can be shipped on dry ice to facilities that perform molecular analysis.

Table 1. Characteristic Cytogenetic and Molecular Events of Bone Tumors

Histologic Type	Cytogenetic Events	Molecular Events	
Chondrosarcoma of bone	Complex	<i>IDH1</i> and <i>IDH2</i> mutations	
Ewing sarcoma	t(11;22)(q24;q12)	<i>EWSR1-FLI1</i> fusion	
	t(21;22)(q12;q12)	<i>EWSR1-ERG</i> fusion	
	t(2;22)(q33;q12)	<i>EWSR1-FEV</i> fusion	
	t(7;22)(p22;q12)	<i>EWSR1-ETV1</i> fusion	
	t(17;22)(q12;q12)	<i>EWSR1-E1AF</i> fusion	
	inv(22)(q12q12)	<i>EWSR1-ZSG</i>	
	t(16;21)(p11;q22)	<i>FUS-ERG</i>	
	t(2;16)(q35;p11)	<i>FUS-FEV</i>	
Ewing-like sarcomas [#]	t(20;22)(q13;q12)	<i>EWSR1-NFATC2</i>	
	t(6;22)(p21;q12)	<i>EWSR1-POU5F1</i>	
	t(4;22)(q31;q12)	<i>EWSR1-SMARCA5</i>	
	Submicroscopic inv(22)in		
	t(1;22)(p36.1;q12)	<i>EWSR1-PATZ</i>	
	t(2;22)(q31;q12)	<i>EWSR1-SP3</i>	
	t(4;19)(q35;q13)	<i>CIC-DUX4</i>	
Osteosarcoma			
	Low grade central	Simple	<i>MDM2</i> amplification
	Parosteal	Ring chromosomes	12q13-15 amplification
	High grade	Complex	

[#] Ewing-like sarcomas are similar both clinically and histologically to Ewing sarcoma, but it is not known at the present time whether they represent true Ewing sarcomas. They are treated the same as true Ewing sarcomas.

B. Location of Neoplasms of Bone

Relevant Radiologic Findings

Radiographic imaging plays an especially critical role in the diagnosis of bone tumors. Close collaboration with an experienced musculoskeletal radiologist and orthopedic surgeon is recommended.

Figure 1 is a diagrammatic representation of the “anatomic” regions of a long bone. These locations are very important in classifying bone tumors. For instance, chondroblastomas almost always arise in the epiphysis. Epiphyses and apophyses are secondary ossification centers and therefore are embryonic equivalents. The greater and lesser trochanters are apophyses, while the epiphyses are at the ends of long bones.

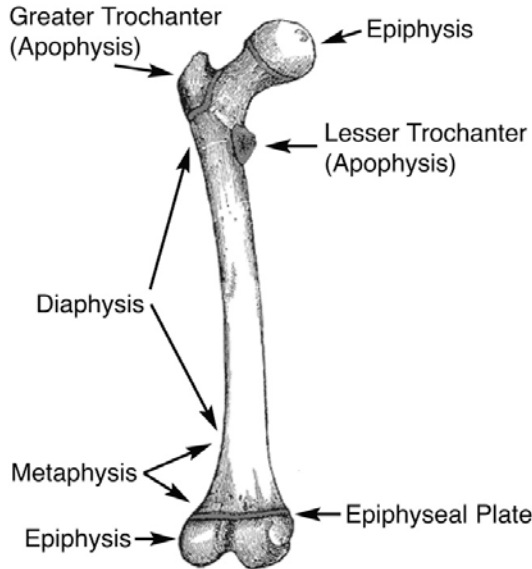


Figure 1. Important anatomic landmarks for tumor diagnosis in long bones. Adapted from *Gray's Anatomy*.¹⁵

C. Classification of Bone Tumors

Intraoperative Consultation

Histologic classification of bone tumors is sufficiently complex that, in many cases, it is unreasonable to expect a precise classification of these tumors based on an intraoperative consultation. A complete understanding of the surgeon's treatment algorithm is recommended before rendering a frozen section diagnosis. In the case of primary bone tumors, an intraoperative diagnosis of benign versus malignant will generally guide the immediate decision to curette, excise, or wait for permanent sections, and certain therapeutic options may be lost if the wrong path is pursued. Intraoperative consultation is useful in assessing if "lesional" tissue is present and whether or not this tissue is necrotic, and in constructing a differential diagnosis that can direct the proper triage of tissue for flow cytometry (lymphoma), electron microscopy, and molecular studies/cytogenetics. Tissue triage optimally is performed at the time of frozen section. In many cases, it is important that a portion of tissue be submitted for ancillary studies, even from fine-needle aspiration (FNA) and core needle biopsy specimens, once sufficient tissue has been submitted for histologic evaluation.

Tumor Classification From Biopsies

It is not always possible to classify bone tumors precisely based on biopsy material, especially FNA and core needle biopsy specimens. Although pathologists should make every attempt to classify lesions in small biopsy specimens, on occasion, stratification into very basic diagnostic categories, such as lymphoma, carcinoma, melanoma, and sarcoma, is all that is possible. In some cases, precise classification is only possible in open biopsies or resection specimens.

WHO Classification of Malignant Bone Tumors

Classification of tumors should be made according to the World Health Organization (WHO) classification of bone tumors listed below.⁵

WHO Classification of Malignant Bone Tumors

Chondrogenic Tumors

- Intermediate (locally aggressive)
 - Chondromyxoid fibroma
 - Atypical cartilaginous tumor/chondrosarcoma grade I
- Intermediate (rarely metastasizing)
 - Chondroblastoma
- Malignant
 - Chondrosarcoma
 - Grade II, Grade III
 - Dedifferentiated chondrosarcoma
 - Clear cell chondrosarcoma
 - Mesenchymal chondrosarcoma

Osteogenic Tumors

- Intermediate (locally aggressive)
 - Osteoblastoma
- Malignant
 - Low-grade central osteosarcoma
 - Conventional osteosarcoma
 - Chondroblastic
 - Fibroblastic
 - Osteoblastic
 - Telangiectatic
 - Small cell
 - Secondary
 - Parosteal
 - Periosteal
 - High grade surface

Fibrogenic Tumors

- Intermediate (locally aggressive)
 - Desmoplastic fibroma of bone
- Malignant
 - Fibrosarcoma of bone

Hematopoietic Tumors*

- Plasma cell myeloma*
- Solitary plasmacytoma of bone*
- Primary non-Hodgkin lymphoma, NOS*

Osteoclastic Giant Cell Rich Tumors

- Intermediate (locally aggressive, rarely metastasizing)
 - Giant cell tumor of bone
- Malignant
 - Malignancy in giant cell tumor of bone

Notochordal Tumors

- Malignant
 - Chordoma

Vascular Tumors

- Intermediate (locally aggressive, rarely metastasizing)
 - Epithelioid hemangioma
- Malignant

Epithelioid hemangioendothelioma
Angiosarcoma

Myogenic Tumors
Leiomyosarcoma of bone

Lipogenic Tumors
Liposarcoma of bone

Tumors of Undefined Neoplastic Nature
Intermediate (locally aggressive)
Aneurysmal bone cyst
Langerhans cell histiocytosis
Monostotic
Polyostotic

Miscellaneous Tumors
Ewing sarcoma
Adamantinoma
Undifferentiated high-grade pleomorphic sarcoma

* *Primary malignant lymphomas and plasma cell neoplasms are not staged using the AJCC system for malignant bone tumors.*

D. Grading

The grading of bone tumors is largely driven by the histologic diagnosis, and traditionally grading has been based on the system advocated by Broders, which assesses cellularity and nuclear features/degree of anaplasia.⁶ The eighth edition of the *AJCC Cancer Staging Manual* recommends a 2-tiered system (low vs high grade) for recording grading.¹ Histologic grading uses a 3-tiered system: G1 is considered low grade, and G2 and G3 are grouped together as high grade for biological grading. However, we advocate a more pragmatic approach to grading aggressive and malignant primary tumors of bone.

Two bone tumors that are locally aggressive and metastasize infrequently, and thus are usually low grade, are low-grade central osteosarcoma and parosteal osteosarcoma. Periosteal osteosarcoma is generally regarded as a grade 2 osteosarcoma. Primary bone tumors that are generally high grade include malignant giant cell tumor, Ewing sarcoma, angiosarcoma, dedifferentiated chondrosarcoma, conventional osteosarcoma, telangiectatic osteosarcoma, small cell osteosarcoma, secondary osteosarcoma, and high-grade surface osteosarcoma.

Grading of conventional chondrosarcoma is based on cellularity, cytologic atypia, and mitotic figures. Grade 1 (low-grade) chondrosarcoma is hypocellular and similar histologically to enchondroma. Grade 2 (intermediate-grade) chondrosarcoma is more cellular than grade 1 chondrosarcoma; has more cytologic atypia, greater hyperchromasia and nuclear size; or has extensive myxoid stroma. Grade 3 (high-grade) chondrosarcoma is hypercellular, pleomorphic, and contains prominent mitotic activity.

Mesenchymal chondrosarcoma, fibrosarcoma, leiomyosarcoma, liposarcoma, undifferentiated high-grade pleomorphic sarcoma of bone and other "soft tissue-type" sarcomas that rarely occur in bone can be graded according to the French Federation of Cancer Centers Sarcoma Group (FNCLCC) grading system⁷ (see College of American Pathologists protocol for soft tissue tumors⁸).

Chordomas are locally aggressive lesions with a propensity for metastasis late in their clinical course and are not graded. Adamantinomas tend to have a low-grade clinical course, but this is variable. Fortunately, they are very rare. According to the WHO classification of tumors of bone, adamantinomas are considered low grade.

Bone Tumor Grades (Summary)

Grade 1 (Low Grade)

Low-grade intramedullary (central) osteosarcoma

Parosteal osteosarcoma
Grade I chondrosarcoma
Clear cell chondrosarcoma

Grade 2

Periosteal osteosarcoma
Grade II chondrosarcoma
Classic adamantinoma
Chordoma

Grade 3 (High Grade)

Ewing sarcoma
Conventional osteosarcoma
Telangiectactic osteosarcoma
Mesenchymal chondrosarcoma
Small cell osteosarcoma
Secondary osteosarcoma
High-grade surface osteosarcoma
Dedifferentiated chondrosarcoma
Dedifferentiated chordoma
Malignancy in giant cell tumor
Grade III chondrosarcoma
Soft-tissue type sarcomas (eg, leiomyosarcoma)
Undifferentiated high-grade pleomorphic sarcoma

Mitotic rate is determined by counting mitotic figures in 10 contiguous high-power fields (HPF) (40x objective), in the most mitotically active area of the tumor, away from areas of necrosis. The area of 1 HPF originally used measured 0.1734 mm². However, the area of 1 HPF using most modern microscopes with wider 40x lenses will most likely be higher. Pathologists are encouraged to determine the field area of their 40x lenses and divide 0.1734 by the obtained field area to obtain a conversion factor. The number of mitotic figures in 10 HPF multiplied by the obtained conversion factor and rounded to the nearest whole number should be used for reporting purposes.

TNM Grading

The 8th edition of the American Joint Committee on Cancer (AJCC) and International Union Against Cancer (UICC) staging system for bone tumors includes a 3-grade system but effectively collapses into high grade and low grade.^{1,9} Grading in the TNM grading system is based on differentiation only and does not generally apply to sarcomas.

GX	Grade cannot be assessed
G1	Well differentiated, low grade
G2	Moderately differentiated, high grade
G3	Poorly differentiated, high grade

For purposes of using the AJCC staging system (see note J), 3-grade systems can be converted to a 2-grade (TNM) system as follows: grade 1 = low-grade; grade 2 and grade 3 = high-grade.

E. Lymphovascular Invasion

Lymphovascular invasion (LVI) indicates whether microscopic lymphovascular invasion is identified. LVI includes lymphatic invasion, vascular invasion, or lymphovascular invasion. By AJCC/UICC convention, LVI does not affect the T category indicating local extent of tumor unless specifically included in the definition of a T category.

F. Relevant Radiologic Findings

Radiographic imaging plays an especially critical role in the diagnosis of bone tumors. Close collaboration with an experienced musculoskeletal radiologist and orthopedic surgeon is recommended.

G. Definition of Procedures

The following is a list of guidelines to be used in defining what type of procedure has been performed. This is based on the surgeon's intent and not based on the pathologic assessment of the margins.

Intralesional Resection

Leaving gross tumor behind. Partial debulking or curettage are examples.

Marginal Resection

Removing the tumor and its pseudocapsule with a relatively small amount of adjacent tissue. There is no gross tumor at the margin; however, microscopic tumor may be present. Note that occasionally, a surgeon will perform an "excisional" biopsy, which effectively accomplishes the same thing as a marginal resection.

Segmental/Wide Resection

An intracompartmental resection. A single piece of bone is resected, including the lesion and a cuff of normal bone.

Radical Resection

The removal of an entire bone, or the excision of the adjacent muscle groups if the tumor is extracompartmental.

H. Histologic Classification of Treated Lesions

Due to extensive treatment effects, such as necrosis, fibrosis, and chemotherapy-induced and radiation-induced pleomorphism, it may not be possible to classify some lesions that were either never biopsied or where the biopsy was insufficient for a precise diagnosis. In problematic cases, the grade of the pretreatment specimen (if available) should take precedence.

I. Margins

It has been recommended that for all margins <2 cm, the distance of the tumor from the margin be reported in centimeters.¹⁰ However, there is a lack of agreement on this issue. We recommend specifying the location of all margins <2 cm. Margins from bone tumors should be taken as *perpendicular* margins, if possible. If the tumor is >2 cm from the margin, the marrow can be scooped out and submitted as a margin.

J. Pathologic Stage Classification (TNM and Stage Groupings)

The 8th edition TNM staging system for bone tumors of the AJCC and the UICC is recommended.^{1,9}

The classification is to be applied to all primary tumors of bone. Anatomic site is known to influence outcome; therefore, outcome data should be reported specifying site. Site groups for bone sarcomas are the following: appendicular skeleton, including trunk, skull and facial bones, pelvis, and spine. Pathologic staging includes pathologic data obtained from examination of a resected specimen sufficient to evaluate the highest T category, histopathologic type and grade, regional lymph nodes as appropriate, or distant metastasis. Because regional lymph node involvement from bone tumors is rare, the pathologic stage grouping includes any of the following combinations: pT pG pN pM, or pT pG cN cM, or cT cN pM

TNM Descriptors

For identification of special cases of TNM or pTNM classifications, the "m" suffix and the "y" and "r" prefixes are used. Although they do not affect the stage grouping, they indicate cases needing separate analysis.

The "m" suffix indicates the presence of multiple primary tumors in a single site and is recorded in parentheses: pT(m)NM.

The "y" prefix indicates those cases in which classification is performed during or following initial multimodality therapy (ie, neoadjuvant chemotherapy, radiation therapy, or both chemotherapy and radiation therapy). The cTNM or pTNM category is identified by a "y" prefix. The ycTNM or ypTNM categorizes the extent of tumor actually present at the time of that examination. The "y" categorization is not an estimate of tumor prior to multimodality therapy (ie, before initiation of neoadjuvant therapy).

The “r” prefix indicates a recurrent tumor when staged after a documented disease-free interval, and is identified by the “r” prefix: rTNM.

T Category Considerations (Figures 2 and 3)

Spine segments for staging:

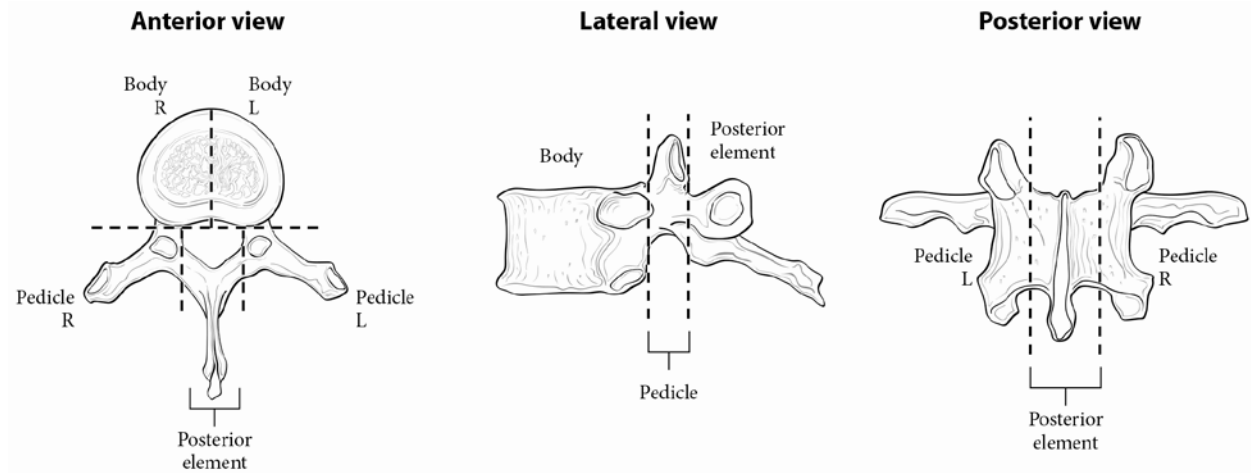


Figure 2. Spine segments for staging. Used with permission of the American Joint Committee on Cancer (AJCC), Chicago, Illinois. The original source for this material is the AJCC Cancer Staging Manual (2017) published by Springer Science and Business Media LLC, www.springerlink.com.

Pelvic segments for staging:

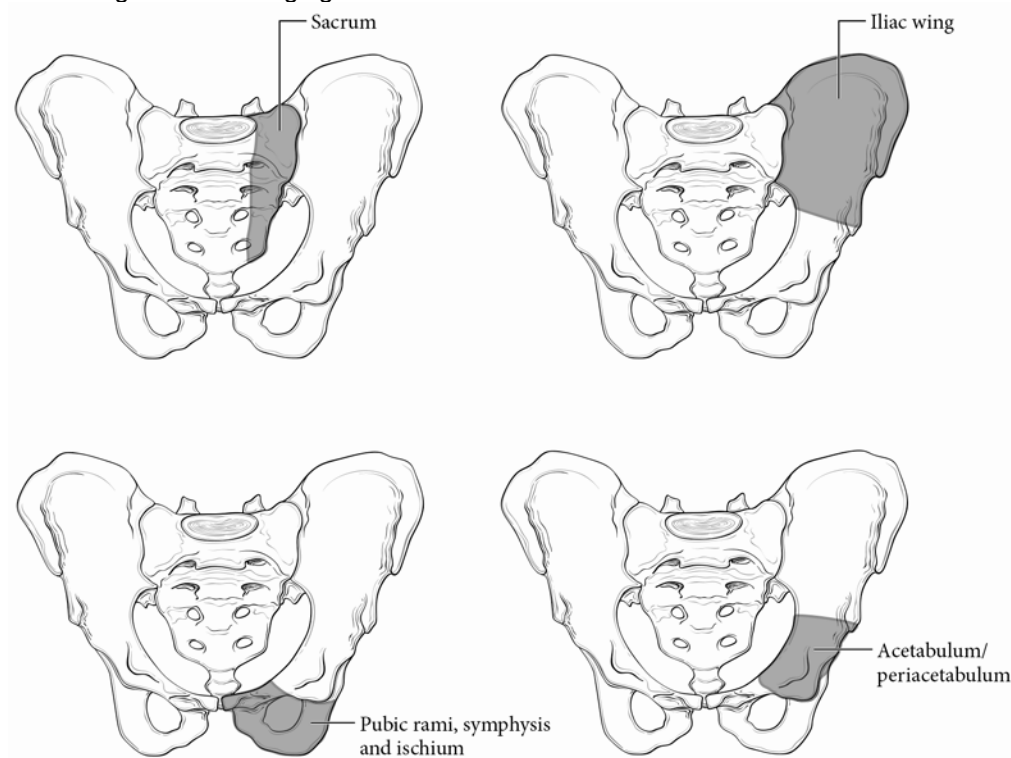


Figure 3. Pelvic segments for staging. Used with permission of the American Joint Committee on Cancer (AJCC), Chicago, Illinois. The original source for this material is the AJCC Cancer Staging Manual (2017) published by Springer Science and Business Media LLC, www.springerlink.com

N Category Considerations

Because of the rarity of lymph node involvement in sarcomas, the designation NX may not be appropriate and could be considered N0 if no clinical involvement is evident.

Stage Groupings

Appendicular Skeleton, Trunk, Skull, and Facial Bones

Stage IA	T1	N0	M0 [#]	G1,GX	Low grade
Stage IB	T2	N0	M0	G1,GX	Low grade
	T3	N0	M0	G1,GX	Low grade
Stage IIA	T1	N0	M0	G2,G3	High grade
Stage IIB	T2	N0	M0	G2,G3	High grade
Stage III	T3	N0	M0	G2,G3	High grade
Stage IVA	Any T	N0	M1a	Any G	Any grade
Stage IVB	Any T	N1	Any M	Any G	Any grade
	Any T	Any N	M1b	Any G	Any grade

[#] M0 is defined as no distant metastasis.

Spine and Pelvis

There are no AJCC prognostic stage groupings for spine and pelvis.

Additional Descriptors

Residual Tumor (R)

Tumor remaining in a patient after therapy with curative intent (eg, surgical resection for cure) is categorized by a system known as R classification, shown below.

RX	Presence of residual tumor cannot be assessed
R0	No residual tumor
R1	Microscopic residual tumor
R2	Macroscopic residual tumor

For the surgeon, the R classification may be useful to indicate the known or assumed status of the completeness of a surgical excision. For the pathologist, the R classification is relevant to the status of the margins of a surgical resection specimen. That is, tumor involving the resection margin on pathologic examination may be assumed to correspond to residual tumor in the patient and may be classified as macroscopic or microscopic according to the findings at the specimen margin(s).

K. Lymph Nodes

Regional lymph node metastasis is extremely rare in adult bone sarcomas. Nodes are not sampled routinely, and it is not necessary to exhaustively search for nodes. When present, regional lymph node metastasis has prognostic importance and should be reported.

L. Response to Chemotherapy/Radiation Therapy Effect

It is essential to estimate neoadjuvant treatment effect in primary Ewing sarcoma and osteosarcoma of bone, as these have been shown to have prognostic significance.^{1,11-14} An entire representative slice of the tumor taken through the long axis should be mapped using a grid pattern diagram, photocopy, or radiologic film to indicate the site for each tumor block. In addition, the remainder of the neoplasm should be sampled at the rate of 1 section per centimeter. Areas of soft tissue extension and the interface of tumor with normal tissue should also be sampled. The sum of all viable areas measured microscopically is divided by the total cross-sectional area occupied by tumor to arrive at a percentage. Prognostically significant therapy response in osteosarcoma, according to most series, is defined at 90%, with those tumors showing 90% therapy response associated with a favorable prognosis.^{11,12} There are 2 protocols to assess response to therapy in Ewing sarcoma. Response can be assessed in the same manner as osteosarcoma or by the system of Picci, which is expressed as grade I (macroscopic viable tumor), grade II (microscopic viable tumor), or grade III (no viable tumor).^{13,14}

References

1. Amin MB, Edge SB, Greene FL, et al, eds. *AJCC Cancer Staging Manual*. 8th ed. New York, NY: Springer; 2017.
2. Pawel B, Bahrami A, Hicks MJ, Rudzinski E. Protocol for the Examination of Specimens From Pediatric Patients With Ewing Sarcoma (ES). 2016. Available at www.cap.org/cancerprotocols.
3. Taylor BS, Barretina J, Maki RG, Antonescu CR, Singer S, Ladanyi M. Advances in sarcoma genomics and new therapeutic targets. *Nat Rev Cancer*. 2011;11(8):541-547.
4. Rubin BP, Lazar JF, Oliveira AM. Molecular pathology of bone and soft tissue tumors. In: Tubbs R, Stoler M. *Cell and Tissue Based Molecular Pathology*. Philadelphia, PA: Churchill Livingstone; 2009.
5. Fletcher CDM, Bridge JA, Hogendoorn PCW, Mertens F, eds. *WHO Classification of Tumors of Soft Tissue and Bone*. 4th ed. Geneva, Switzerland; WHO Press; 2013.
6. Inwards CY, Unni KK. Classification and grading of bone sarcomas. *Hematol Oncol Clin North Am*. 1995;9(3):545-569.
7. Guillou L, Coindre JM, Bonichon F, et al. Comparative study of the National Cancer Institute and French Federation of Cancer Centers Sarcoma Group grading systems in a population of 410 adult patients with soft tissue sarcoma. *J Clin Oncol*. 1997;15(1):350-362.
8. Laurini JA, Cooper K, Fletcher CDM, et al. Protocol for the Examination of Specimens From Patients With Soft Tissue Tumors. 2017. Available at www.cap.org/cancerprotocols.
9. Brierley JD, Gospodarowicz MK, Wittekind C, et al, eds. *TNM Classification of Malignant Tumours*. 8th ed. Oxford, UK: Wiley; 2016.
10. Abdul-Karim FW, Bauer TW, Kilpatrick SE, et al. Recommendations for the reporting of bone tumors. Association of Directors of Anatomic and Surgical Pathology. *Hum Pathol*. 2004;35(10):1173-1178.
11. Picci P, Sangiorgi L, Rougraff BT, Neff JR, Casadei R, Campanacci M. Relationship of chemotherapy-induced necrosis and surgical margins to local recurrence in osteosarcoma. *J Clin Oncol*. 1994;12(12):2699-2705.
12. Raymond AK, Chawla SP, Carrasco CH, et al. Osteosarcoma chemotherapy effect: a prognostic factor. *Semin Diagn Pathol*. 1987;4(3):212-236.
13. Bacci G, Ferrari S, Bertoni F, et al. Prognostic factors in nonmetastatic Ewing's sarcoma of bone treated with adjuvant chemotherapy: analysis of 359 patients at the Istituto Ortopedico Rizzoli. *J Clin Oncol*. 2000;18(1):4-11.
14. Picci P, Bohling T, Bacci G, et al. Chemotherapy-induced tumor necrosis as a prognostic factor in localized Ewing's sarcoma of the extremities. *J Clin Oncol*. 1997;15(4):1553-1559.
15. *Gray's Anatomy of the Human Body*. Philadelphia, PA: Lea & Febiger; 1918.