



## Protocol for the Examination of Specimens From Patients With Neuroendocrine Tumors (Carcinoid Tumors) of the Appendix

Version: AppendixNET 4.0.0.1

Protocol Posting Date: June 2017

Includes pTNM requirements from the 8<sup>th</sup> Edition, AJCC Staging Manual

**For accreditation purposes, this protocol should be used for the following procedures AND tumor types:**

Procedure	Description
Excision	Includes specimens designated appendectomy, and right hemicolectomy
Tumor Type	Description
Well differentiated neuroendocrine tumor	

**This protocol is NOT required for accreditation purposes for the following:**

Procedure
Biopsy
Primary resection specimen with no residual cancer (eg, following neoadjuvant therapy)
Recurrent tumor
Cytologic specimens

**The following tumor types should NOT be reported using this protocol:**

Tumor Type
Poorly differentiated neuroendocrine carcinomas (including small cell and large cell neuroendocrine carcinomas) (consider the Appendix Carcinoma protocol)
Goblet cell carcinoid tumors(consider the Appendix Carcinoma protocol)

### Authors

Chanjuan Shi, MD, PhD\*; Volkan Adsay, MD; Emily K. Bergsland, MD; Jordan Berlin, MD; Philip A. Branton, MD; Patrick L. Fitzgibbons, MD; Wendy L. Frankel, MD; Sanjay Kakar, MD; Veronica Klepeis, MD, PhD; David S. Klimstra, MD; Joseph T. Lewis, MD; Laura H. Tang, MD; Eugene A Woltering, MD; Mary K Washington, MD, PhD

With guidance from the CAP Cancer and CAP Pathology Electronic Reporting Committees.

\* Denotes primary author. All other contributing authors are listed alphabetically.

### Accreditation Requirements

This protocol can be utilized for a variety of procedures and tumor types for clinical care purposes. For accreditation purposes, only the definitive primary cancer resection specimen is required to have the core and conditional data elements reported in a synoptic format.

- Core data elements are required in reports to adequately describe appropriate malignancies. For accreditation purposes, essential data elements must be reported in all instances, even if the response is “not applicable” or “cannot be determined.”
- Conditional data elements are only required to be reported if applicable as delineated in the protocol. For instance, the total number of lymph nodes examined must be reported, but only if nodes are present in the specimen.
- Optional data elements are identified with “+” and although not required for CAP accreditation purposes, may be considered for reporting as determined by local practice standards.

The use of this protocol is not required for recurrent tumors or for metastatic tumors that are resected at a different time than the primary tumor. Use of this protocol is also not required for pathology reviews performed at a second institution (ie, secondary consultation, second opinion, or review of outside case at second institution).

### Synoptic Reporting

All core and conditionally required data elements outlined on the surgical case summary from this cancer protocol must be displayed in synoptic report format. Synoptic format is defined as:

- Data element: followed by its answer (response), outline format without the paired "Data element: Response" format is NOT considered synoptic.
- The data element should be represented in the report as it is listed in the case summary. The response for any data element may be modified from those listed in the case summary, including “Cannot be determined” if appropriate.
- Each diagnostic parameter pair (Data element: Response) is listed on a separate line or in a tabular format to achieve visual separation. The following exceptions are allowed to be listed on one line:
  - Anatomic site or specimen, laterality, and procedure
  - Pathologic Stage Classification (pTNM) elements
  - Negative margins, as long as all negative margins are specifically enumerated where applicable
- The synoptic portion of the report can appear in the diagnosis section of the pathology report, at the end of the report or in a separate section, but all Data element: Responses must be listed together in one location

Organizations and pathologists may choose to list the required elements in any order, use additional methods in order to enhance or achieve visual separation, or add optional items within the synoptic report. The report may have required elements in a summary format elsewhere in the report IN ADDITION TO but not as replacement for the synoptic report i.e. all required elements must be in the synoptic portion of the report in the format defined above.

### CAP Laboratory Accreditation Program Protocol Required Use Date: March 2018\*

\* Beginning January 1, 2018, the 8th edition AJCC Staging Manual should be used for reporting pTNM.

## CAP Appendix NET Protocol Summary of Changes

---

### Version 4.0.0.1

Corrected Notes for area on table to 2mm<sup>2</sup>

### Version 4.0.0.0

#### The following data elements were modified:

Pathologic Stage Classification (pTNM, AJCC 8th Edition)  
Histologic Type and Grade  
Mitotic Rate  
Microscopic Tumor Extension

#### The following data elements have been deleted:

Specimen Integrity  
Specimen Size

## Surgical Pathology Cancer Case Summary

---

Protocol posting date: June 2017

### APPENDIX NEUROENDOCRINE TUMOR

Select a single response unless otherwise indicated.

#### Procedure

- Appendectomy  
 Right hemicolectomy  
 Other (specify): \_\_\_\_\_

#### Tumor Site (Note A)

- Proximal half of appendix  
 Distal half of appendix  
 Diffusely involving appendix  
 Appendix, not otherwise specified  
 Other (specify): \_\_\_\_\_

#### Tumor Size (Note B)

- Greatest dimension (centimeters): \_\_\_\_ cm  
 + Additional dimensions (centimeters): \_\_\_\_ x \_\_\_\_ cm  
 Cannot be determined (explain): \_\_\_\_\_

#### Histologic Type and Grade (Notes C and D)

- G1: Well-differentiated neuroendocrine tumor  
 G2: Well-differentiated neuroendocrine tumor  
 G3: Well-differentiated neuroendocrine tumor  
 Other (specify): \_\_\_\_\_  
 GX: Well-differentiated neuroendocrine tumor, grade cannot be assessed  
 Not applicable

*Note: For poorly differentiated (high-grade) neuroendocrine carcinomas, the College of American Pathologists (CAP) protocol for carcinoma of the appendix should be used.<sup>1</sup>*

Mitotic rate and/or Ki67 labeling index is required to determine histologic grade.

#### Mitotic Rate (Note D)

- <2 mitoses/2mm<sup>2</sup>  
 2 to 20 mitoses/2mm<sup>2</sup>  
     + Specify mitoses per 2mm<sup>2</sup>: \_\_\_\_\_  
 >20 mitoses per 2mm<sup>2</sup>  
     + Specify mitoses per 2mm<sup>2</sup>: \_\_\_\_\_  
 Cannot be determined (explain): \_\_\_\_\_  
 Not applicable

*Note: Mitotic rate should be reported as number of mitoses per 2 mm<sup>2</sup>, by evaluating at least 10 mm<sup>2</sup> in the most mitotically active part of the tumor (eg, if using a microscope with a field diameter of 0.55 mm, count 42 high-power fields [10 mm<sup>2</sup>] and divide the resulting number of mitoses by 5 to determine the number of mitoses per 2 mm<sup>2</sup> needed to assign tumor grade).*

#### Ki-67 Labeling Index (Note D)

- <3%  
 3% to 20%  
     + Specify Ki-67 percentage: \_\_\_\_%  
 >20%

+ Data elements preceded by this symbol are not required for accreditation purposes. These optional elements may be clinically important but are not yet validated or regularly used in patient management.

- + Specify Ki-67 percentage: \_\_\_\_\_%
- Cannot be determined (explain): \_\_\_\_\_
- Not applicable

**Tumor Extension**

- No evidence of primary tumor
- Tumor invades the lamina propria
- Tumor invades the submucosa
- Tumor invades the muscularis propria
- Tumor invades the subserosa/mesoappendix without involvement of visceral peritoneum
- Tumor perforates the visceral peritoneum (serosa)
- Tumor directly invades other adjacent organs or structures<sup>#</sup> (specify): \_\_\_\_\_
- Cannot be assessed

<sup>#</sup> This excludes direct mural extension to adjacent subserosa of adjacent bowel, but may include abdominal wall and skeletal muscle.

**Margins (Note E)**

Note: Use the section only if all margins are uninvolved and all margins can be assessed.

- All margins are uninvolved by tumor
  - Margins examined: \_\_\_\_\_
  - Note: Margins may include proximal, distal, radial or mesenteric and others.
  - + Distance of tumor from closest margin (millimeters or centimeters): \_\_\_\_ mm or \_\_\_\_ cm
  - + Specify closest margin: \_\_\_\_\_

Individual margin reporting required if any margins are involved or margin involvement cannot be assessed

For appendectomy specimens only

Proximal Margin

- Cannot be assessed
- Uninvolved by tumor
- Involved by tumor

Radial or Mesenteric Margin

- Cannot be assessed
- Uninvolved by tumor
- Involved by tumor

Other Margin(s) (required only if applicable)

- Specify margin(s): \_\_\_\_\_
- Cannot be assessed
- Uninvolved by tumor
- Involved by tumor

For right hemicolectomy specimens only

Proximal Margin

- Cannot be assessed
- Uninvolved by tumor
- Involved by tumor

Distal Margin

- Cannot be assessed
- Uninvolved by tumor
- Involved by tumor

+ Data elements preceded by this symbol are not required for accreditation purposes. These optional elements may be clinically important but are not yet validated or regularly used in patient management.

Radial and Mesenteric Margin

- Cannot be assessed
- Uninvolved by tumor
- Involved by tumor

Other Margin(s) (required only if applicable)

- Specify margin(s): \_\_\_\_\_
- Cannot be assessed
  - Uninvolved by tumor
  - Involved by tumor

**Lymphovascular Invasion**

- Not identified
- Present
- Cannot be determined

**+ Perineural Invasion**

- +  Not identified
- +  Present
- +  Cannot be determined

**Regional Lymph Nodes**

- No lymph nodes submitted or found

Lymph Node Examination (required only if lymph nodes are present in the specimen)

- Number of Lymph Nodes Involved: \_\_\_\_\_
- Number cannot be determined (explain): \_\_\_\_\_

- Number of Lymph Nodes Examined: \_\_\_\_\_
- Number cannot be determined (explain): \_\_\_\_\_

**Pathologic Stage Classification (pTNM, AJCC 8<sup>th</sup> Edition) (Note F)**

*Note: Reporting of pT, pN, and (when applicable) pM categories is based on information available to the pathologist at the time the report is issued. Only the applicable T, N, or M category is required for reporting; their definitions need not be included in the report. The categories (with modifiers when applicable) can be listed on 1 line or more than 1 line.*

TNM Descriptors (required only if applicable) (select all that apply)

- m (multiple primary tumors)
- r (recurrent)
- y (posttreatment)

Primary Tumor (pT)

- pTX: Primary tumor cannot be assessed
- pT0: No evidence of primary tumor
- pT1: Tumor 2 cm or less in greatest dimension
- pT2: Tumor more than 2 cm but less than or equal to 4 cm
- pT3: Tumor more than 4 cm or with subserosal invasion or involvement of the mesoappendix
- pT4: Tumor perforates the peritoneum or directly invades other adjacent organs or structures (excluding direct mural extension to adjacent subserosa of adjacent bowel), eg, abdominal wall and skeletal muscle

+ Data elements preceded by this symbol are not required for accreditation purposes. These optional elements may be clinically important but are not yet validated or regularly used in patient management.

Regional Lymph Nodes (pN)

- pNX: Regional lymph nodes cannot be assessed  
 pN0: No regional lymph node metastasis  
 pN1: Regional lymph node metastasis

Distant Metastasis (required only if confirmed pathologically in this case)

- pM1: Distant metastasis  
 pM1a: Metastasis confined to liver  
 pM1b: Metastasis in at least one extrahepatic site (eg, lung, ovary, nonregional lymph node, peritoneum, bone)  
 pM1c: Both hepatic and extrahepatic metastases  
Specify site(s), if known: \_\_\_\_\_

**+ Additional Pathologic Findings (select all that apply) (Note G)**

- +  None identified  
+  Tumor necrosis  
+  Acute appendicitis  
+  Other (specify): \_\_\_\_\_

**+ Comment(s)**

## Explanatory Notes

---

### A. Application and Tumor Location

This protocol applies to well-differentiated neuroendocrine tumors (carcinoid tumors) of the appendix of any size. For poorly differentiated neuroendocrine carcinomas (including small cell carcinomas and large cell neuroendocrine carcinomas) and goblet cell carcinoid tumor, use the CAP cancer protocol for carcinoma of the appendix<sup>1</sup>.

Although the “goblet cell carcinoid tumors” give the impression of belonging to the generic category of well-differentiated neuroendocrine tumors by their name “carcinoid,” recent studies have shown that most tumors with goblet cell pattern that previously classified as goblet cell carcinoid are in fact adenocarcinomas (termed “adenocarcinoma ex-goblet cell carcinoid tumor” or “appendiceal crypt cell adenocarcinoma” and behave aggressively as adenocarcinomas, and should be classified under adenocarcinomas (see CAP protocol for carcinoma of the appendix).<sup>2,3</sup>

The appendix is a common site of gastrointestinal neuroendocrine tumors, usually presenting as small solitary lesions incidentally discovered after appendectomy. Appendiceal neuroendocrine tumors are commonly diagnosed at a young age and arise in the deep mucosa or submucosa. Unlike other gastrointestinal neuroendocrine tumors or appendiceal adenocarcinomas, tumor size is considered more important than depth of invasion for appendiceal neuroendocrine tumor. Therefore, the staging system for appendiceal neuroendocrine tumors is different from those for other neuroendocrine tumors of the gut.<sup>4</sup>

### B. Tumor Size

Appendiceal neuroendocrine tumors smaller than 1.0 cm do not recur or metastasize, whereas those between 1.0 and 2.0 cm rarely do.<sup>5</sup> Tumor size >2.0 cm and mesoappendiceal invasion<sup>6</sup> have been correlated with nodal metastasis, but not with poor outcome.<sup>7</sup> For these reasons, appendectomy is usually sufficient for tumors 1.0 cm or smaller, as well as many tumors between 1.0 and 2.0 cm. More extensive procedures (eg, right hemicolectomy) are usually reserved for patients with tumors larger than 2.0 cm or with invasion beyond the muscularis propria.

### C. Histologic Type

Most appendiceal NETs are low grade, with none to few mitoses and no necrosis, and have traditionally been classified as “carcinoids.” Although the term “carcinoid tumor” remains in widespread use, this term may cause confusion for clinicians, who might view a carcinoid tumor as a serotonin-producing tumor associated with functional manifestations of carcinoid syndrome. The use of the term “carcinoid” for neuroendocrine tumor reporting is therefore discouraged for these reasons.

Immunohistochemistry and other ancillary techniques are generally not required to diagnose well-differentiated neuroendocrine tumors. Specific markers that may be used to establish neuroendocrine differentiation include chromogranin A, synaptophysin, and CD56.<sup>8</sup> Because of their relative sensitivity and specificity, chromogranin A and synaptophysin are recommended.

Although specific histologic patterns in well-differentiated neuroendocrine tumors, such as trabecular, insular, and glandular, roughly correlate with tumor location,<sup>9</sup> these patterns have not been clearly shown independently to predict response to therapy or risk of nodal metastasis and are rarely reported in clinical practice. Most appendiceal neuroendocrine tumors are derived from enterochromaffin cells. Rarely, L-cell neuroendocrine tumors of the appendix are encountered; because of their distinctive growth pattern of tear-drop-shaped tubules embedded in a fibrous stroma,<sup>10</sup> these lesions are sometimes called tubular neuroendocrine tumors. It should be noted that these tumors are negative for chromogranin A but express enteroglucagon, peptide YY, and pancreatic polypeptide. Tubular neuroendocrine tumors are usually small lesions confined to the appendix and are found in female patients. These lesions exhibit benign behavior and should not be confused with adenocarcinoma.

### D. Histologic Grade

Cytologic atypia in well differentiated neuroendocrine tumors has no impact on clinical behavior of these tumors. The WHO classification<sup>11</sup> and others<sup>12</sup> use mitotic rate and/or Ki-67 index as one of the criteria for potential for

aggressive behavior. Mitotic rate should be reported as number of mitoses per 2 mm<sup>2</sup>, by evaluating at least 10mm<sup>2</sup> in the most mitotically active part of the tumor. Only clearly identifiable mitotic figures should be counted; hyperchromatic, karyorrhectic, or apoptotic nuclei are excluded. Because of variations in field size, the number of high-power fields (HPF) (at 40X magnification) for 10 mm<sup>2</sup> (thereby 2 mm<sup>2</sup>) must be determined for each microscope (Table 1). For example, if using a microscope with a field diameter of 0.55 mm, count 42 HPF and divide the resulting number of mitoses by 5 to determine the number of mitoses per 2 mm<sup>2</sup> needed to assign tumor grade.

**Table 1. Number of HPF Required for 10 mm<sup>2</sup> Using Microscopes With Different Field Diameter**

Field Diameter (mm)	Area (mm <sup>2</sup> )	Number of HPF for 10 mm <sup>2</sup>
0.40	0.125	80
0.41	0.132	75
0.42	0.139	70
0.43	0.145	69
0.44	0.152	65
0.45	0.159	63
0.46	0.166	60
0.47	0.173	58
0.48	0.181	55
0.49	0.189	53
0.50	0.196	50
0.51	0.204	49
0.52	0.212	47
0.53	0.221	45
0.54	0.229	44
0.55	0.238	42
0.56	0.246	41
0.57	0.255	39
0.58	0.264	38
0.59	0.273	37
0.60	0.283	35
0.61	0.292	34
0.62	0.302	33
0.63	0.312	32
0.64	0.322	31
0.65	0.332	30
0.66	0.342	29
0.67	0.353	28
0.68	0.363	28
0.69	0.374	28



Ki-67 index is reported as percent positive tumor cells in area of highest nuclear labeling (“hot spot”), although the precise method of assessment has not been standardized. A number of methods have used to assess Ki-67 index, including automatic counting and “eyeballing”.<sup>13,14</sup> Automated counting is not widely available and requires careful modification of the software to circumvent the inaccuracies.<sup>13</sup> Eye-balling can be used for most tumors; however, for tumors with Ki-67 index close to grade cut-offs, it is recommended to perform the manual count on the print of camera-captured image of the hot spot. It has been recommended that a minimum of 500 tumor cells be counted to determine the Ki-67 index, and a notation is made if less cells are available. Grade assigned based on Ki-67 index is typically higher than that based on mitotic count, and the case is assigned to the higher of the 2 if both methods are performed.<sup>11</sup>

It is important to note that there are a small group of well-differentiated neuroendocrine tumors with a Ki-67 index >20% and a mitotic rate usually <20 per 10 HPF. In WHO-2010, these tumors were considered as G3 poorly differentiated neuroendocrine carcinomas. However, they have typical morphology of well-differentiated tumors. Previous studies (most on pancreatic neuroendocrine tumors) have demonstrated that these tumors have a worse prognosis than grade 2 (Ki-67=3-20 % and mitosis <20/10 HPF) neuroendocrine tumors, but they are not as aggressive as poorly differentiated neuroendocrine carcinomas.<sup>15</sup> In addition, these tumors do not have the genetic abnormalities seen in poorly differentiated neuroendocrine carcinomas.<sup>16</sup> Furthermore, unlike poorly differentiated neuroendocrine carcinomas, they are less responsive to platinum-based chemotherapy.<sup>17</sup> In the WHO-2017 blue book of endocrine tumors and AJCC 8<sup>th</sup> edition, those with typical morphology of well-differentiated tumors are classified as “well-differentiated neuroendocrine tumor” but as grade 3. Here, the updated classification for “endocrine” tumors is adapted, and following grading scheme is recommended to grade well-differentiated gastroenteropancreatic neuroendocrine tumors (Table 2).

**Table 2**

**Recommended Grading System for Well-Differentiated Gastroenteropancreatic Neuroendocrine Tumors**

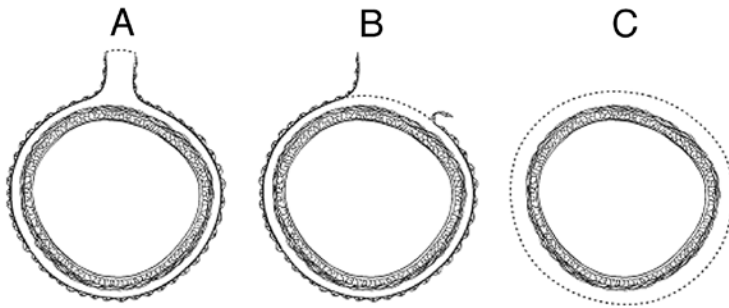
Grade	Mitotic Rate (per 2mm <sup>2</sup> )	Ki-67 index (%)
Well-differentiated neuroendocrine tumor, G1	<2	<3
Well-differentiated neuroendocrine tumor, G2	2-20	3-20
Well-differentiated neuroendocrine tumor, G3	>20	>20

### E. Margins

Margins in a simple appendectomy specimen include the proximal and circumferential (radial) margin. It is recommended that the proximal margin on a simple appendectomy specimen should be taken en face in order to evaluate the entire appendiceal mucosa and muscularis circumferentially. In the vast majority of cases, the appendix is entirely peritonealized (Figure, A), and the closest distance between the tumor and the mesoappendiceal resection margin represents the radial margin and should be measured. Even retrocecal appendices are usually invested by peritoneum but have adhered to the posterior cecum, either because of inflammation or tumor. Exceptionally, a retrocecal appendix may be retroperitoneal, in which case the distance between the tumor and the nonperitonealized radial resection margin is the “surgical clearance” and should be measured.

In general, the circumferential (radial) margin must be assessed for any segment of gastrointestinal tract either incompletely encased or unencased by peritoneum (Figure, B and C). The posterior surface of the ascending colon portion of a right hemicolectomy specimen lacks a peritoneal covering and thus constitutes a circumferential margin, which in rare cases may be relevant in right hemicolectomy specimens resected for treatment of appendiceal neuroendocrine tumors. The circumferential (radial) margin represents the adventitial soft tissue margin closest to the deepest penetration of tumor and is created surgically by blunt or sharp dissection of the retroperitoneal or subperitoneal aspect, respectively. The distance between the tumor and circumferential (radial) margin should be reported, if applicable. The circumferential (radial) margin is considered positive if the tumor is present at the inked nonperitonealized surface. This assessment includes tumor within a lymph node as well as direct tumor extension, but if circumferential (radial) margin positivity is based solely on intranodal tumor, this should be so stated.

The mesenteric resection margin is the only relevant circumferential margin in segments completely encased by peritoneum (eg, cecum; mesoappendiceal resection margin for the appendix) (Figure, A). Involvement of this margin should be reported even if tumor does not penetrate the serosal surface.



A, Mesenteric margin in viscus completely encased by peritoneum (dotted line). B, Circumferential (radial) margin (dotted line) in viscus incompletely encased by peritoneum. C, Circumferential (radial) margin (dotted line) in viscus completely unencased by peritoneum.

#### F. Pathologic Stage Classification

The TNM staging system for appendiceal NETs of the American Joint Committee on Cancer (AJCC) and the International Union Against Cancer (UICC) is recommended.<sup>4</sup>

#### pTNM Pathologic Classification

The pT, pN, and pM categories correspond to the T, N, and M categories except that pM0 (no distant metastasis) does not exist as a category.

By AJCC/UICC convention, the designation “T” refers to a primary tumor that has not been previously treated. The symbol “p” refers to the pathologic classification of the TNM, as opposed to the clinical classification, and is based on gross and microscopic examination. pT entails a resection of the primary tumor or biopsy adequate to evaluate the highest pT category, pN entails removal of nodes adequate to validate lymph node metastasis, and pM implies microscopic examination of distant lesions. Clinical classification (cTNM) is usually carried out by the referring physician before treatment during initial evaluation of the patient or when pathologic classification is not possible.

Pathologic staging is usually performed after surgical resection of the primary tumor. Pathologic staging depends on pathologic documentation of the anatomic extent of disease, whether or not the primary tumor has been completely removed. If a biopsied tumor is not resected for any reason (eg, when technically unfeasible) and if the highest T and N categories or the M1 category of the tumor can be confirmed microscopically, the criteria for pathologic classification and staging have been satisfied without total removal of the primary cancer.

#### TNM Descriptors

For identification of special cases of TNM or pTNM classifications, the “m” suffix and “y,” “r,” and “a” prefixes are used. Although they do not affect the stage grouping, they indicate cases needing separate analysis.

The “m” suffix indicates the presence of multiple primary tumors in a single site and is recorded in parentheses: pT(m)NM.

The “y” prefix indicates those cases in which classification is performed during or following initial multimodality therapy (ie, neoadjuvant chemotherapy, radiation therapy, or both chemotherapy and radiation therapy). The cTNM or pTNM category is identified by a “y” prefix. The ycTNM or ypTNM categorizes the extent of tumor actually present at the time of that examination. The “y” categorization is not an estimate of tumor prior to multimodality therapy (ie, before initiation of neoadjuvant therapy).

The “r” prefix indicates a recurrent tumor when staged after a documented disease-free interval, and is identified by the “r” prefix: rTNM.

The “a” prefix designates the stage determined at autopsy: aTNM.

### T Category Considerations

Tumor that is adherent to other organs or structures, macroscopically, is classified cT4. However, if no tumor is present in the adhesion and there is no serosal penetration microscopically, the classification should be pT1 to pT3.

### N Category Considerations

The regional lymph nodes for the appendix are the ileocolic lymph nodes. pN0. Histologic examination of a regional lymphadenectomy specimen will ordinarily include 12 or more lymph nodes. If the lymph node results are negative, but the number ordinarily examined is not met, classify as pN0.

### G. Additional Pathologic Findings

Coagulative tumor necrosis, usually punctate, may indicate more aggressive behavior<sup>18</sup> and should be reported. Appendiceal NETs are often an incidental finding in specimens removed for acute appendicitis.

### References

1. Kakar S, Shi C, Driman DK, et al. Protocol for the Examination of Specimens From Patients With Carcinoma of the Appendix. 2017. Available at [www.cap.org/cancerprotocols](http://www.cap.org/cancerprotocols).
2. Tang LH, Shia J, Soslow RA, et al. Pathologic classification and clinical behavior of the spectrum of goblet cell carcinoid tumors of the appendix. *Am J Surg Pathol*. 2008;32(10):1429-43.
3. Reid MD, Basturk O, Shaib WL, et al. Adenocarcinoma ex-goblet cell carcinoid (appendiceal-type crypt cell adenocarcinoma) is a morphologically distinct entity with highly aggressive behavior and frequent association with peritoneal/intra-abdominal dissemination: an analysis of 77 cases. *Mod Pathol*. 2016;29(10):1243-1253.
4. Amin MB, Edge SB, Greene FL, et al, eds. *AJCC Cancer Staging Manual*. 8th ed. New York, NY: Springer; 2017.
5. Carr NJ, Sobin LH. Neuroendocrine tumors of the appendix. *Semin Diagn Pathol*. 2004;21(2):108-119.
6. Syracuse DC, Perzin KH, Price JB, Wiedel PD, Mesa-Tejada R. Carcinoid tumors of the appendix: mesoappendiceal extension and nodal metastases. *Ann Surg*. 1979;190(1):58-63.
7. Rossi G, Valli R, Bertolini F, et al. Does mesoappendix infiltration predict a worse prognosis in incidental neuroendocrine tumors of the appendix?: a clinicopathologic and immunohistochemical study of 15 cases. *Am J Clin Pathol*. 2003;120(5):706-711.
8. Williams GT. Endocrine tumours of the gastrointestinal tract: selected topics. *Histopathology*. 2007;50(1):30-41.
9. Soga J. Carcinoids of the colon and ileocecal region: a statistical evaluation of 363 cases collected from the literature. *J Exp Clin Cancer Res*. 1998;17(2):139-148.
10. Iwafuchi M, Watanabe H, Ajioka Y, Shimoda T, Iwashita A, Seiki I. Immunohistochemical and ultrastructural studies of twelve argentaffin and six argyrophil carcinoids of the appendix vermiformis. *Hum Pathol*. 1990;21(7):773-780.
11. Bosman FT, Carneiro F, Hruban RH, Theise ND, eds. *WHO Classification of Tumours of the Digestive System*. Geneva, Switzerland: WHO Press; 2010.
12. Rindi G, Kloppel G, Alhman H, et al; and all other Frascati Consensus Conference participants; European Neuroendocrine Tumor Society (ENETS). TNM staging of foregut (neuro)endocrine tumors: a consensus proposal including a grading system. *Virchows Arch*. 2006;449(4):395-401.
13. Tang LH, Gonen M, Hedvat C, Modlin I, Klimstra DS. Objective quantification of the Ki67 proliferative index in neuroendocrine tumors of gastroenteropancreatic system: a comparison of digital image analysis with manual methods. *Am J Surg Pathol*. 2012;36(12):1761-1770.
14. Reid MD, Bagci P, Ohike N, et al. Calculation of the Ki67 index in pancreatic neuroendocrine tumors: a comparative analysis of four counting methodologies. *Mod Pathol*. 2016;29(1):93.
15. Shi C, Klimstra DS. Pancreatic neuroendocrine tumors: pathologic and molecular characteristics. *Semin Diagn Pathol*. 2014;31(6):498-511.
16. Yachida S, Vakiani E, White CM, Zhong Y, Saunders T, Morgan R et al. Small cell and large cell neuroendocrine carcinomas of the pancreas are genetically similar and distinct from well-differentiated pancreatic neuroendocrine tumors. *Am J Surg Pathol*. 2012;36(2):173-184.

17. Sorbye H, Strosberg J, Baudin E, Klimstra DS, Yao JC. Gastroenteropancreatic high-grade neuroendocrine carcinoma. *Cancer*. 2014;120(18):2814-2823.
18. Rindi G, Kloppel G, Couvelard A, et al. TNM staging of midgut and hindgut (neuro) endocrine tumors: a consensus proposal including a grading system. *Virchows Arch*. 2007;451(4):757-762.