



COLLEGE of AMERICAN
PATHOLOGISTS



Lower Anogenital Squamous Terminology Standardization of HPV- associated Neoplasia

Teresa M. Darragh, MD
*University of California, San Francisco
Steering Committee, ASCCP Co-Chair*

David C. Wilbur, MD
*Harvard Medical School,
Massachusetts General Hospital
Steering Committee, CAP Co-Chair*

Objectives

- **Understand the new and revised terminologies for the HPV- associated lesions of all lower anogenital tract body sites (cervix, vulva, vagina, penis, scrotum, anal canal and perianus)**
- **Understand how select biomarkers are used to improve accuracy and reproducibility of diagnosis in the revised terminology**
- **Understand the appropriate use for select molecular markers for HPV-related lesions of the lower anogenital tract body sites**

Focus: words...

Terminology /ter·mi·nol·o·gy/ (ter"mĭ-nol´ah-je)

- 1. the vocabulary of an art or science.**
- 2. the science which deals with the investigation, arrangement, and construction of terms.**

Medicine = Art + Science

Nomenclature (nō´menklā´chur):

- the formally adopted terminology of a science, art, or discipline;**
- the system of names or terms used in a particular branch of science.**

The Bethesda System: A Historical Perspective

Terminology : 3 fundamental principles

1. **Communicate clinically relevant information from the laboratory to the patient's health care provider.**
2. **Uniform and reasonably reproducible across different pathologists and laboratories and also flexible enough to be adapted in a wide variety of lab settings and geographic locations**
3. **Reflect the most current understanding of the disease process**

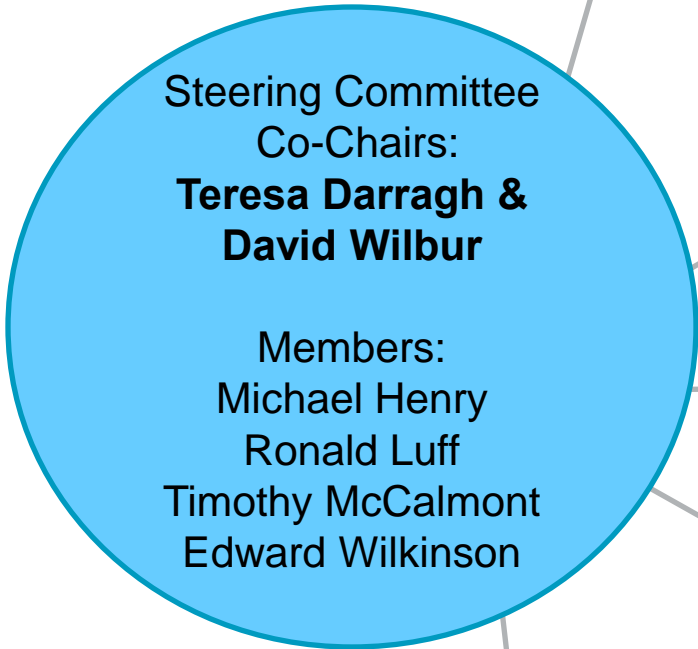
LAST Work Groups

- **WG 1 – Historical Review of Lower Anogenital Tract Terminology Across Disciplines**
- **WG2 – Terminology for Intraepithelial Lesions, Integrating Morphology, Biology, and Clinical Management**
- **WG3 - Terminology for Minimally Invasive Cancers, Integrating Morphology, Biology, and Clinical Management**
- **WG4 – Molecular Markers for Histopathology**
- **WG5 – Implications and Implementation of Standardized Terminology**

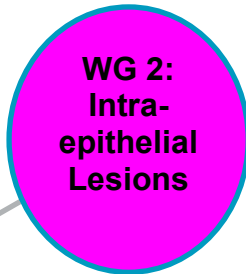Project Overview

44 Members and 13 advisors: Multidisciplinary panel of experts and thought leaders in the field, including...

- **Expertise in pathology specialties, eg**
 - **Cytopathology**
 - **Dermatopathology**
 - **Gynecologic pathology**
 - **Surgical pathology**
- **Expertise in clinical specialties, eg**
 - **Dermatology**
 - **Gynecology & Gynecologic Oncology**
 - **Internal Medicine, Infectious Diseases & Medical Oncology**
 - **Surgery**
 - **Epidemiology & Public Health**



J. Thomas Cox
Edward Wilkinson
Dennis O'Connor
R. Kevin Reynolds
Angelica Selim
James Scurry**

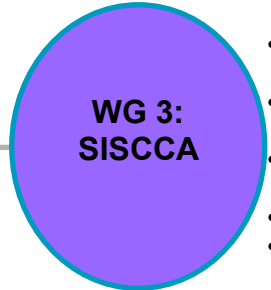


- Cervix/Vagina
- Vulva/Penis
- Anal/Perianal
- Advisor
- Jennifer Roberts**

Michael Henry
David Chelmow
Lydia Howell
Brigitte Ronnett
Alan Waxman

Timothy McCalmont
Hope Haefner
Kieron Leslie
Christopher Shea
Paul Staats

Joel Palefsky
Leona Council
Alice Lytwyn
Barbara Winkler

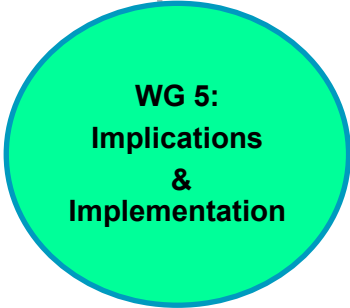


- Cervix/Vagina
- Vulva/Penis
- Anal/Perianal
- Advisor
- Christopher Otis*


Terence Colgan
Levi Downs
Rudy Laucirica
Richard Zaino

Debra Heller
Jill Allbritton
Olga Ioffe
Nancy Joste

Teresa Darragh
J. Michael Berry
Oscar Lin
Mark Welton



Ronald Luff
Ritu Nayar
Phil Castle
Maire Duggan
Ann Moriarty
G. Chip Niedt
Alicia Carter*
Francisco Garcia*
Marc Goodman*
Meg Neal*
Vijaya Reddy*
Stanley Robboy*
Mona Saraiya*
Steven Silverberg*
Susan Spires*



David Wilbur
Mark Stoler
Joel Bentz
Christina Kong
Bradley Quade
Mary Schwartz
Sarah Bean*

Methodologist*
Evan Myers



Bold- chair or co-chair
* Advisor
** International Advisor

Literature Review

WG2-4: Intraepithelial, Invasive and Molecular

- Reviewed:
 - 6,063 titles/abstracts
- Read
 - 1,210 Full text articles
- Completed
 - 452 data extractions
- Provided
 - 11 recommendations and 5 definitions for a proposed standardized terminology and appropriate use of biomarkers

Methods Used to Produce Recommendations

- **The LAST Consensus Conference was held March 13 -14, 2012 in San Francisco**
- **35 participating organizations sent representatives to review, discuss, and revise the recommendations.**
- **Each recommendation required a two-thirds majority (66% or higher) to pass**
- **Recommendations not achieving consensus on the first vote were revised by the WGs and submitted for a revote.**
- **All recommendations achieved the required majority votes.**
- **Observers in attendance did not vote.**

References: The LAST Project

The Lower Anogenital Squamous Terminology Standardization Project for HPV-Associated Lesions: Background and Consensus Recommendations from the College of American Pathologists and the American Society for Colposcopy and Cervical Pathology.

Darragh TM, Colgan TJ, Cox JT, Heller DS, Henry MR, Luff RD, McCalmont T, Nayar R, Palefsky JM, Stoler MH, Wilkinson EJ, Zaino RJ, Wilbur DC, for Members of the Last Project Work Groups.

- **Archives of Pathology and Laboratory Medicine:**
 - June 28, 2012. [Epub ahead of print]
 - October 2012 – Volume 135 – p 1266-1297.
- **Journal of Lower Genital Tract Disease:**
 - June 28, 2012. [Epub ahead of print]
 - July 2012 – Volume 16 – p 205-242

Central Tenets = Underlying Premises

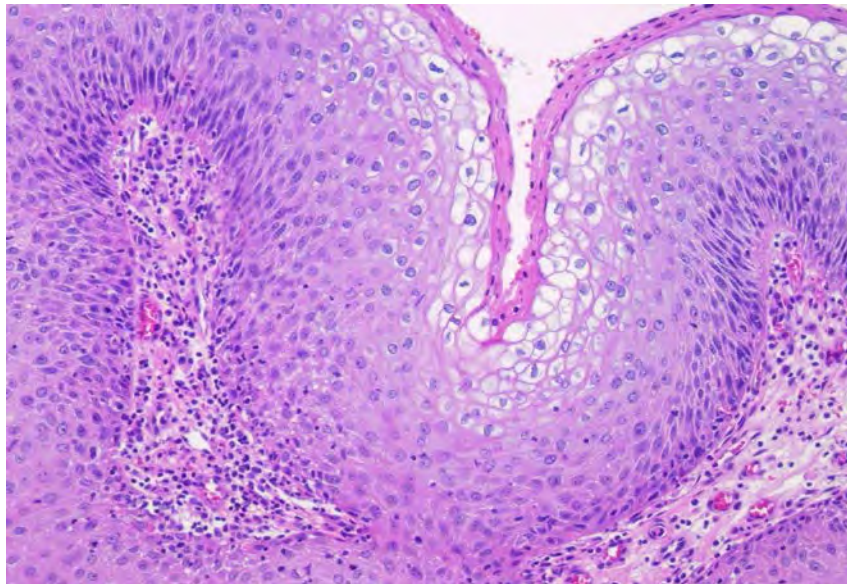
- There is unified epithelial biology to HPV-related squamous neoplasia.
- Each patient sample is only a statistical representation of the patient's true biology.
- The more samples or data points available, the closer you get to the patient's "true" biology.
- The true biology represents "risk" for "cancer" at the current time and to a lesser extent "risk" over time.
- -IN2 is like ASCUS: an indistinct poorly defined entity.
- Diagnostic variation can be improved by:
 - Limiting the number of tiers
 - The use of biologic markers

? False Premises

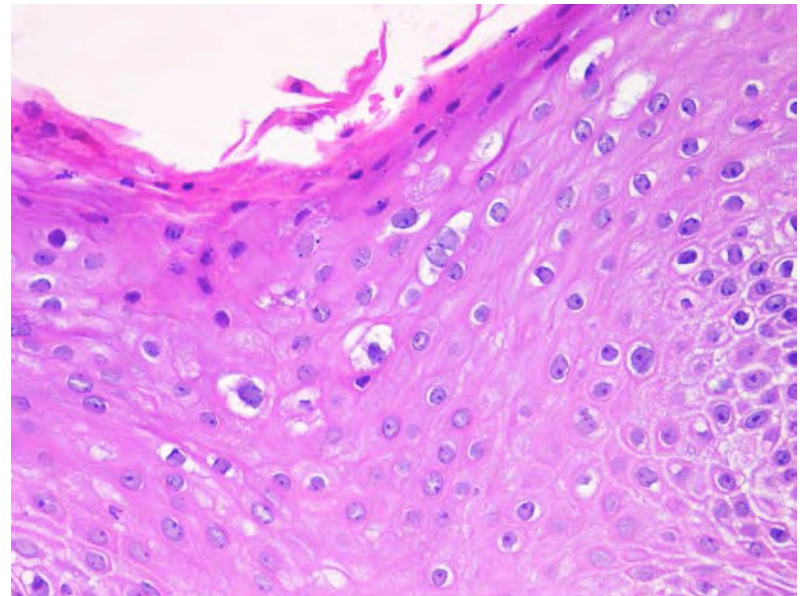
- **Biopsy is perfect representation and contains everything you need to know to manage the patient.**
- **Everybody reads the biopsy the same way.**
- **CIN2 is a distinct biologically defined category.**
- **Interpretative variation can be eliminated through education on morphologic criteria alone.**

There is a unified HPV-related biology: Which is Female vs. Male?

- **Male – Perianal Condyloma**

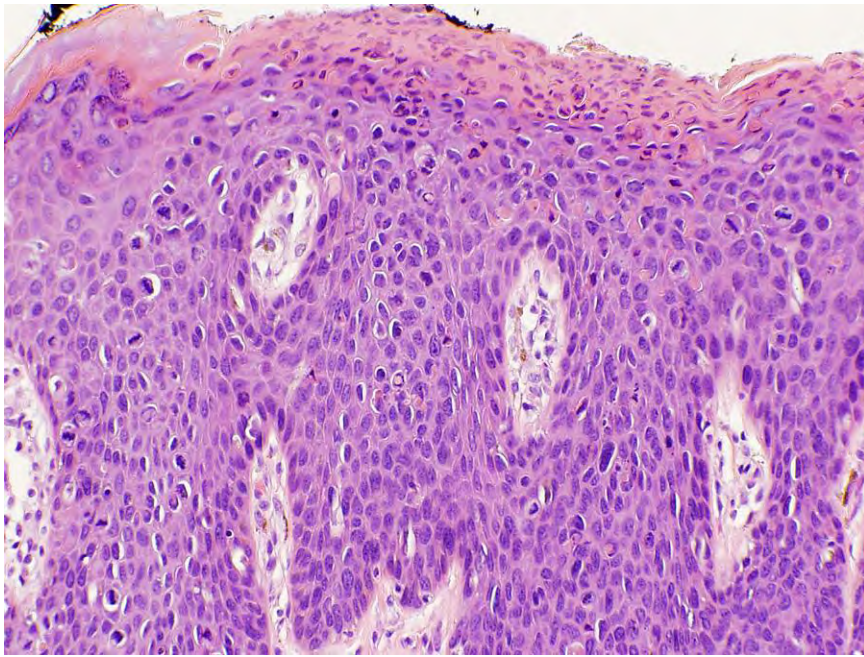


- **Cervix - Condyloma**

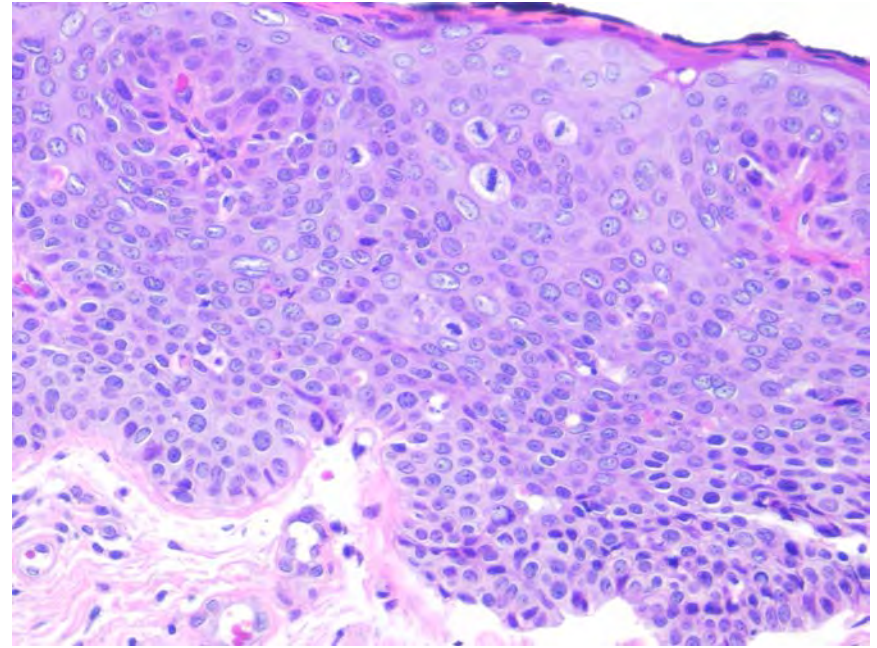


There is a unified HPV-related biology: Which is Female vs. Male?

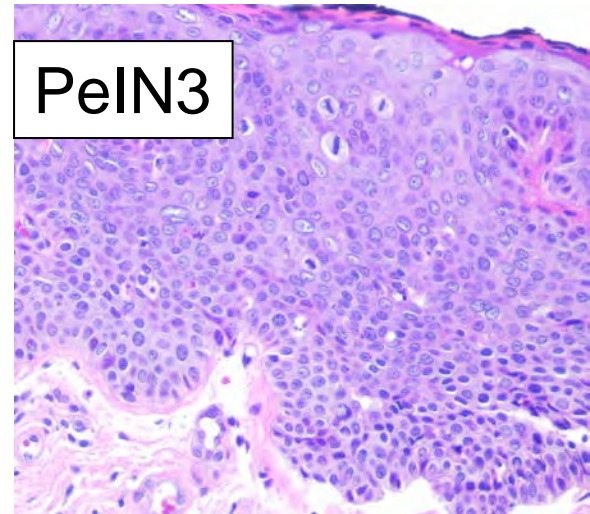
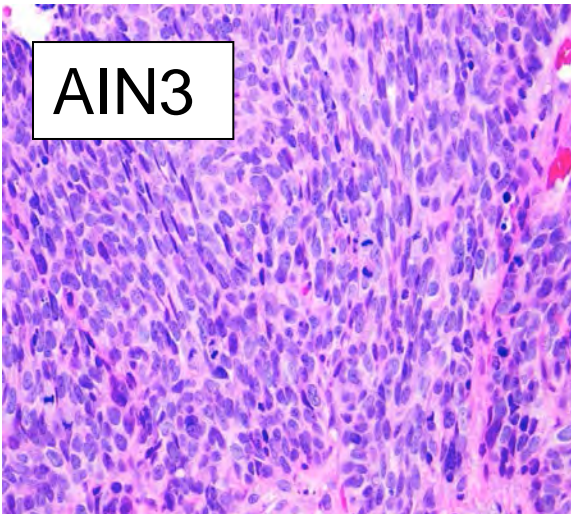
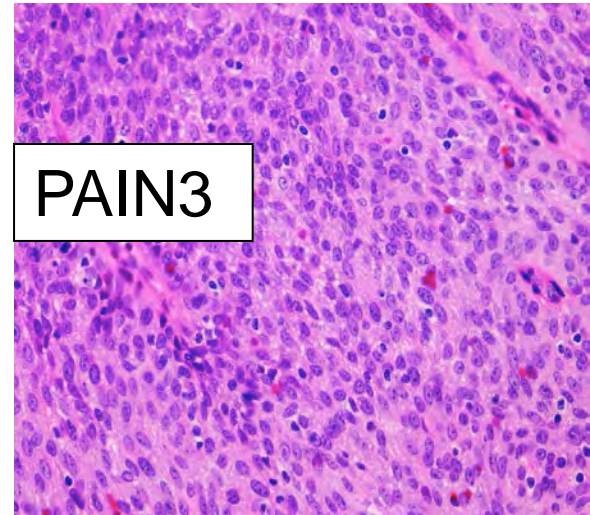
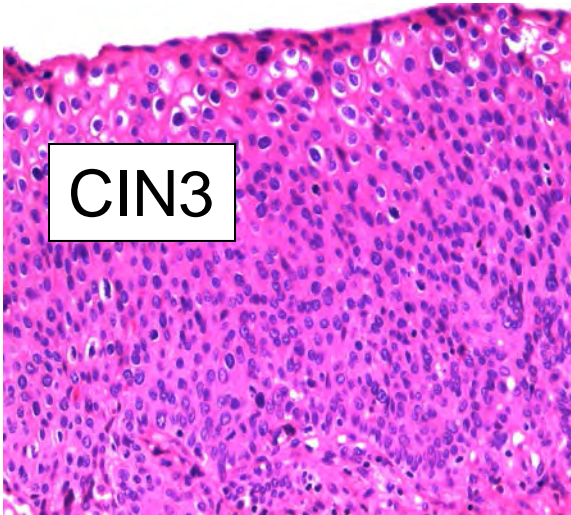
- **VIN3**

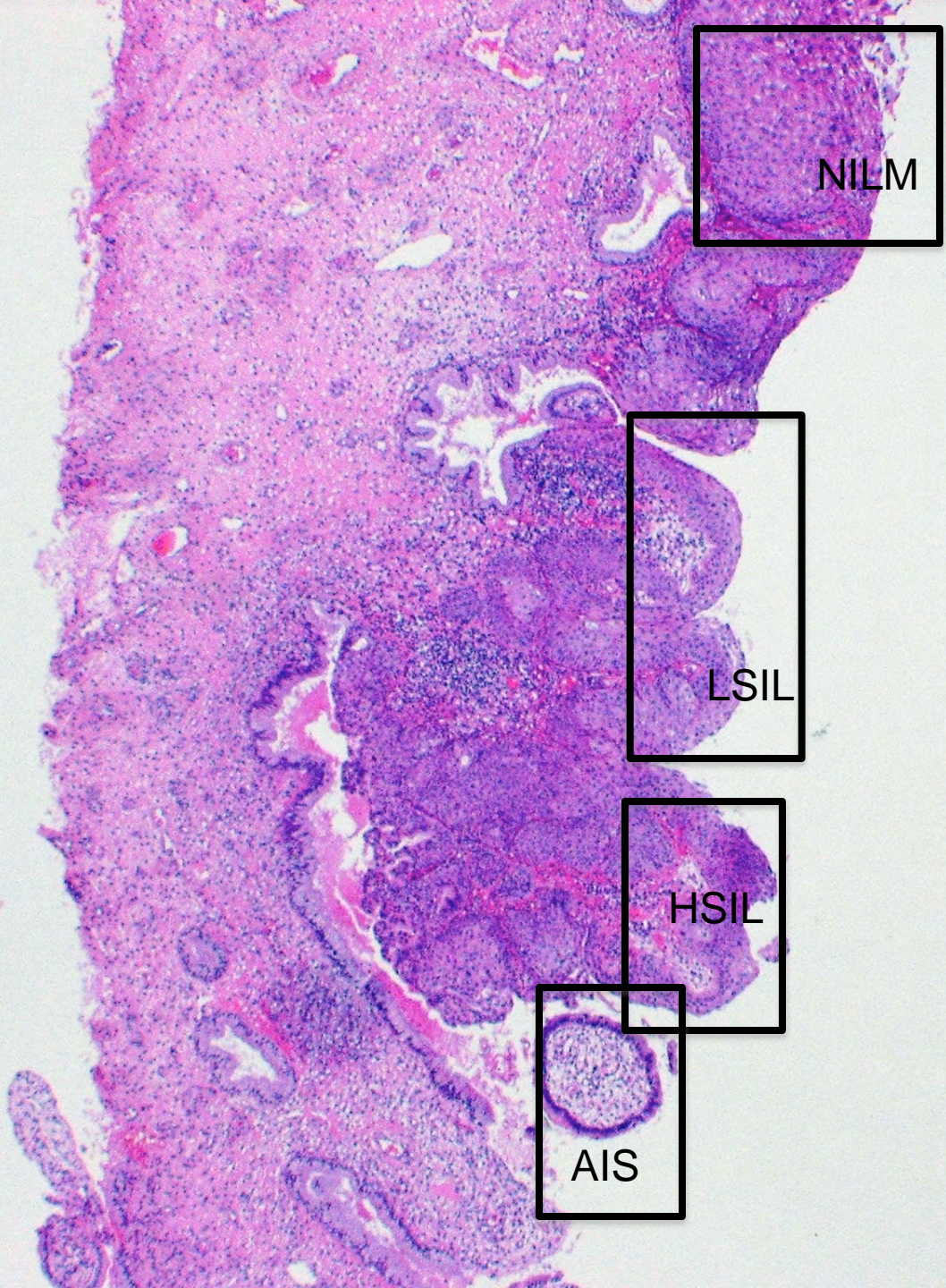


- **PeIN3**



High Grade or High Risk or Precancer





NILM

LSIL

HSIL

AIS



HPV NEG

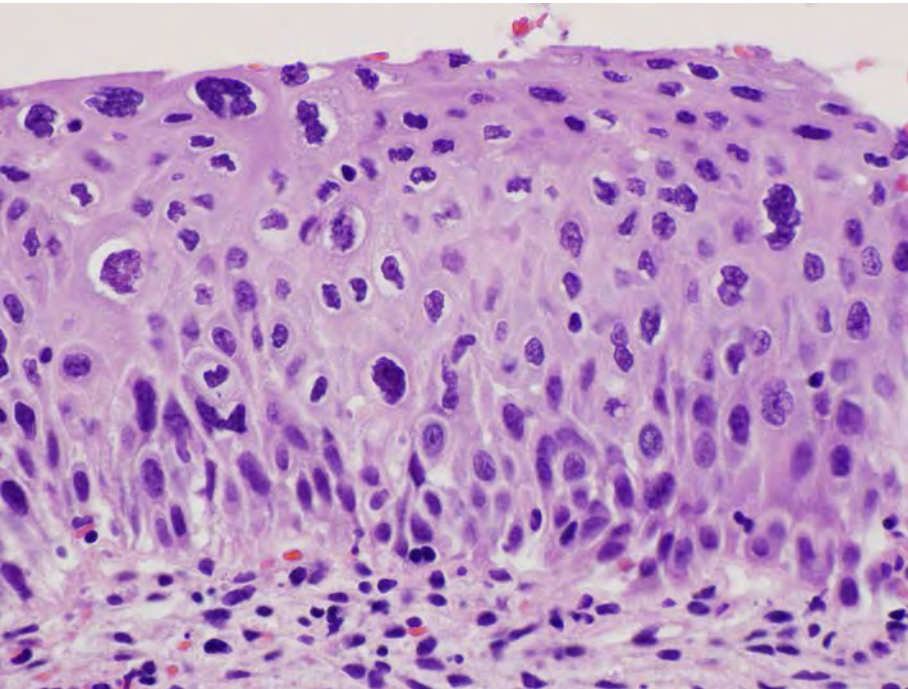
This histological section shows a cross-section of cervical tissue stained with hematoxylin and eosin (H&E). The tissue exhibits various layers, including the stratified squamous epithelium and underlying stroma. Four specific areas are highlighted with black boxes and labeled with their corresponding HPV test results. The labels are: HPV NEG (top right), HPV 6 (middle right), HPV16 (lower middle right), and HPV18 (bottom right). The HPV18 label is positioned over a glandular structure, likely an endocervical crypt.

HPV 6

HPV16

HPV18

Histology: '-IN2'



- **-IN2 is poorly reproducible**
- **In ALTS, clinical site vs study pathologists**
 - Only 46%, CIN2→CIN2
 - 27% upgraded to CIN3
 - 27% downgraded to CIN1 or normal

What is -IN2?

- **A DISTINCT BIOLOGIC STAGE?**
- **UGLY LOOKING CIN1?**
- **NOT SO UGLY CIN3?**

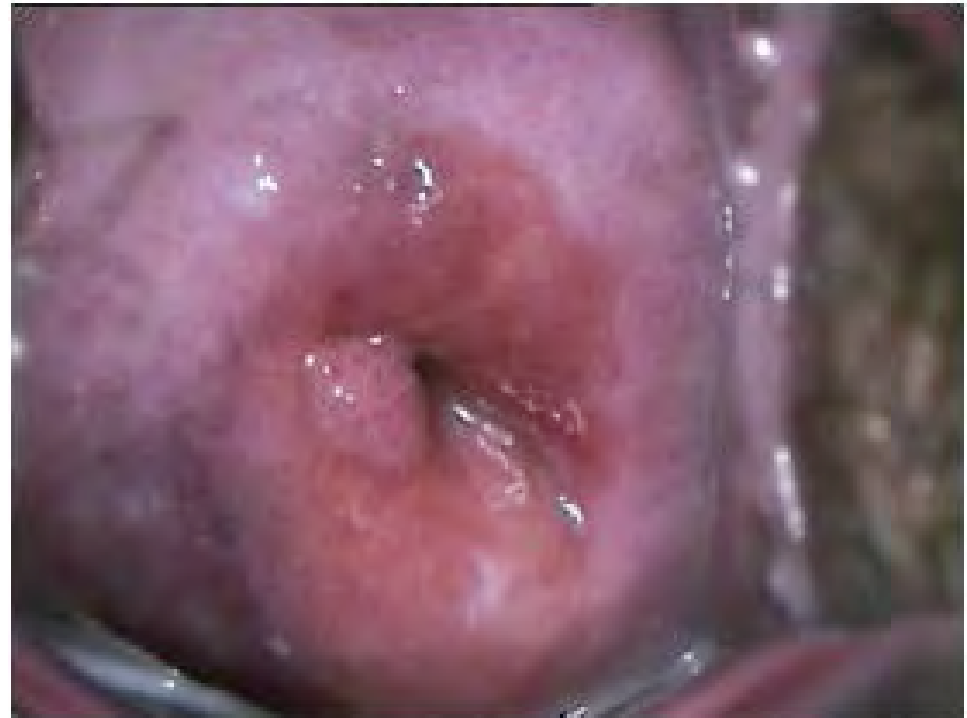-IN2 is ...

- **The ASCUS of CIN**
- **An equivocation that is NOT reproducible**
- **A representation of incomplete sampling**
- **~2/3s HSIL; ~1/3 LSIL**
- **A management safety net?**

COLPOSCOPIC VARIATION

- **Colposcopic Sampling**

- Location of T-zone
- Size of lesion
- Location of lesion
- Visual criteria
- Size forceps
- Skill



Accuracy of Colpo Biopsy?

- **OVERALL PERFECT AGREEMENT: 42%**
- **BX UNDERESTIMATES: 21%**
- **OVERESTIMATE or REMOVE: 36%**

- **Overall underestimation of CIN3+ = 42%**
- **Overall underestimation of CIN2+ = 26%**
- ***Biopsy is somewhat inaccurate and also potentially therapeutic***

H&E morphology: Interobserver Agreement

- **Benign Kappa 0.52**
- **CIN1 Kappa 0.24**
- **CIN2 Kappa 0.20**
- **CIN3+ Kappa 0.61**

Kappa values:

Strength of agreement

- **< 0.20 Poor**
- **0.21 - 0.40 Fair**
- **0.41 - 0.60 Moderate**
- **0.61 - 0.80 Good**
- **0.81 - 1.00 Very good**

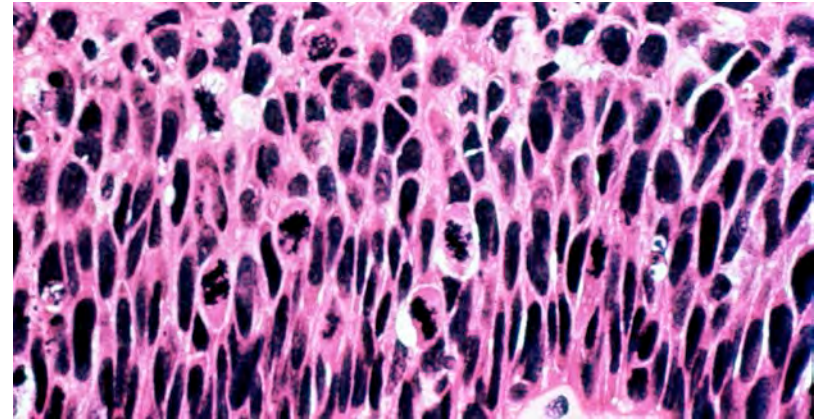
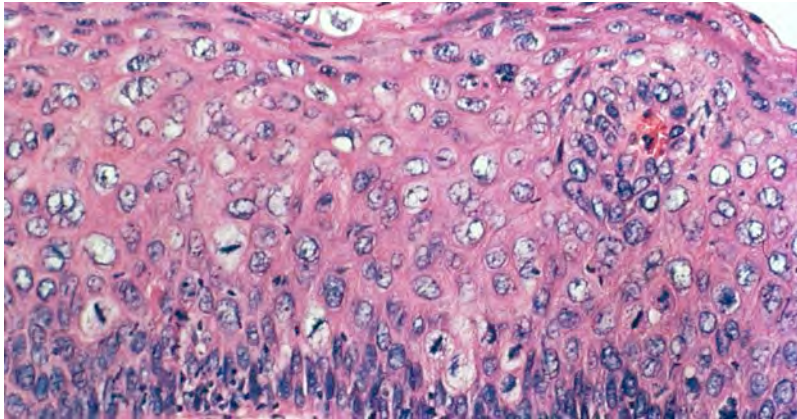
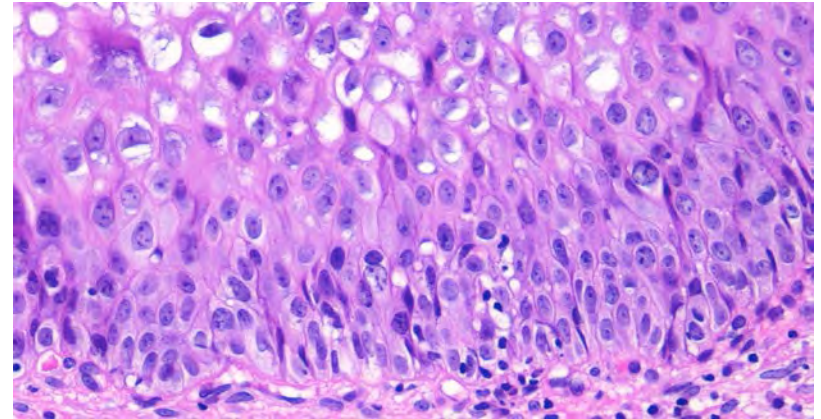
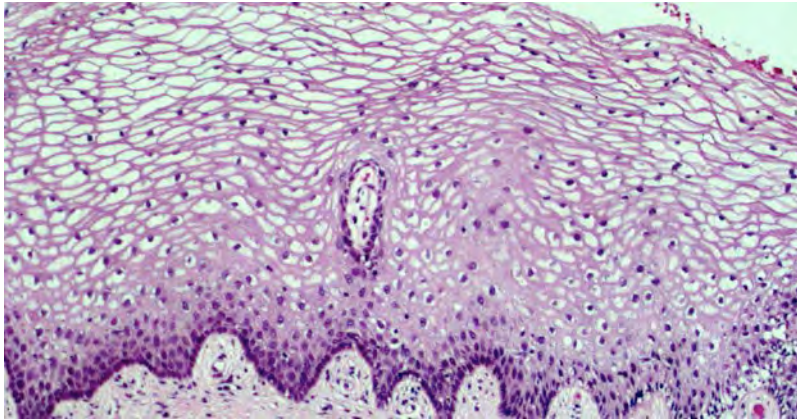


Observer variability in histopathological reporting of cervical biopsy specimens. J Clin Pathol 1989;42:231-8. Robertson AJ, Anderson JM, Beck JS, et al.

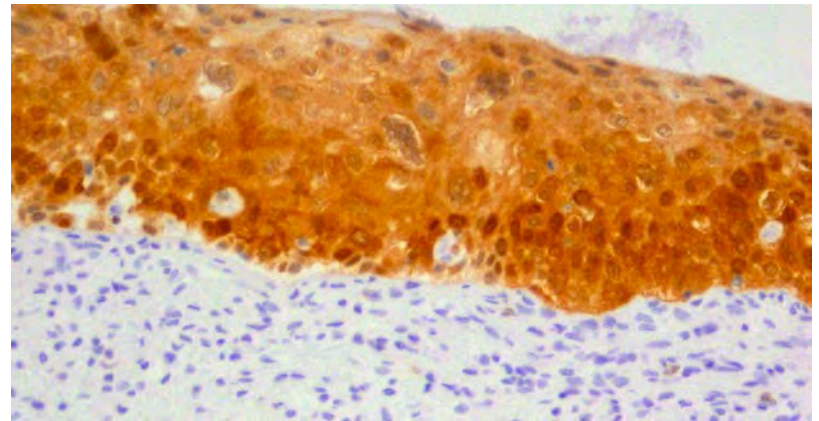
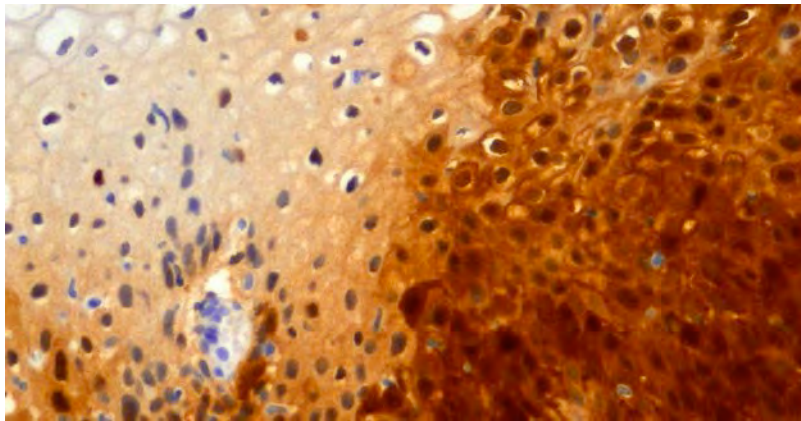
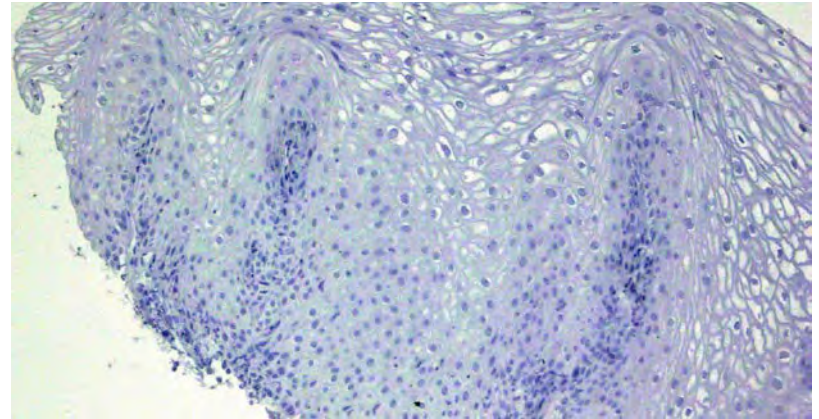
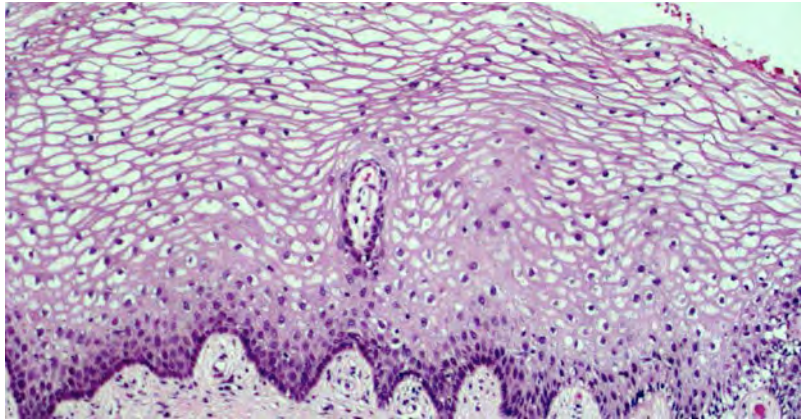
Hypotheses

- **Diagnostic variation can be improved by:**
 - **Limiting the number of tiers**
 - **The use of biologic markers, such as:**
 - **p16**
 - **Ki-67**
 - **ProEx C**

WHAT'S THE PROBLEM?



WHAT IF?



ARE BIOMARKERS THE SOLUTION?

DATA ON ~1500 ADJUDICATED BIOPSIES WITH 3+ p16 STAINING

- **NIL** **5%**
- **CIN1** **39%**
- **CIN2** **77%**
- **CIN3** **99%**



CAP

Galgano MT, Castle PE, Atkins KA, Brix WK, Nassau SR, Stoler MH. Using biomarkers as objective standards in the diagnosis of cervical biopsies. *Am J Surg Pathol* 2010;34:1077-87.

History – Terminology

Issues and controversies: Terminology

- **Varies historically over time**
- **Varies by clinical orientation**
 - **Dermatology / dermatopathology**
 - **Gynecology / gynecologic pathology**
 - **Surgery / surgical pathologists**
 - **Cytology**
- **Based on biology of disease...**
- **Leads to potential communication issues between pathologists and clinicians**

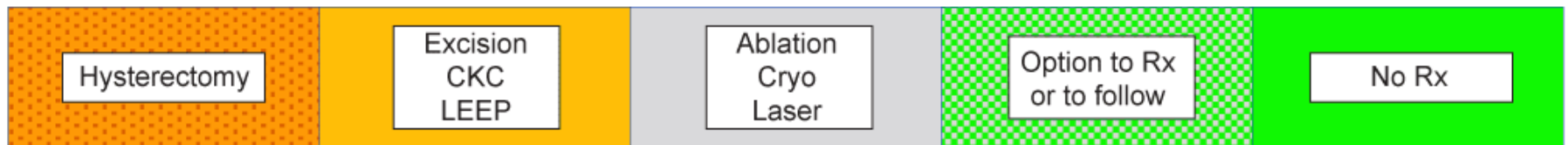
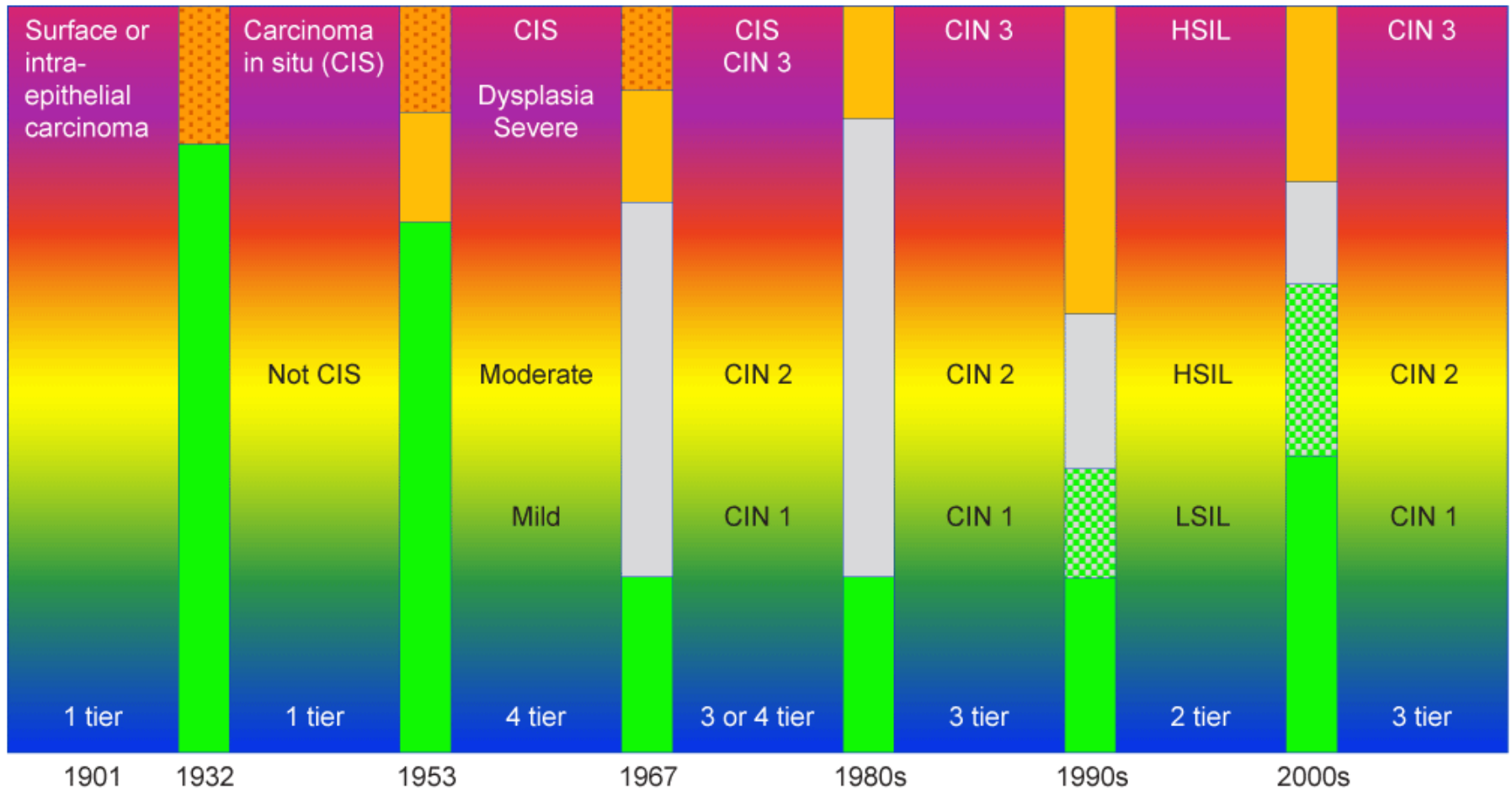
Terminologies of mucosal infection/precancer

- **Dysplasia**
 - mild, moderate, severe, carcinoma in situ
- **Intraepithelial neoplasia**
 - CIN1-3
 - VaIN1-3
 - AIN1-3
- **Squamous intraepithelial lesion**
 - LSIL / HSIL

Terminologies of cutaneous infection/precancer

- VIN1-3, PeIN1-3, PAIN1-3
- LSIL / HSIL
- VIN, usual type
- Carcinoma in situ
- Bowen's disease / Erythroplasia of Queyrat
- Bowenoid papulosis

Terminology



Procedure

WG1 Historical Review Summary

- A whole lotta terms over a whole lotta years...
- *The beginning of wisdom is getting things by their right name.*

Chinese saying

Squamous Intraepithelial Lesions

**WG2 – Terminology for Intraepithelial Lesions,
Integrating Morphology, Biology, and Clinical
Management**

WG2 Scope

- **To integrate current knowledge of HPV-related biology with histopathologic terminology across all lower anogenital body sites.**
- **To assess tiering of terminology and its impact on clinical utility.**
- **To optimize communication between pathologists and clinicians in clear and relevant fashion.**
- **To evaluate how the histopathologic diagnosis is reconciled with clinical management.**
- **To recommend new or unified terminology as appropriate.**

WG2 Intraepithelial Lesions Recommendations

- 1. A unified histopathological nomenclature with a single set of diagnostic terms is recommended for all HPV-associated preinvasive squamous lesions of the lower anogenital tract (LAT).**

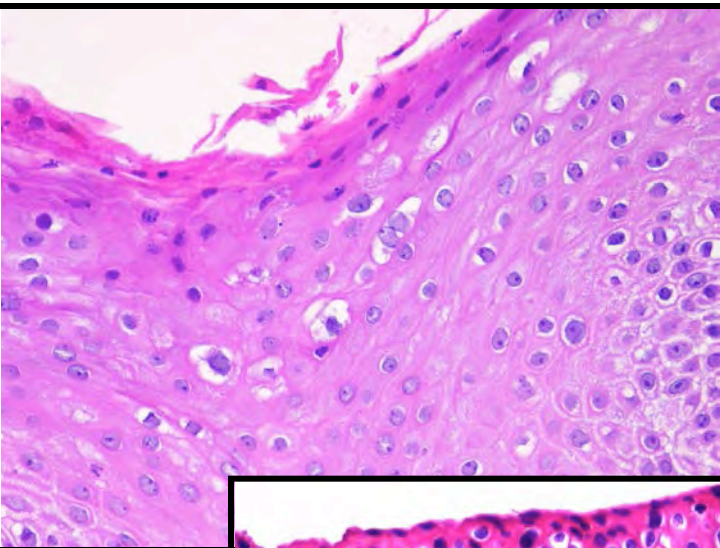
Recommendation #1: Rationale

- **From the literature review from WG2 and WG4, there is evidence of biologic and morphologic similarity of HPV-related squamous lesions across the lower anogenital tract.**
- **Non-HPV-related squamous lesions should have a separate distinctive nomenclature. i.e. differentiated VIN in the vulva.**

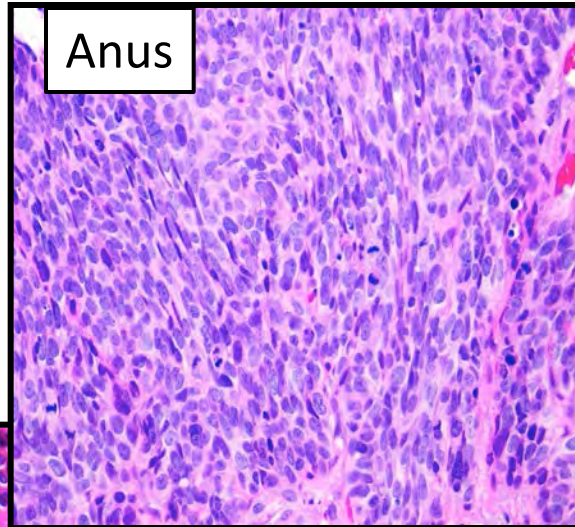
There is a unified HPV related biology:

Across body sites:

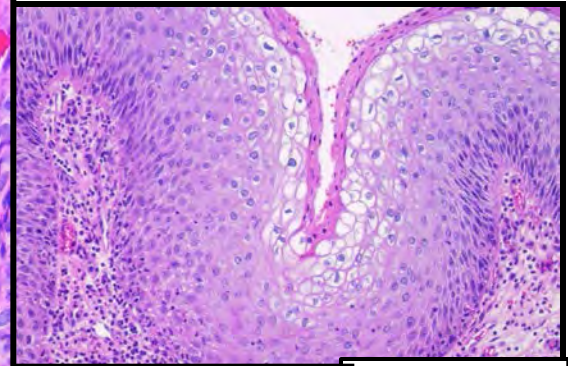
Mucosal and Cutaneous



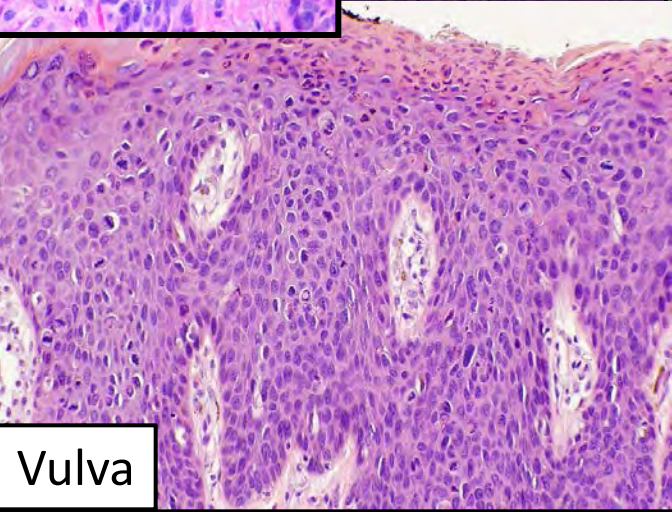
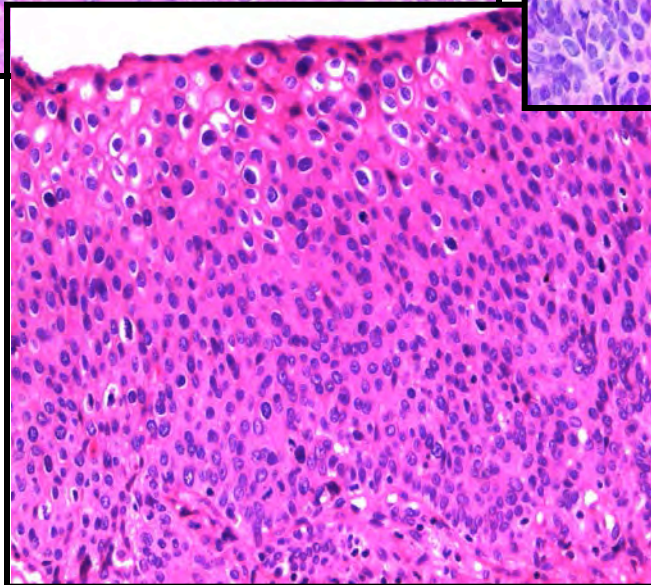
Cervix



Anus



Perianus



Vulva

WG2 Intraepithelial Lesions

Recommendations

- 2. A 2-tiered nomenclature is recommended for non-invasive HPV-associated squamous proliferations of the LAT which may be further qualified with the appropriate –IN terminology.**
 - -IN refers to the generic intraepithelial neoplasia terminology, without specifying the location. For a specific location, the appropriate complete term should be used. Thus for an –IN3 lesion: cervix = CIN3, vagina = VaIN3, vulva = VIN3, anus = AIN3, perianus = PAIN3, and penis = PeIN3**

Recommendation 2: Rationale

- **WG4 could find no molecular marker-based studies to support 3-tiered biology.**
- **WG4 found that the use of p16 to potentially upgrade or downgrade equivocal (CIN2) lesions effectively leads to a 2-tiered classification system.**

Recommendation 2: Rationale

There is evidence that a 2-tiered system for cervical disease is more reproducible (with higher kappa statistics).

- **For 2 tiers: Kappa statistics ranged from .30 to .71.**
 - **Studies are case series or cross sectional with low numbers other than one study from the ALTS trial which has high numbers and is a blinded study comparing 2 expert panel groups.**
- **For 3 tiers: Kappa statistics ranged from .12 to .58.**
 - **All studies are case series or cross sectional and have low numbers.**
 - **CIN2 has the lowest reproducibility of the 3 tiers.**

Recommendation 2: Rationale

- In reality, CIN2 represents a mixture of low-grade (risk) and high-grade lesions with borderline histopathologic features between classic CIN1 or condyloma and CIN3.
- Recent gynecologic pathology textbooks use a 2-tiered nomenclature for cervix/vagina lesions.
- The most recent ISSVD recommended terminology for vulvar HPV-related squamous lesions is essentially a 2-tiered system with the older term VIN1 relegated to condyloma.
- The public comments strongly supported this recommendation.
- Some pathology practices, academic and private, have used a 2-tiered system for many years

Recommendation 3: Diagnostic terminology for a 2-tiered system

Low Grade Squamous Intraepithelial Lesion (LSIL)

High Grade Squamous Intraepithelial Lesion (HSIL)

(These may be further classified by the applicable –IN subcategorization)

Rationale:

- Some current textbooks use this terminology
- Would match cytology nomenclature.
- This received the most support from the public comments
- **Concerns**
 - There were some public comments expressing concern that using identical terminology to cytology would not be appropriate and might be confusing.
 - Clinical guidelines will need to be adjusted to a 2-tiered system

Biomarkers

WG4 – Molecular Markers for Histopathology

WG 4 Issues

- **Assess the use of molecular markers in conjunction with morphology for HPV-related lesions**
- **Potential markers?**
- **Which are ready for primetime?**
- **How should they be used?**
- **Does marker use define any classification?**
- **Do markers affect interobserver variability?**
- **Single marker vs. combinations of markers?**
- **Does marker use affect clinical management?**

Comprehensive literature review

- **2291 relevant articles identified (1985-2012)**
- **Pre-specified criteria**
 - Study type
 - Scope
 - Number of subjects
- **Systematic title/abstract and full text review process**
- **72 articles for data extraction (53 for p16)**
- **Vast majority – cervix related**
- **Prospective and histology-adjudicated studies given most weight**

Quality of evidence review

- **Only WG with this review**
- **Independent evaluation of the evidence quality (18 articles)**
- **Conducted by Evan Myers, M.D., M.P.H.**
- **Use of terminology for qualification of the recommendations**
 - **“recommend”** – WG’s recommendation is unlikely to change based on future studies
 - **“suggest”** – WG’s recommendation is most likely correct but could be better supported by additional data

Key Question #1

- **What (if any) are the molecular markers and when should they be used?**
- **Utility on histologic specimens**
- **Aid to differential diagnosis**
- **Potentially definitional of the patient's biologic state**

Markers evaluated after 1st tier review

- **p16**
- **Ki67 (Mib1)**
- **ProEx C**
- **L1**
- **HPV 16/18 mRNA**
- **Telomerase (TERC)**
- **HPV genotyping**

Adaptability across lower anogenital tract

- **Most studies focus on cervix**
- **Few studies available for other sites**

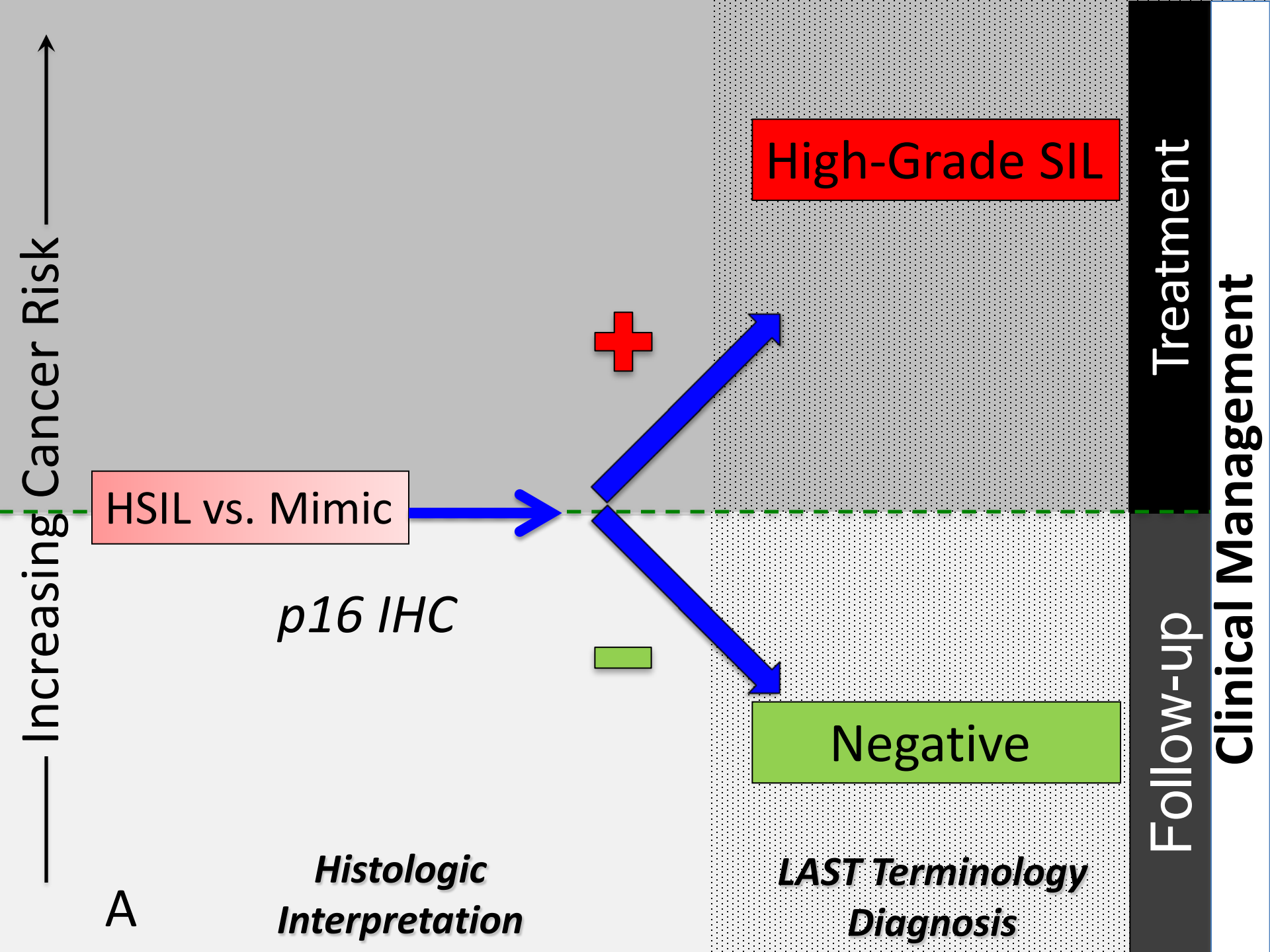
- **All studies for other sites show similar results to cervix.**
- **Given similarity of underlying HPV-associated biology:**
- **WG4 concludes that recommendations should apply across all HPV-associated lower anogenital tract lesions.**

Key Question #2

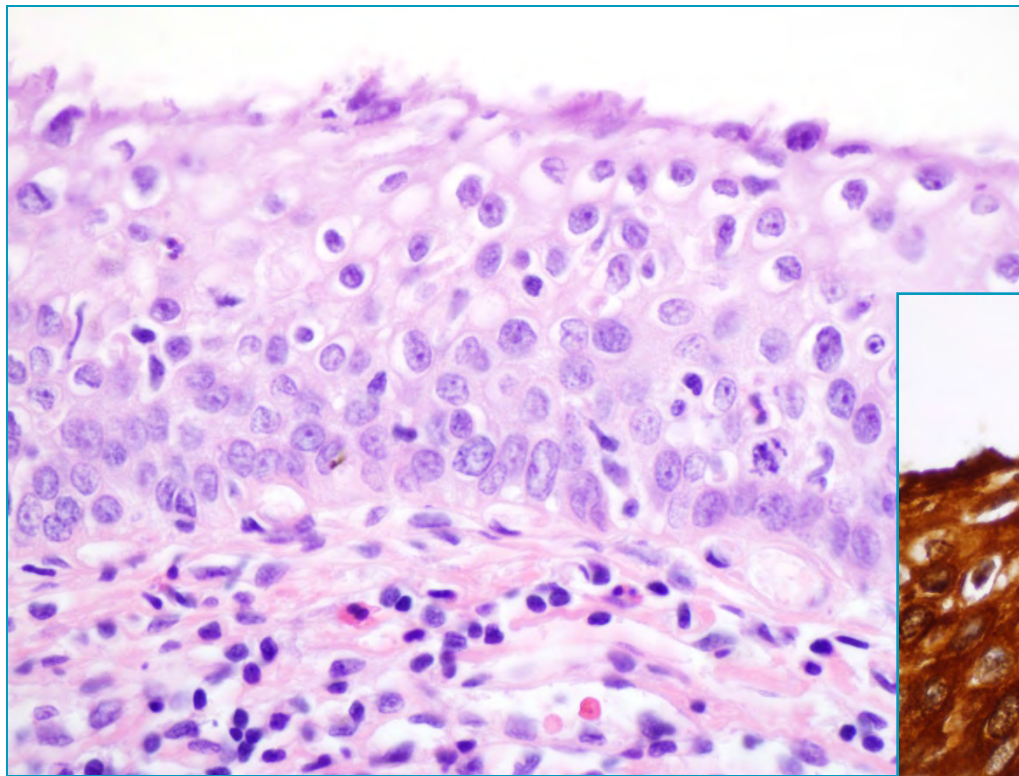
- **Is any biomarker ready for prime time use?**
- **It could be used commonly**
- **It is reliable**
- **Refines diagnostic issues**

WG4 Biomarkers Recommendations

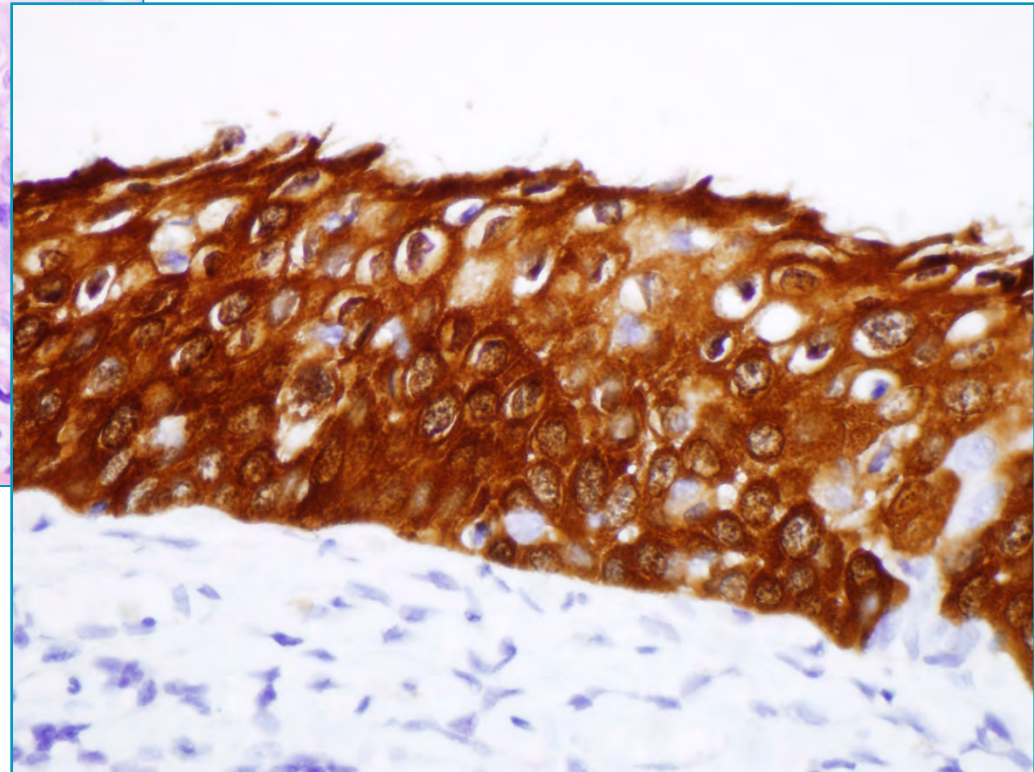
1. **p16 IHC is *recommended* when the H&E morphologic differential diagnosis is between precancer (–IN2 or –IN3) and a mimic of precancer (e.g., processes known to be not related to neoplastic risk such as immature squamous metaplasia, atrophy, reparative epithelial changes, tangential cutting).**
 - **Strong and diffuse block-positive p16 results support a categorization of precancerous disease.**

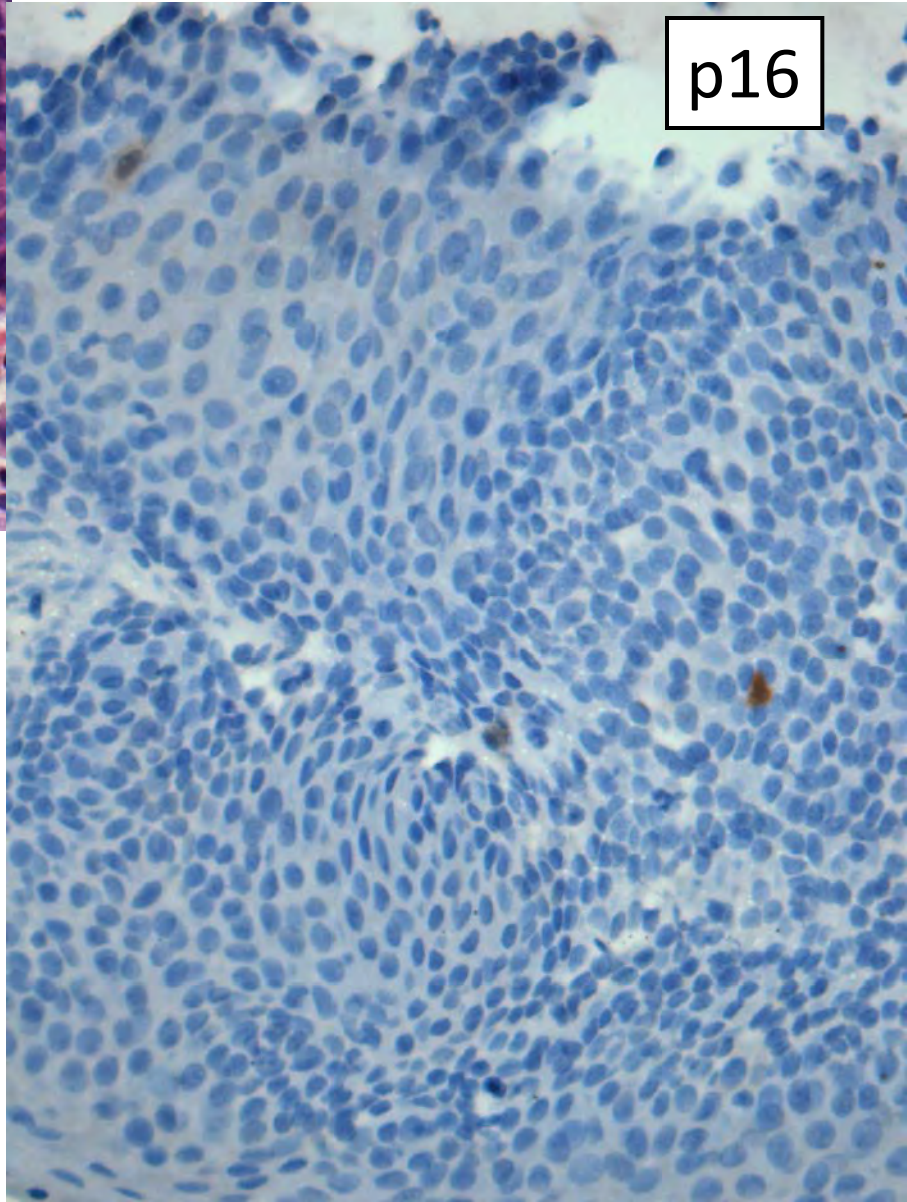
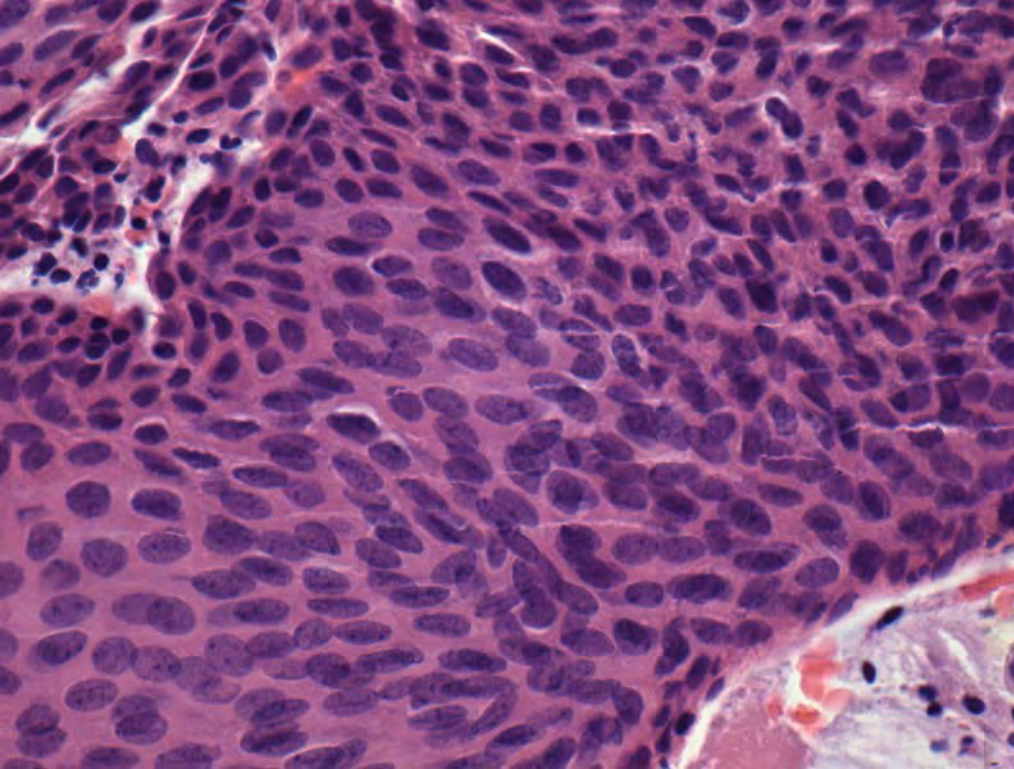


p16 positive lesions in all sites



p16 “block” positive

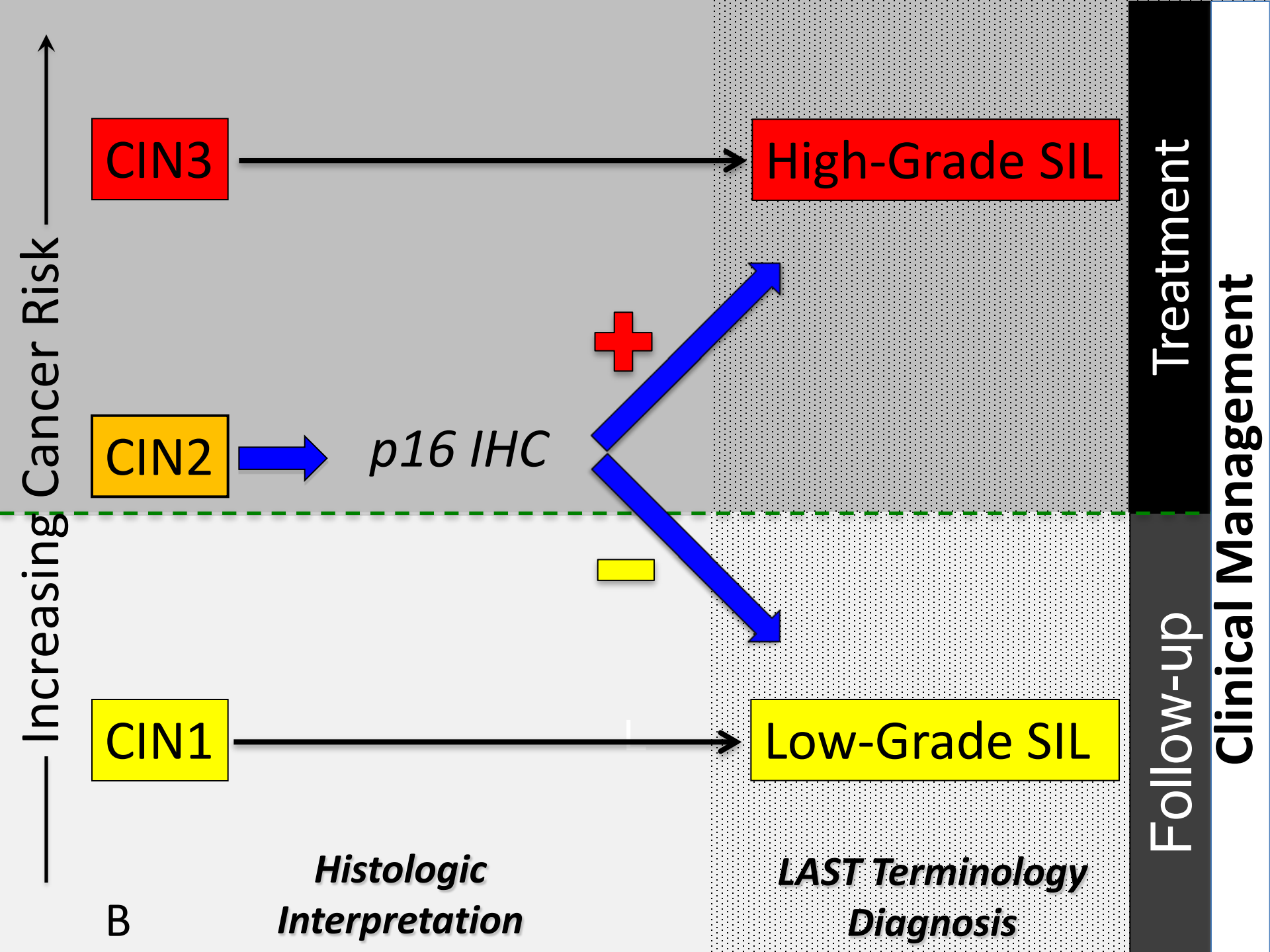


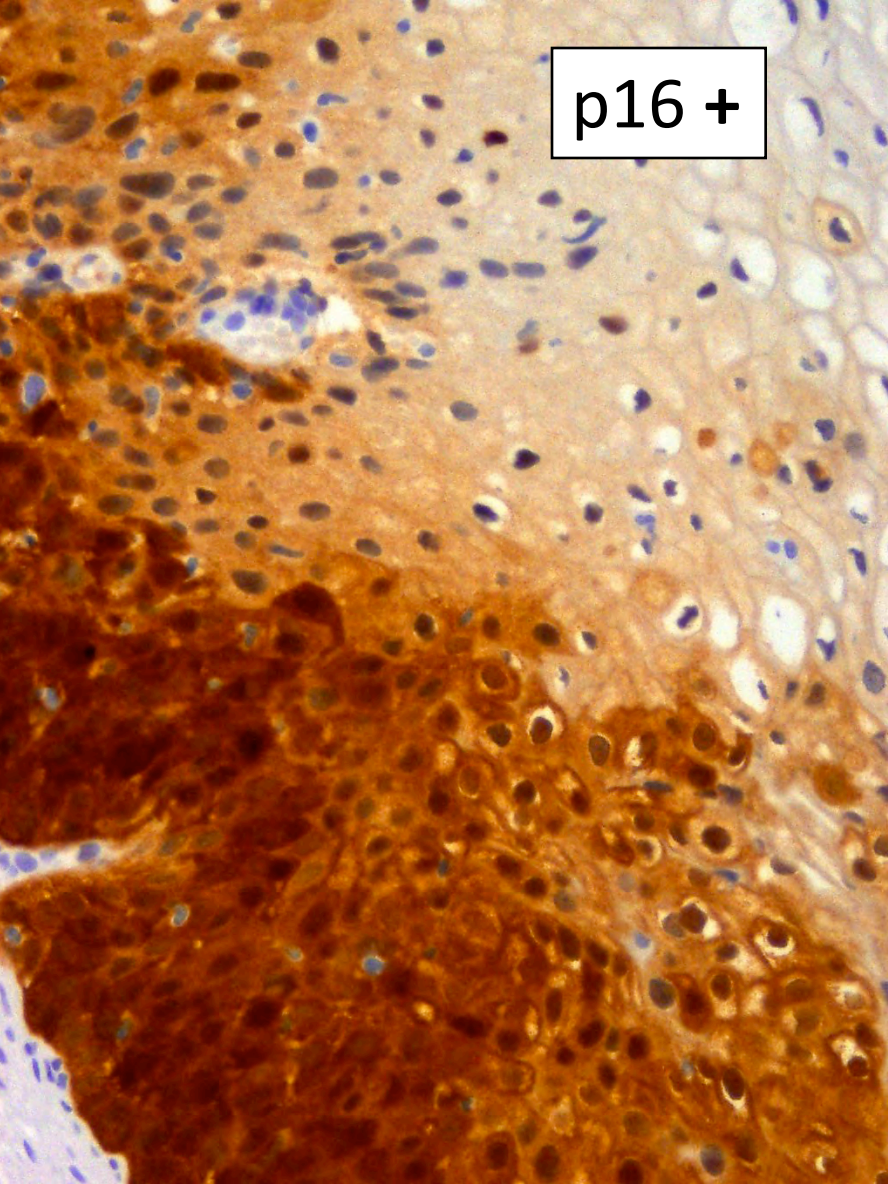
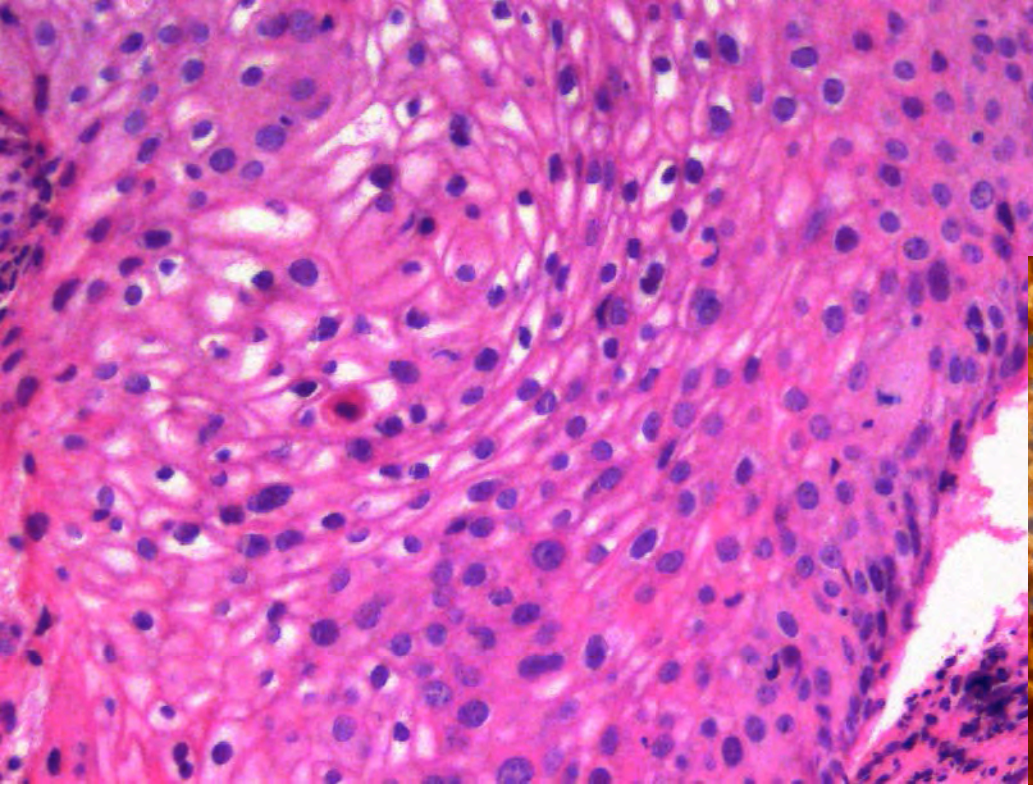


Transitional Cell Metaplasia

WG4 Biomarkers Recommendations

2. **If the pathologist is entertaining an H&E morphologic interpretation of –IN2 (under the old terminology, which is a biologically equivocal lesion falling between the morphologic changes of HPV infection [low-grade lesion] and precancer), p16 IHC is *recommended* to help clarify the situation.**
 - **Strong and diffuse block positive p16 results support a categorization of precancer. Negative or non-block-positive staining strongly favors an interpretation of low-grade disease or a non-HPV associated pathology.**





query CIN2

Recommendation #2 Notes

- p16 should not be used if the H&E morphologic differential diagnosis is between low grade disease (CIN1) and negative, as CIN1 can be either p16 negative or positive.
- If the pathologist's histologic diagnosis is “obvious” CIN1, the WG does not recommend further IHC.
 - There is insufficient evidence to determine whether there is a difference in the natural history between p16 positive and p16 negative CIN1. Hence at the present time, it is recommended that clinical management of CIN1 be based on the histologic diagnosis alone.

Rationale for recommendations #1 and #2

- In the largest prospective adjudicated study and other supporting studies, diffuse strong (block positive) staining with p16 showed similar accuracy for high grade disease when compared to an adjudicated histology standard.
- p16 IHC improves the accuracy of a single pathologist's interpretation of high grade vs. low grade disease relative to an adjudicated pathology panel.
- Addition of a p16 result leads to a more accurate prediction of the patient's risk for high grade disease.

Recommendations #1 & 2

- **Strength of Evidence – Dr. Myers**
- ***“The quality of the evidence for the test characteristics of H&E + p16 is moderate-high.”***
- ***“The quality of the evidence for improved consistency of readings with p16 is high.”***

WG4 Biomarkers Recommendations

3. p16 is recommended for use as an adjudication tool for cases in which there is a professional disagreement in histologic specimen interpretation, with the caveat that the differential diagnosis includes a precancerous lesion (—IN2 or —IN3).

Rationale for recommendation #3

- **A number of studies address interobserver variability in the interpretation of lower anogenital tract squamous lesions.**
- **These studies all show that there is substantial improvement in agreement between observers when p16 IHC is used.**
- **Therefore in association with recommendation #1, the addition of p16 provides a more objective adjudication of the differential diagnosis than does H&E histologic assessment alone.**

Recommendation #3

- **Strength of Evidence – Dr. Myers**
- **“The quality of the evidence is high.”**

WG4 Biomarkers Recommendations

4. **WG4 recommends against the use of p16 IHC as a routine adjunct to histologic assessment of biopsy specimens with morphologic interpretations of negative, –IN1, and –IN3.**

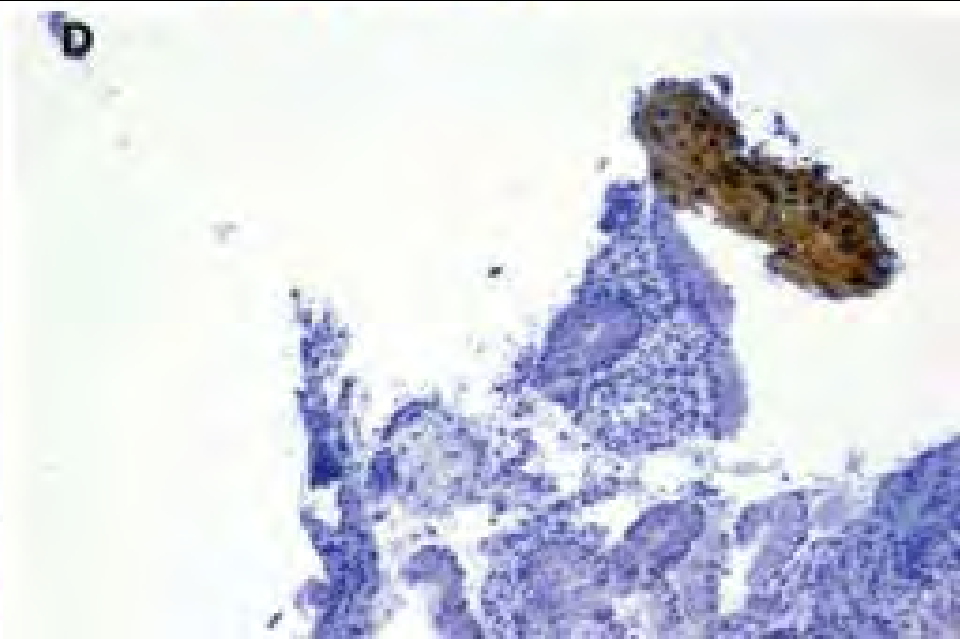

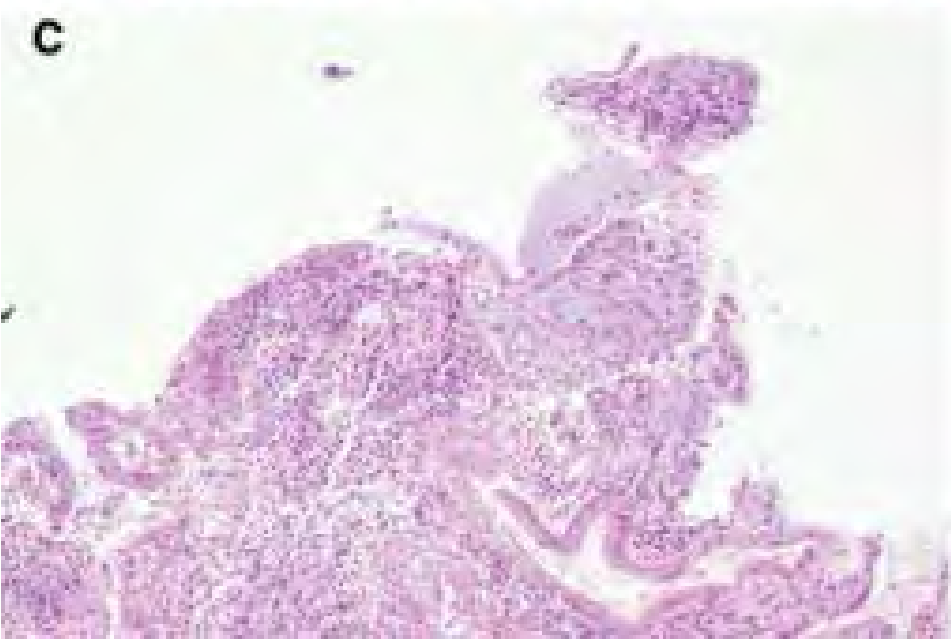
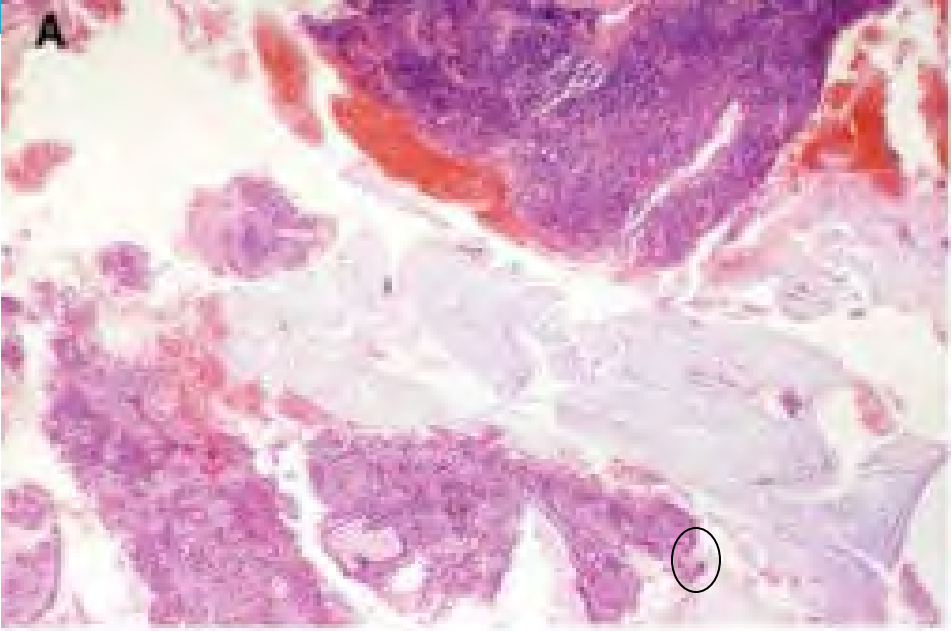
WG4 Biomarkers Recommendations

4. SPECIAL CIRCUMSTANCE

- a) p16 IHC is recommended as an adjunct to morphologic assessment for biopsy specimens interpreted as $\leq -IN1$ that are at high risk for missed high-grade disease, which is defined as a prior cytologic interpretation of HSIL, ASC-H, ASC-US/HPV16 +, or AGC (NOS).
 - Any identified p16 positive area must meet H&E morphologic criteria for a high-grade lesion to be reinterpreted as such.

Rationale for recommendation #4

- **Based on the high sensitivity of p16 for precancerous lesions, areas of small or equivocal high grade disease have been identified on histologic sections using p16, which were not readily identifiable on H&E sections alone.**
- **In a “high risk” situation, p16 block positive areas are most likely to represent precancerous disease.**



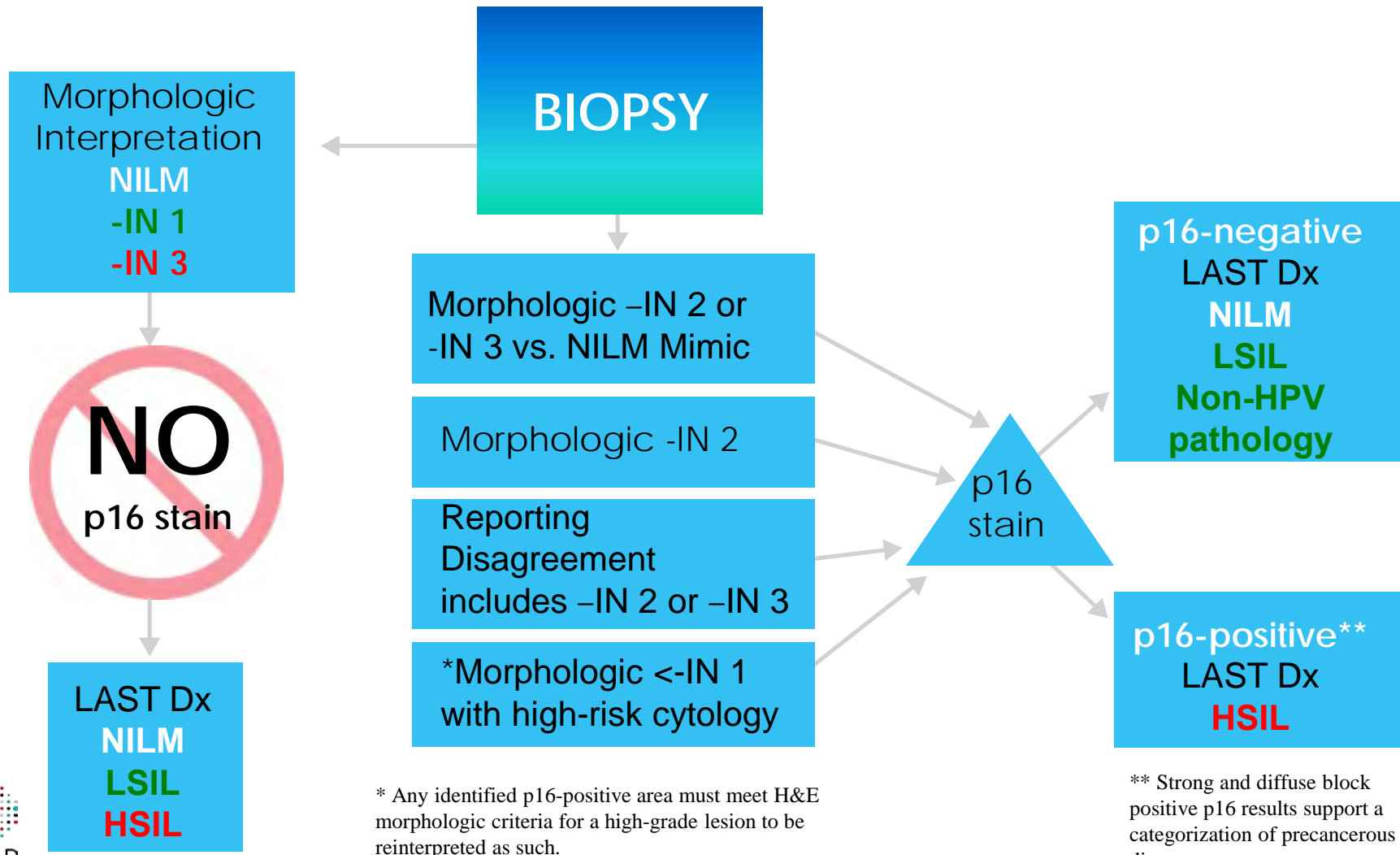
Recommendation #4

- **Strength of Evidence – Dr. Myers**
- **“....the quality of the evidence for superior sensitivity of H&E + p16 is high-moderate.”**

Biomarker Caveat

- **Ki67 and ProEx C show similar but less well-documented operating characteristics when compared to p16.**
- **If p16 is unavailable, technically inadequate, or equivocal;**
- **Ki67 and/or ProEx C may be considered for use.**

Summary of Algorithms for Management of Biopsy Results with LAST Terminology



WG 3: Superficially Invasive Squamous Cell Carcinoma

HPV-associated Cancers in US

| Site | Average annual no.* | % attributable to HPV† | | No. attributable to HPV§ | |
|------------|---------------------|------------------------|---------|--------------------------|-----------------|
| | | % | Range % | Number | |
| Cervix | 11,967 | 96 | (95–97) | 11,500 | (11,400–11,600) |
| Vulva | 3,136 | 51 | (37–65) | 1,600 | (1,200–2,000) |
| Vagina | 729 | 64 | (43–82) | 500 | (300–600) |
| Penis | 1,046 | 36 | (26–47) | 400 | (300–500) |
| Anus | | | | | |
| Female | 3,089 | 93 | (86–97) | 2,900 | (2,700–3,000) |
| Male | 1,678 | 93 | (86–97) | 1,600 | (1,400–1,600) |
| Oropharynx | | | | | |
| Female | 2,370 | 63 | (50–75) | 1,500 | (1,200–1,800) |
| Male | 9,356 | 63 | (50–75) | 5,900 | (4,700–7,000) |

18,500

WG 3: Issues and controversies

- 1. This literature review highlighted an inconsistent use of ‘microinvasive’ terminology**
 - Variety of definitions, per site and between sites
 - Systems use different defining parameters,
 - Outstanding methodological issues, (e.g. multi-focality, precision in measurement),
 - The use of some potential prognostic parameters (e.g. LVI) varies among systems and sites,
 - Lack of clarity in reporting margin involvement by invasive carcinoma or intra-epithelial neoplasia
- 2. No definition of SISCCA for anal canal/peri-anus**
- 3. Peri-anus staged as ‘skin’ cancer, not like vulvar cancer**

WG3: Issues and controversies

Central conclusion of literature review: Adopting a category of “superficially invasive squamous cell carcinoma” (SISCCA) based upon clinical outcome for these sites would have several potential benefits:

- **Clearly identify groups that would be amenable to conservative treatment, (eg, cervix),**
- **Permit comparison for management results of identical stage disease (eg, anal canal),**
- **Eliminate confusion in defining early invasive disease (eg, Cervix SGO microinvasive and FIGO)**

WG3: Issues and controversies

Couldn't we just report pathologic parameters and avoid an outcome based classification of “superficially invasive squamous cell carcinoma”?

NO!... The future of pathology is the development of the pathologist as “diagnostic specialist”* who ...

1. Integrates all relevant data,
2. Delivers definitive diagnostic consultations,
3. Reports using schemas based upon outcomes,
4. Provides meaningful reports for all types of health care professionals.

WG3 Superficially Invasive Squamous Cell Carcinoma

- 3 general recommendations for SISCCA
- 5 site specific definitions for SISCCA

(for sites where parameters have been shown to have prognostic significance)

- Mucosal

- Cervix
- Vaginal – no recommendation
- Anal Canal – suggested definition

- Cutaneous

- Vulva – no change to current definition
- Penis – no change to current definition
- Scrotum – no recommendation
- Perianus – suggested definition

WG3 Superficially Invasive Squamous Cell Carcinoma: Recommendation

1. The term “*superficially invasive squamous cell carcinoma (SISCCA)*” is recommended for minimally invasive squamous cell carcinoma (SCC) of the LAT that has been completely excised and is potentially amenable to conservative surgical therapy.
 - Note: Lymph-vascular invasion (LVI) and pattern of invasion are not part of the definition of SISCCA, with the exception of penile carcinoma.

WG3 Recommendation 1 – Explanatory note

- **Resection margin status is best determined from a single marked/painted surgical biopsy**
 - In the cervix, for example, this will usually mean a LEEP or cone specimen.
- **In the setting of multiple specimens, the final diagnosis must be based on the consideration of the findings in all the specimens.**

WG3 Superficially Invasive Squamous Cell Carcinoma: Recommendation

2. For cases of invasive squamous carcinoma *with positive biopsy/resection margins*, the pathology report should state whether:

The examined invasive tumor exceeds the dimensions for a SISCCA (defined below)

OR

The examined invasive tumor component is less than or equal to the dimensions for a SISCCA and conclude that the tumor is “*at least a superficially invasive squamous carcinoma.*”

WG3 Recommendation 2 – Explanatory note

positive biopsy / resection margins

=

Invasive carcinoma at surgical resection margin

The presence of HSIL at the surgical margins does not negate the diagnosis of SISCCA; however, its presence should be reported.

WG3 Superficially Invasive Squamous Cell Carcinoma: Recommendation

- 3. In cases of SISCCA, the following parameters should be included in the pathology report:**

The presence or absence of LVI.

The presence, number, and size of independent multifocal carcinomas (after excluding the possibility of a single carcinoma).

(Presence/absence of SIL at margins)

WG3 Recommendation 3 – Explanatory note

- **LVI is most reliably defined when the following features are identified in an H&E histologic section:**
 - **A tumor island is present within a space,**
 - **The space has an apparent lining,**
 - **The tumor is adherent to the lining,**
 - **The space is not due to retraction artifact,**
 - **The finding is beyond the invasive front.**

WG3 SISCCA: Cervix

4. SISCCA of the cervix is defined as an invasive squamous carcinoma that:

Is not a grossly visible lesion,

AND

Has an invasive depth of ≤ 3 mm from the basement membrane of the point of origin,

AND

Has a horizontal spread of ≤ 7 mm in maximal extent,

AND

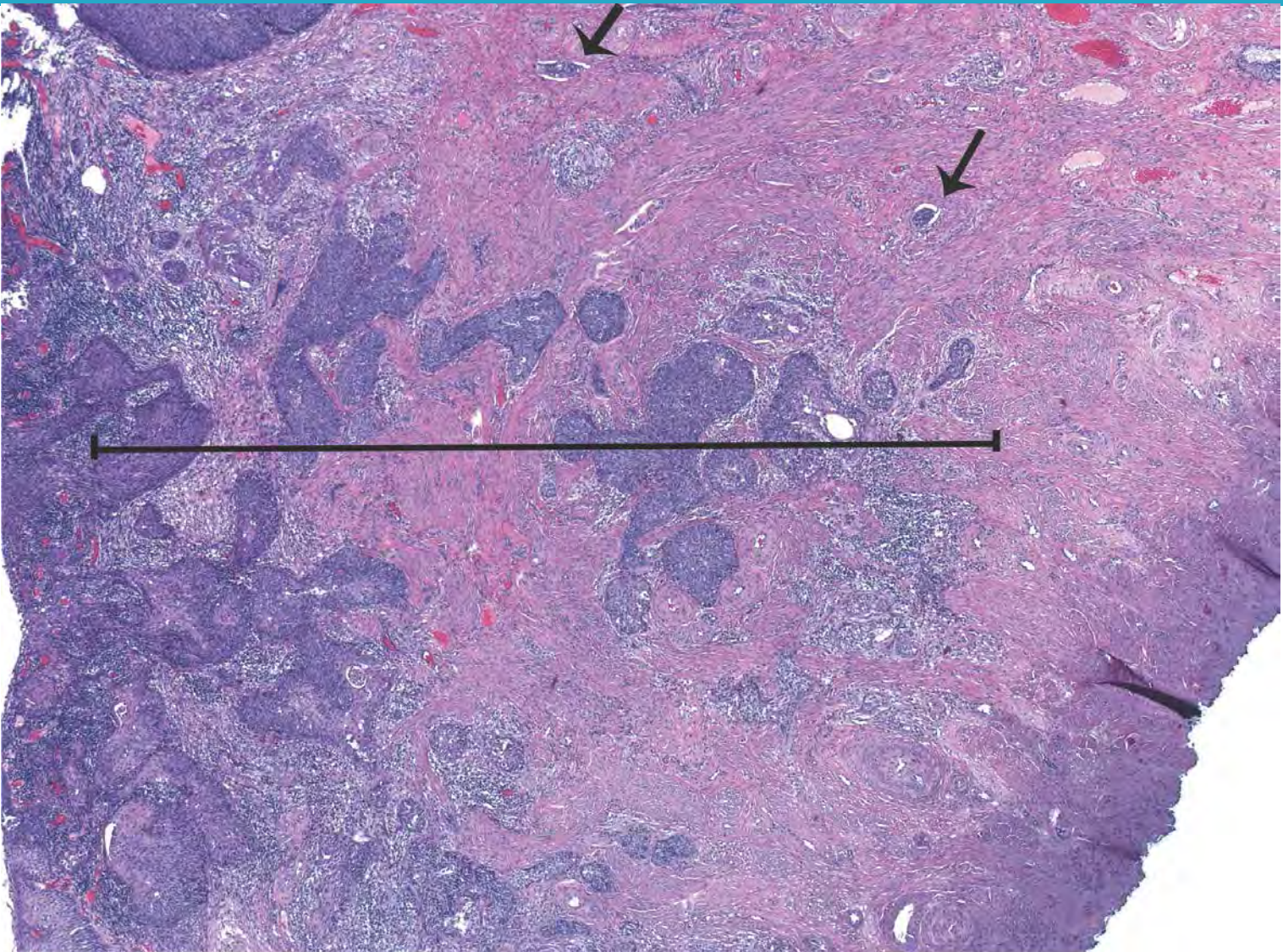
Has been completely excised.

Rationale for cervix recommendation:

- **Essentially 100% of SCCA of the cervix are attributable to HPV.**
- **There are abundant data on early SCCA of the cervix indicating that it can safely be treated conservatively.**
- **However, a variety of terms, including “microinvasive carcinoma”, have been used to label this group and criteria for defining these various groups have changed over the years.**
- **Currently early stage cancers are defined by pathologic examination using both SGO and/or FIGO staging criteria. Larger cervical cancers are staged clinically.**
- **Early stage cervical carcinomas now compose a large proportion of invasive carcinomas of the cervix overall.**

Rationale for cervix recommendation:

- **FIGO defines Stage IA1 as an invasive carcinoma diagnosed only by microscopy with stromal invasion 3.0 mm or less in depth and 7.0 mm or less of horizontal spread,**
- **SGO microinvasion (1974) any lesion with stromal invasion, in one or more sites to a depth of 3 mm or less below the base of the epithelium, without lymphatic or blood vessel involvement,**
- **The microscopic measurements of these invasive lesions are defined, but variable in practice, and portend a cure via local excision in approximately 99% of cases,**
- **These cases may be amenable to conservative surgical management (ie, cone biopsy with negative margins).**



WG3 Figure 1: Cervical SICCCA with less than 3 mm (line); LVI is present (arrows). It was completely excised.

Reprinted with permission. Bean SM, Kurtycz DF, Colgan TJ. J Low Genit Tract Dis. 2011 Apr;15(2):146-57. Copyright 2011, ASCCP.

WG3 SISCCA: Vagina

- 5. No recommendation is offered for early invasive squamous carcinoma of the vagina.**
- Owing to the rarity of primary SCC of the vagina, there are insufficient data to define early invasive squamous carcinoma in the vagina.**

Rationale for Vagina Recommendation:

- **Vaginal SCCA is rare and generally is not amenable to local resection,**
- **Approximately 40-60% of SCCA of the vagina are attributable to HPV,**
- **FIGO staging for vaginal SCCA is clinical, and uses all available data including biopsy results, regional lymph node FNA to determine definitive treatment,**
- **An SCCA confined to the vagina is an AJCC T1 tumor (FIGO Stage 1). T1 tumors are not further subdivided.**

WG3 SISCCA: Anal Canal

6. The suggested definition of SISCCA of the anal canal is an invasive squamous carcinoma that:

Has an invasive depth of ≤ 3 mm from the basement membrane of the point of origin,

AND

Has a horizontal spread of ≤ 7 mm in maximal extent,

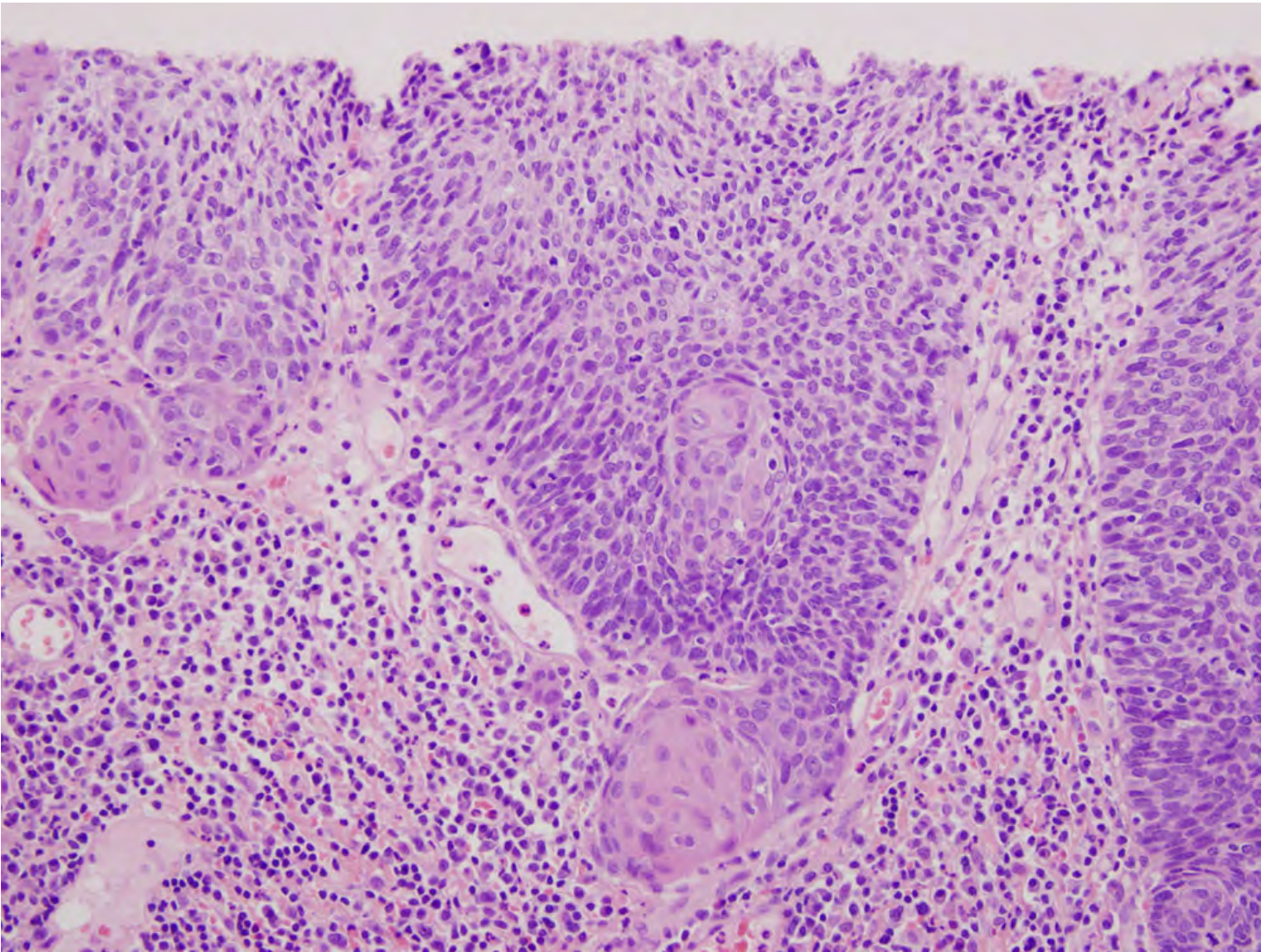
AND

Has been completely excised.

Rationale for anal canal recommendation:

- **Approximately 90-93% of anal canal SCCA are attributable to HPV.**
- **The current AJCC definition of a T1 anal tumor is 2 cm or less in greatest dimension. T1 tumors are not subdivided further.**
- **There is a paucity of information regarding anal canal SCCA, and the tumor size amenable to conservative surgical therapy is largely unknown.**
- **Combined modality therapy (radiation and chemotherapy) is the current standard of care for anal cancer.**
- **As more early invasive anal cancers are diagnosed (due to increased awareness and screening in some centers), identifying minimally invasive cancers that are potentially amenable to conservative surgical therapy is imperative.**





WG3 Figure 2: SISCCA of anal canal with a nest of malignant squamous cells invading into the stroma. Note overlying HSIL. (H&E, Medium power)

WG3 Recommendation 6 – Explanatory note

- **The conservative management of an anal SISCCA patient should include an evaluation by an expert experienced with high-resolution anoscopy and anal canal cancer.**

WG3 SISCCA: Vulva

7. Vulvar SISCOA is defined as an AJCC T1a (FIGO IA) vulvar cancer.

No change in the current definition of T1a vulvar cancer is recommended.

- **Current AJCC definition of T1a vulvar carcinoma:**

Tumor ≤ 2 cm in size, confined to the vulva or perineum

AND

Stromal invasion of ≤ 1 mm.

Rationale-Vulva

Vulva: Approximately 40-50% of squamous cell carcinomas of the vulva are attributable to HPV*

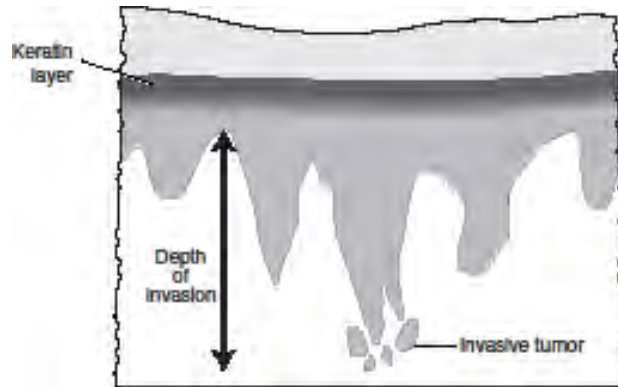
***Parkin & Bray Vaccine 2006**

- **Staging for SCCA of the vulva is the same regardless of the etiology.**
- **The AJCC definition of a T1a (FIGO 1A) vulvar squamous carcinoma is a lesion 2 cm or less in size, confined to the vulva or perineum and with stromal invasion of 1 mm or less.**

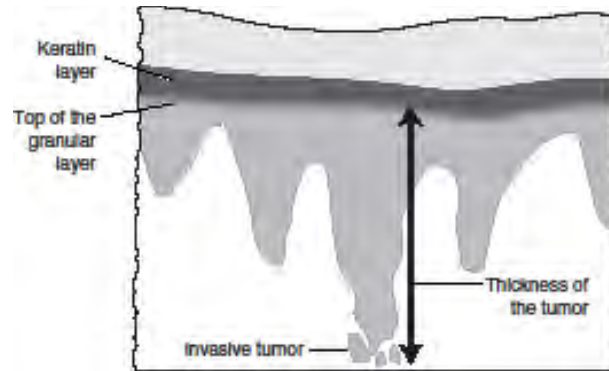
Rationale-Vulva

- **The depth of invasion is defined as the measurement of the tumor from the epithelial-stromal junction of the adjacent most superficial dermal papilla to the deepest point of invasion.**

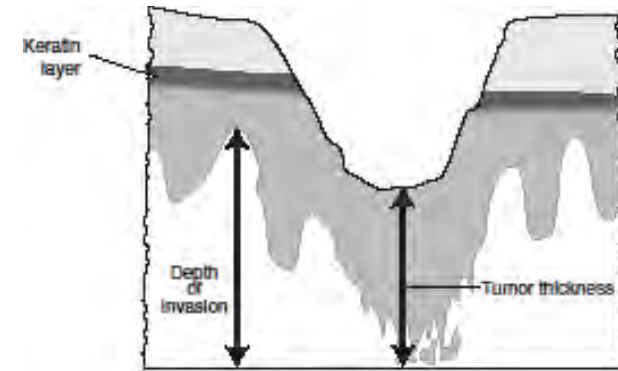
A



B



C



WG3 Figure 3: Cutaneous anogenital SISCCA; measurement of the depth of invasion.

A. The depth of invasion is measured from the epithelial-dermal junction of the adjacent-most superficial dermal papillae to the deepest point of invasion. This measurement is applicable whether or not the surface epithelium is ulcerated or keratinized. This is the AJCC recommended method of measuring vulvar squamous cell carcinomas in determining if a tumor is Stage T1a or T1b.

B: Measurement for the thickness of the tumor when the epithelial surface is intact. If the tumor is keratinized, the thickness of the tumor is measured from the granular cell layer to the deepest point of invasion. For squamous cell carcinomas, the convention is to measure from the bottom of the granular cell layer. If the epithelium is not keratinized the thickness of the tumor is measured from the surface of the tumor to the deepest point of invasion.

C: Measurement for tumor thickness when the tumor is ulcerated. The tumor thickness is measured from the surface of the ulcerated tumor to the deepest point of invasion. For squamous cell carcinoma the depth of invasion is a more accurate measurement of the true depth of the tumor, as measured from the epithelial dermal junction of the adjacent dermal papillae to the deepest point of invasion

WG3 SISCCA: Penis

8. Penile SISCCA is defined as an AJCC T1a.

No change in the current definition of T1a penile cancer is recommended.

- Current AJCC definition of T1a penile carcinoma: Tumor that invades only the subepithelial connective tissue,

AND

No LVI

AND

Is not poorly differentiated (ie, grade 3-4).

Rationale-Penis

- **Cancers of the penis are rare in the United States.**
- **Approximately 40% of squamous cell carcinomas of the penis are attributable to HPV***
- **The AJCC definition of a T1a penile squamous carcinoma is a tumor that invades subepithelial connective tissue without lymphovascular invasion and is not poorly differentiated (i.e., grade 3-4).**

***Parkin & Bray Vaccine 2006**

Rationale-Penis

- **If lymph-vascular invasion is identified or the tumor is poorly differentiated the lesion is classified as T1b**
- **Both parameters are independent predictors of inguinal lymph node involvement in patients with squamous cell carcinoma of the penis and should prompt more aggressive care.**

WG3 SISCCA: Scrotum

- 9. No recommendation is offered for early invasive squamous carcinoma of the scrotum.**
- Owing to the rarity of primary SCC of the scrotum, there is insufficient evidence to make a recommendation regarding the current AJCC staging of early scrotal cancers.**

Rationale-Scrotum

- **Squamous cell carcinoma of the scrotum is now very rare**
- **Although some are HPV-related, historically its development was linked to occupational exposure in chimney sweeps**

Rationale-Scrotum

- **The current AJCC staging system for scrotal cancer is as per cutaneous squamous cell carcinoma.**
- **There are no subdivisions of T1 skin cancers, defined as 2 cm or less with fewer than two high-risk features (> 2 mm thickness, Clark level \geq IV, perineural invasion, poorly differentiated or undifferentiated)**

WG3 SISCCA: Perianus

10. The suggested definition for SISCCA of the perianus is an invasive squamous carcinoma that:

Has an invasive depth of ≤ 3 mm from the basement membrane of the point of origin,

AND

Has a horizontal spread of ≤ 7 mm in maximal extent,

AND

Has been completely excised.



Rationale-Perianus

- **Specific statistics regarding the proportion of squamous cell carcinoma of the perianus that are attributable to HPV are unknown**
- **Presumably, it is similar to other contiguous cutaneous genital sites, such as the vulva in women.**

Rationale-Staging - Perianus

- **In the current AJCC staging, perianal cancers are staged as cutaneous squamous cell carcinoma.**
- **T1 skin cancers are defined as:**
 - **2 cm or less with fewer than two high-risk features**
 - **There are no subdivisions of this stage**

Rationale-Definition- Perianus

- **The perianus is currently defined as the region extending 5 cm from the anal verge.**
- **However, in women, the perineum should be considered part of the vulva for staging and management purposes.**

Clinical Implications and Implementation

LAST: Clinician's Concerns

Concerns from the public comment period and working group are predominantly focused on two aspects.

- **The clinical guidelines for treating cervical lesions are based on a 3-tiered (i.e. CIN) system.**
- **Concern was expressed that a 2-tiered system for cervical disease where most CIN2 lesions would fall into a high grade category would lead to potential over-treatment of patients, especially young women.**
 - **Potential perinatal morbidity associated with treatment**

LAST: Clinicians' Concerns

- **Abuse of p16**
 - While LAST proscribes use of p16 with CIN1, there is a fear among some clinicians that it will be used.
 - Diagnosis of CIN1-2
 - There is some data suggesting that CIN1/p16-positive lesions are more likely to progress than CIN1/p16-negative.
 - Will CIN1/p16-positive now be called “HSIL”?
 - Will clinicians manage HSIL (CIN1/p16-positive) with unnecessary treatment?

LAST: Benefits of Eliminating CIN2

- **A 2-tiered system using p16 for adjudication of equivocal high grade lesions results is a much more reproducible diagnosis in pathology practice which will result in better clinical care**
- **The poorly reproducible diagnosis of CIN2 may have resulted in overtreatment of lesions with low likelihood of becoming cancer.**

LAST: Benefits of Eliminating CIN2

- **Most clinicians are not aware that CIN2 is an equivocal diagnosis**
- **Implementing LAST terminology will probably not affect most clinicians' practice.**
- **Accustomed to cytology reporting of LSIL / HSIL**
 - **Parentetical reporting of CIN terminology after “SIL” designation has been the norm for many labs since first Bethesda Conference in 1988.**

Management Concerns for Clinicians

Current ASCCP management recommendations:

- **CIN1**
 - In most cases, follow conservatively over 12 months with repeat cytology X 2 or HPV
- **CIN2+**
 - In most cases, treat with excision or ablation
 - **(except in adolescents and young women)**

Management Concerns for Clinicians

- **How will the ASCCP management guidelines work with new endpoints?**
 - LSIL = CIN1 and CIN2 (p16-negative)
 - HSIL = CIN3 and CIN2 (p16-positive)
- **ASCCP guidelines based on data from multiple studies -- largely influenced by ALTS**

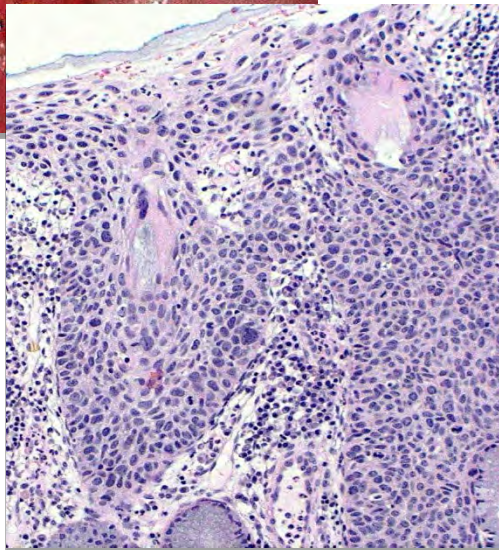
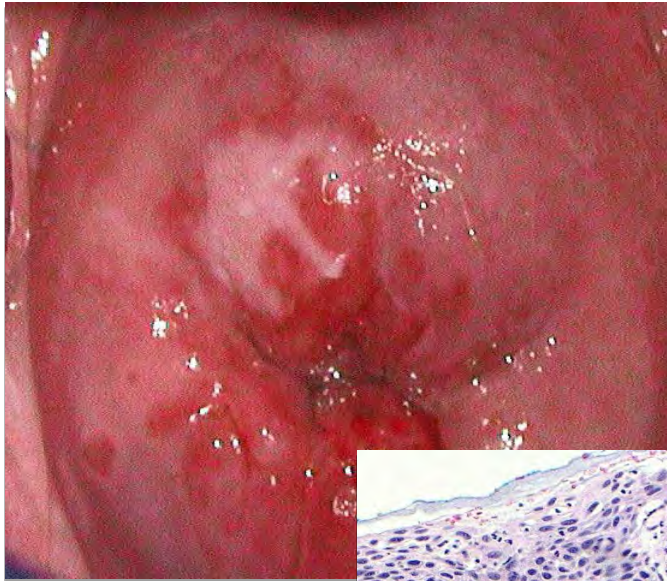
Management Concerns for Clinicians

- **Unknown clinical course of LSIL(CIN2/p16-neg)**
 - **Can this be managed expectantly as confidently as morphologic CIN1?**
 - **Probably, but no data**
 - **Conservative management of “LSIL”**
 - **Low likelihood of cancer in 6-12 months**
 - **Persistent abnormal cytology or positive HPV will lead to repeat colposcopy.**

Management Concerns for Clinicians

- **There is one scenario in which recommended clinical management is different for CIN2 and CIN3.**
 - **Adolescents and “young women”.**
- **How do we deal with this if CIN2 and CIN3 are combined into “HSIL”?**

A 21 y.o. has HSIL on cytology. Colposcopy was satisfactory and a biopsy was performed at 11:00. The biopsy revealed CIN2. How should she be managed?



A. LEEP

**B. Follow with Pap test
in 6 and 12 months**

**C. Follow with Pap test
plus colposcopy in 6
and 12 months**

**D. HPV DNA test in 12
months**

Natural History of Untreated CIN2 in Adolescents and Young Women

| Author | N | Age | Mean f/u | Regression to neg | Progression to CIN3 |
|----------|----|-------|----------|-------------------|---------------------|
| Moore | 23 | ≤ 21 | 18 mo | 65% | 13% |
| Fuchs | 36 | ≤ 21 | 378 days | 39% | 8% |
| | 32 | | 3 Yrs | 75% | |
| Moscicki | 95 | 13-24 | 1 yr | 38% | 2% |
| | | | 2 yr | 63% | 12% |
| | | | 3 yr | 68% | 15% |

No cases progressed to cancer in any study.

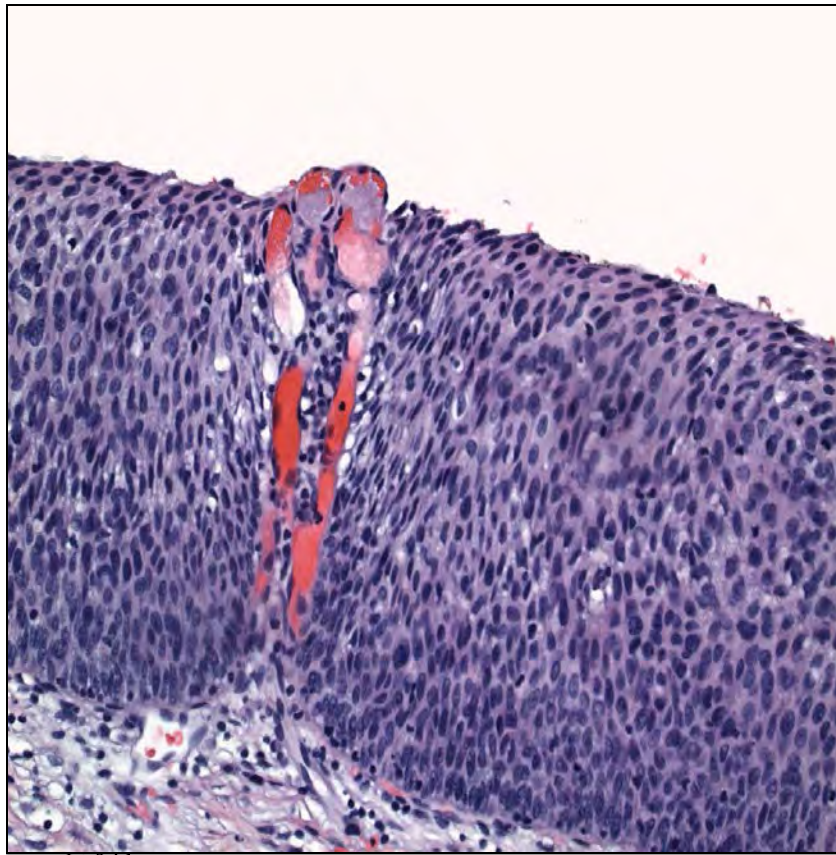


Moore K. et.al. Am J Obstet Gynecol 2007;197:141.e1-6

Fuchs J et.al. Ped Adoles Gynecol 2007;20:269-74

Moscicki AB et.al. Obstet Gynecol 2010;116:1373-80

What if her biopsy showed CIN3?
Would your management differ?



CAP

A. LEEP

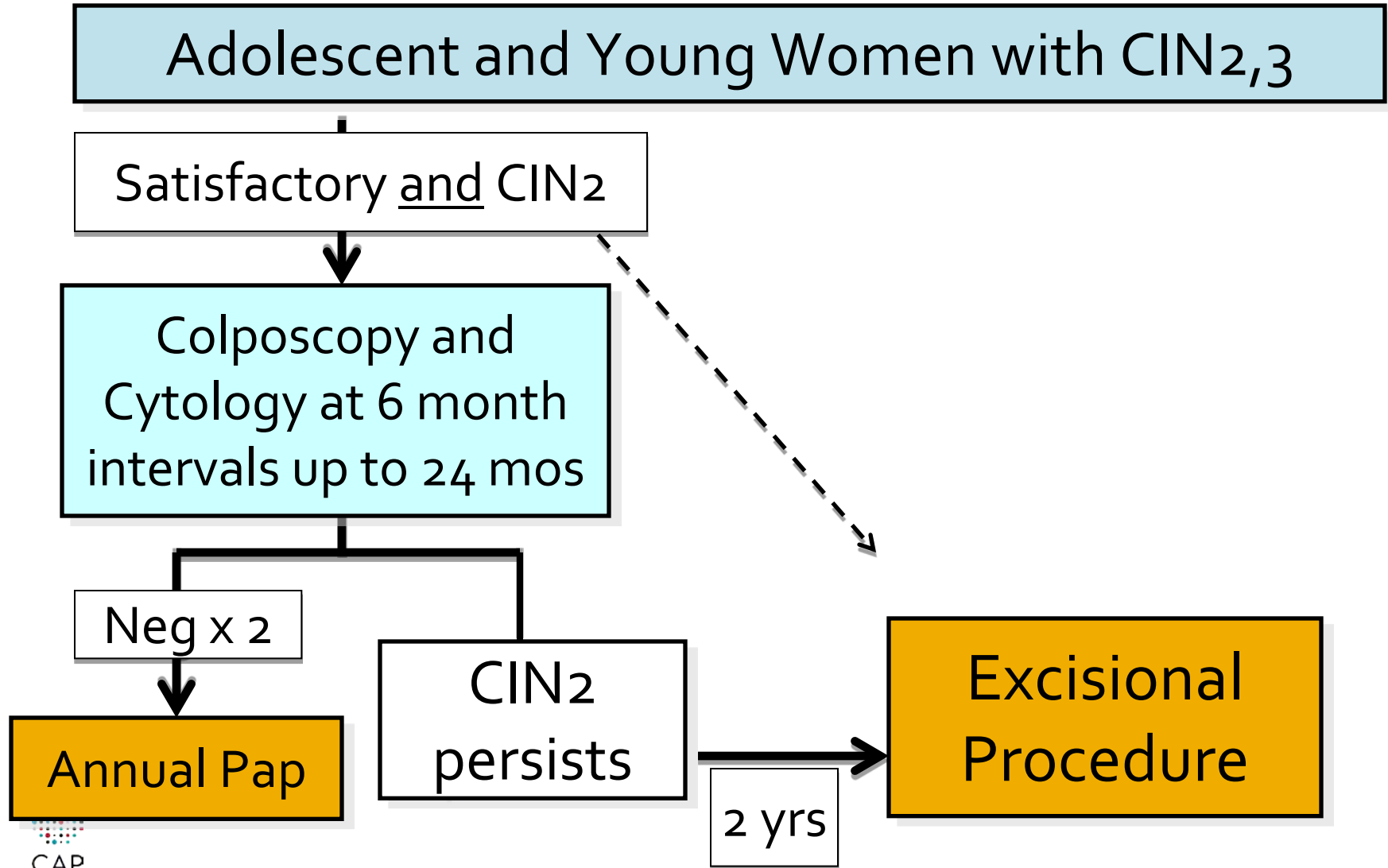
B. Follow with Pap test
in 6 and 12 months

C. Follow with Pap test
plus colposcopy in 6
and 12 months

D. HPV DNA test in 12
months

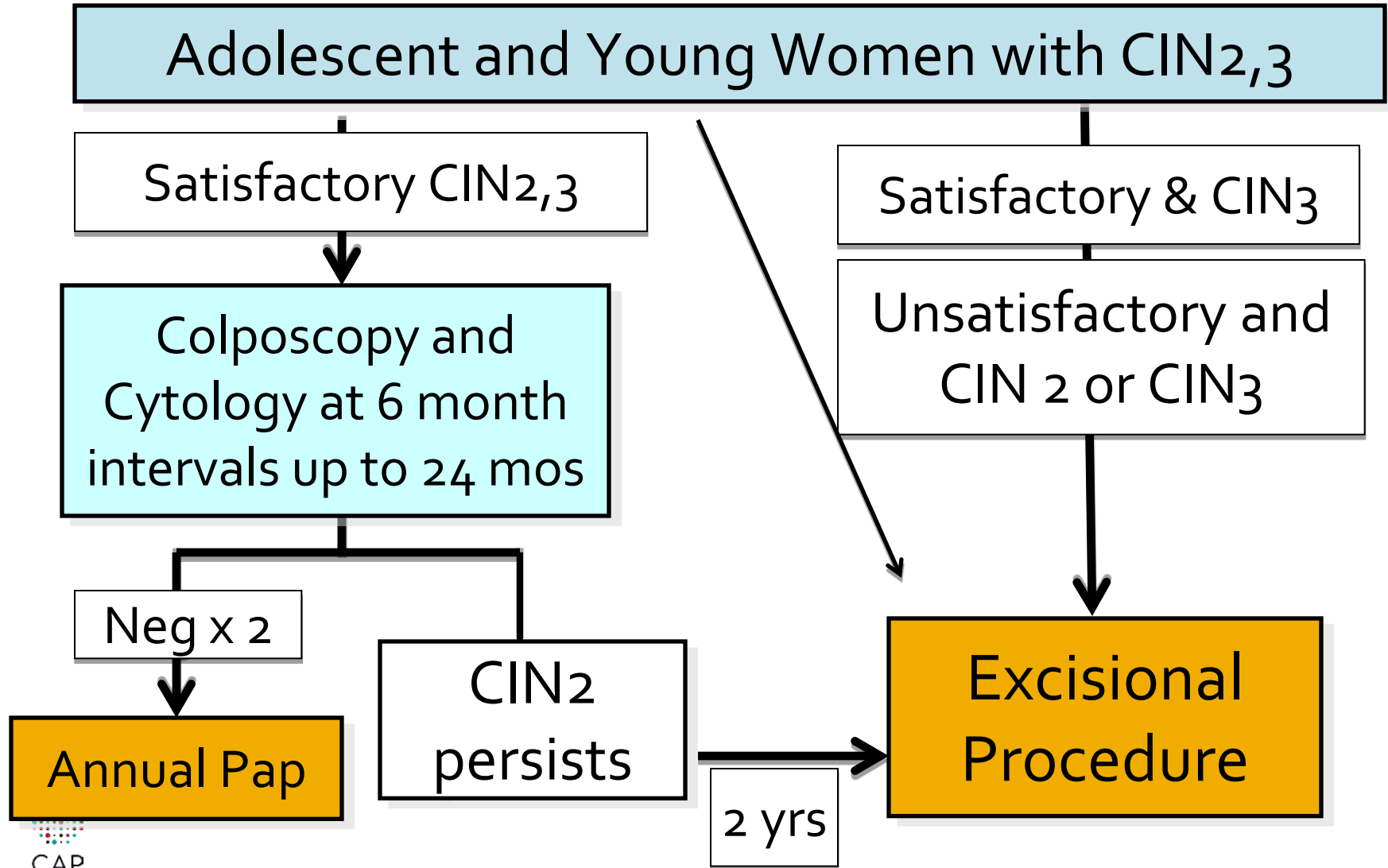
2006 ASCCP Guidelines

CIN2,3 in Teens and Young Women



2006 ASCCP Guidelines

CIN2,3 in Teens and Young Women



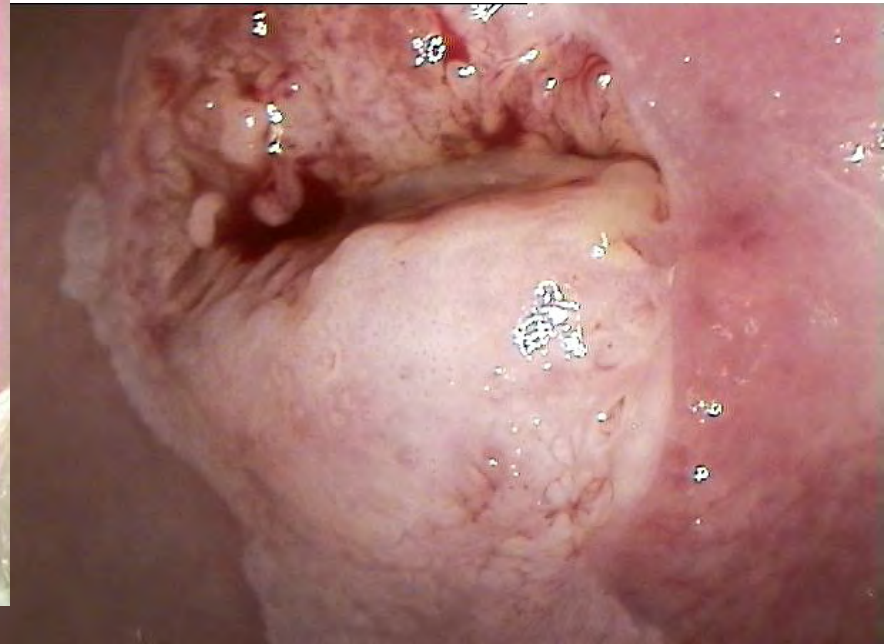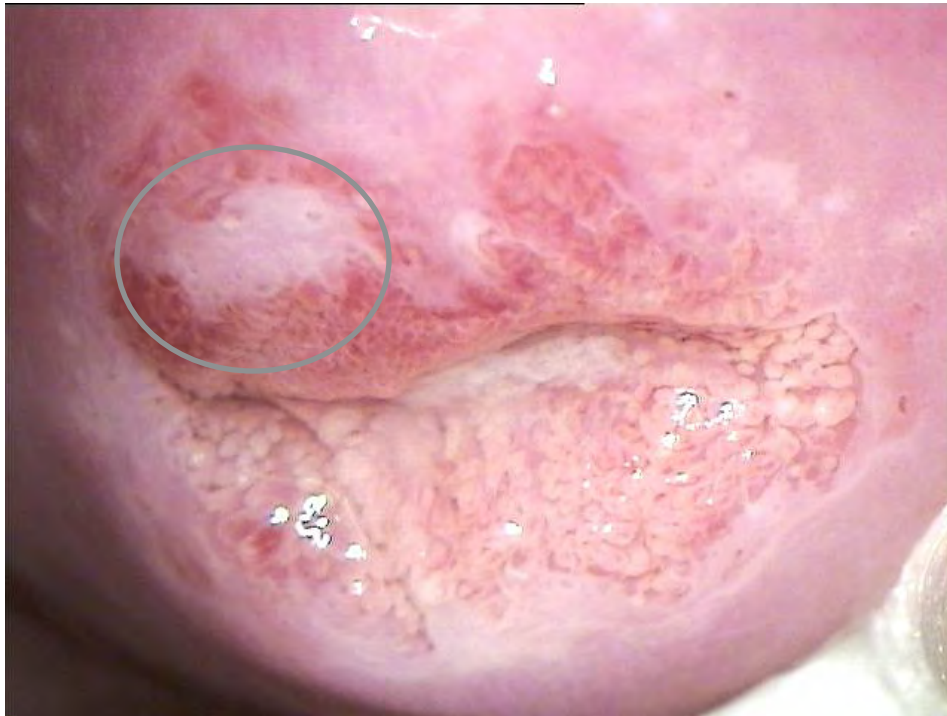Proposed Management Regimen

- There is no *direct* data on conservative management of young women with “HSIL” with HSIL defined as CIN2 / p16-positive or CIN3.
- Progression from HPV infection to cancer usually takes decades.
- Most infections in young women are new infections
 - 90% no longer detectable in 2-3 years
 - Those that develop HSIL have a long latent period before development of cancer in the few that will progress.
- Rate of invasive cancer under age 25 is 1.5/100,000 (SEER)

Proposed Management Regimen

- **LSIL – manage as CIN1**
 - **LSIL (CIN2 / p16-negative) should be safely followed with cytology q 6 months X 2 or HPV in 12 months**
- **HSIL in most women – manage as CIN2 or 3**
- **HSIL in young women**
 - **If HSIL (CIN3) – treatment with excision or ablation**
 - **If HSIL (CIN2 or NOS) manage with q 6 month cytology and colposcopy**
 - **Treat if persists for 24 months**
 - **Treat if colposcopy unsatisfactory**
 - **Treat if lesion enlarges or appears more severe on colposcopy**

We already have the option to manage young women with CIN2,3 with close follow-up if satisfactory colposcopy. Most clinicians would be more likely to follow CIN2,3 in a young woman when the lesion is small, less apparent and not extending into the canal as seen here.



Whereas no one would follow this CIN2,3

Working Group 5: Implications and Implementation of Standardizing Lower Anogenital Terminology

- **To develop action plans to implement the terminology for pathologists and clinicians**
 - Presentations at medical society meetings
 - Publication of recommendations /commentaries in journals and development of web based resources
- **To address the potential implications to the following areas:**
 - *Data collection/recording/billing-* tumor registries/cancer protocols, SNOMED /CPT/ICD codes
 - *Education/Testing bodies-* training programs, examinations
 - *Regulatory agencies-* CMS, CDC, CAP/JC checklists
- **To assess uptake and impact**
 - Baseline and follow up surveys of pathologists/clinicians

Summary: The LAST Project



CAP/ASCCP Lower Anogenital Squamous Terminology for HPV-Associated Lesions Summary of Consensus Recommendations

Squamous Intraepithelial Lesions

Recommendation:

1. A unified histopathological nomenclature with a single set of diagnostic terms is recommended for all HPV-associated preinvasive squamous lesions of the lower anogenital tract (LAT).
2. A 2-tiered nomenclature is recommended for noninvasive HPV-associated squamous proliferations of the LAT, which may be further qualified with the appropriate -IN terminology, without specifying the location. For a specific location, the -IN refers to the generic intraepithelial neoplasia terminology. For a specific location, the appropriate complete term should be used. Thus for an -IN 3 lesion: cervix = CIN 3, vagina = VIN 3, vulva = VIN 3, and perianus = PAIN 3, and penis = PeIN 3.
3. The recommended terminology for HPV-associated squamous lesions of the LAT is low-grade squamous intraepithelial lesion (LSIL) and high-grade squamous intraepithelial lesion (HSIL), which may be further classified by the applicable -IN subcategorization.

Biomarkers in HPV-Associated Lower Anogenital Squamous Lesions

Recommendation:

1. p16 IHC is recommended when the H&E morphologic differential diagnosis is between precancer (-IN 2 or -IN 3) and cancer (e.g., processes known to be not related to neoplastic risk such as immature squamous metaplasia). Strong and diffuse block positive p16 results support a categorization of precancerous disease.
 2. If the pathologist is entertaining an H&E morphologic interpretation of -IN 2 (under the old terminology, low-grade lesion) or -IN 3 (under the old terminology, high-grade lesion) and the p16 IHC is positive, the p16 IHC result should be interpreted as follows:
 - IN 2: Strong and diffuse block positive p16 results support a categorization of precancerous disease.
 - IN 3: Strong and diffuse block positive p16 results support a categorization of precancerous disease.
 3. p16 is recommended for use as an adjudication tool for cases in which there is a professional disagreement on the interpretation of low-grade disease or a non-HPV-associated pathology.
 4. p16 is recommended for use as an adjunct to morphologic assessment, for biopsy specificity, and for interpretation of low-grade disease or a non-HPV-associated pathology.
- SPECIAL CIRCUMSTANCE**
4a. p16 IHC is recommended as an adjunct to morphologic assessment, for biopsy specificity, and for interpretation of low-grade disease, which is defined as a prior cytologic interpretation (NOS). Any identified p16-positive area must meet H&E morphologic criteria for a high-

CAP/ASCCP Lower Anogenital Squamous Terminology for HPV-Associated Lesions Summary of Consensus Recommendations

SISCCA Recommendation: Superficially Invasive Squamous Cell Carcinomas (SISCCA)

1. The term superficially invasive squamous cell carcinoma (SISCCA) is recommended for minimally invasive squamous cell carcinoma of the LAT that has been completely excised and is potentially amenable to conservative surgical therapy.

Note: Lymphovascular invasion (LVI) and pattern of invasion are not part of the definition of SISCCA, with the exception of penile carcinoma.

2. For cases of invasive squamous carcinoma with positive biopsy/resection margins, the pathology report should state whether the examined invasive tumor exceeds the dimensions for a SISCCA (defined below).

Note: The examined invasive tumor component is less than or equal to the dimensions for a SISCCA and conclude that the tumor is "At least a superficially invasive squamous carcinoma."

3. In cases of SISCCA, the following parameters should be included in the pathology report: The presence or absence of LVI, The presence, number, and size of independent multifocal carcinomas (after excluding the possibility of a single carcinoma).

SISCCA Site-Specific Recommendation

| Site | Mucosal | Cutaneous | Comments |
|---------------|--|-----------|---|
| 4. CERVIX | SISCCA of the cervix is defined as an invasive squamous carcinoma that is not a grossly visible lesion, AND has an invasive depth of ≤ 3 mm from the basement membrane of the point of origin, AND has a horizontal spread of ≤ 7 mm in maximal extent, AND has been completely excised. | | |
| 5. VAGINA | No recommendation is offered for early invasive squamous carcinoma of the vagina. | | Owing to the rarity of primary SCC of the vagina, there are insufficient data to define early invasive squamous carcinoma in the vagina. |
| 6. ANAL CANAL | The suggested definition for SISCCA of the anal canal is an invasive squamous carcinoma that has an invasive depth of ≤ 3 mm from the basement membrane of the point of origin, AND has a horizontal spread of ≤ 7 mm in maximal extent, AND has been completely excised. | | |
| 7. VULVA | Vulvar SISCCA is defined as an AJCC T1a (FIGO IA) vulvar cancer. | | |
| 8. PENIS | Penile SISCCA is defined as an AJCC T1a. | | Current AJCC definition of T1a vulvar carcinoma: tumor ≤ 2 cm in size, confined to the adjacent stromal invasion of ≤ 1 mm. Note: The depth of invasion is the deepest point of invasion from the epithelial-stromal junction of the adjacent most superficial dermal papilla to the deepest point of invasion. |
| 9. SCROTUM | No change in the current definition of T1a penile cancer is recommended. | | Current AJCC definition of T1a penile carcinoma: tumor that invades only the subepithelial connective tissue, AND No LVI AND is not poorly differentiated (i.e., grade 3-4). |
| 10. PERIANUS | No recommendation is offered for early invasive squamous carcinoma of the scrotum. | | Owing to the rarity of primary SCC of the scrotum, there is insufficient literature to make a recommendation regarding the current AJCC staging of early scrotal cancers. |

Reference: Barragh RM, Colgan JT, Cox JL, et al. The lower anogenital squamous terminology standardization project for HPV-associated lesions: Background and consensus recommendations from the College of American Pathologists and the American Society for Coloproctology and Cervical Pathology. *Am J Pathol*. 2018;184:1-11. Effective date: June 26, 2018.



LAST Project Resources

- Links to articles
- Summary of recommendations
- FAQs
- Biomarker Algorithms
- LAST Project PowerPoint presentation
- www.cap.org
- www.asccp.org



COLLEGE of AMERICAN
PATHOLOGISTS



LAST Project Teaching PowerPoint Copyright

Effective June 28, 2012

Copyright of the line-by-line text, the teaching PowerPoint and the biomarker algorithms of the LAST Consensus Recommendations belongs to CAP and ASCCP.

Permission to reprint guidelines text for any purpose (e.g., educational or commercial) requires written permission by either [Archives](#) or [Lippincott, Williams & Wilkins](#)

Permission to reprint the algorithm requires sole, exclusive written permission of either CAP or the ASCCP. [Contact the ASCCP](#) for further information.

The algorithms must be reproduced without modification, edits or changes to style or format.



CAP



COLLEGE of AMERICAN
PATHOLOGISTS



The LAST Project

Thank you for implementing!



CAP